



Gabapentin Treatment in a Child With Delayed-Onset Hemichorea/ Hemiballismus

Sanjeev V. Kothare, MD*,
Phyllis Pollack, MD[†],
Alan G. Kulberg, MD[‡], and
Paula D. Ravin, MD[§]

A 13-year, 6-month-old female was evaluated for subacute onset of left-sided hemichorea/hemiballismus, with an old, right parietal, cortical, and subcortical stroke as the presumed cause. Treatment with gabapentin was initiated, with good results at 6-month follow-up. Discussion of the differential diagnosis and evaluation of delayed-onset movement disorders in children and the mechanism of action of gabapentin is included. © 2000 by Elsevier Science Inc. All rights reserved.

Kothare SV, Pollack P, Kulberg AG, Ravin PD. Gabapentin treatment in a child with delayed-onset hemichorea/hemiballismus. *Pediatr Neurol* 2000;22:68-71.

Introduction

Hemichorea/hemiballismus is an uncommon presentation in children compared with adults and is rarely reported as a late complication of static lesions in the brain. A 13-year, 6-month-old female is reported with delayed-onset hemichorea/hemiballismus and a discrete contralateral parietal and subcortical stroke attributable to a cardiac embolism 8 years before resulting from infective endocarditis involving the mitral valve. The mechanisms of production of hemichorea/hemiballismus and the favor-

able response to gabapentin are discussed. Differences between this case and others caused by antiphospholipid antibody syndrome [1] or Sydenham's chorea [2] are also discussed with regard to their treatment and prognosis.

Case Report

A 13-year, 6-month-old, right-handed female presented to the emergency room because of worsening of left upper and lower extremity jerky movements, dysarthria, and drooling from the left angle of the mouth during the previous 2 months. Her past medical history was significant for a mitral valve prolapse diagnosed at 4 years of age. At age 5, she developed episodic left upper extremity tingling and numbness and weakness of the left hand. *Streptococcus viridans* infective endocarditis was diagnosed at 5 years, 6 months and was adequately treated with intravenous antibiotics. During the next 8 years, she continued to have episodic dysesthesias of the left upper extremity and intermittently dropped objects from her left hand. During the past 3-4 years, she also began to develop exertional dyspnea because of worsening mitral regurgitation. Two months before the current presentation with involuntary movements, she underwent an uncomplicated mitral valvuloplasty. Her past medical history was also significant for a few years of migraines with visual auras at a frequency of 2-3 monthly before the onset of her current symptoms. They were readily relieved using simple analgesics. She had begun menstruating 8 months before the onset of the movement disorder. Her birth history and early developmental milestones were unremarkable. She had been an honor student in seventh grade but in the eighth grade had not been doing well because of poor concentration. Her family history was significant for migraines in the mother. Her cardiac medications had been withdrawn after her surgery.

On examination, she weighed 67 kg and was afebrile. She had no skin rashes or joint inflammation. The systemic examination was significant for a systolic murmur at the apex of the precordium. The neurologic examination revealed a labile affect, dysarthric speech, normal cognitive skills, hippus in both pupils, and normal vision and extraocular movements. Her motor examination revealed choreiform movements of her tongue, choreiform movements of her left upper extremity with associated athetosis of her left hand, occasional hemiballistic movements of her left upper and lower extremities, normal sensation and strength, and no cerebellar signs. Her gait was jerky in character, her tendon reflexes were normal, and she had normal plantar responses on the right and equivocal responses on the left.

The results of the laboratory studies were as follows: leukocyte count was 7,900/mm³, erythrocyte sedimentation rate was 3 mm/hour, hemoglobin was 12.3 gm/dL, platelet count was 193,000/mm³, antistreptolysin-O titer was less than 1:128 (normal less than 1:256), serum copper was 969 µg/L (normal 700-1,750 µg/L), serum ceruloplasmin was 35.9 mg/dL (normal 20-52 mg/dL), and 24-hour urine copper was 11 µg. The serum electrolytes and protein electrophoresis, prothrombin and partial thromboplastin times, and thyroid functions were normal, and the throat culture, antinuclear antibodies, rheumatoid factor, and antiphospholipid antibody profile were negative. Magnetic resonance imaging of the brain revealed a small, old ischemic infarct involving the right posterior parietal cortex and extending into the underlying subcortical white

From the *Division of Pediatric Neurology and [†]Division of Pediatric Cardiology; Department of Pediatrics; and Departments of [‡]Pediatrics and [§]Neurology; University of Massachusetts Memorial Health Care, Worcester, Massachusetts.

Communications should be addressed to:
Dr. Ravin; Department of Neurology; University of Massachusetts
Memorial Health Care; 55 Lake Avenue North;
Worcester, MA 01655-0318.

Received May 3, 1999; accepted August 10, 1999.

matter up to the lateral ventricle. Technetium-99 hexamethylpropylene amineoxime single-photon emission computed tomography of the brain was normal. Electroencephalography revealed mild slowing of the background activity in the right posterior quadrant without any epileptiform activity on a sleep-deprived study.

Gabapentin 300 mg three times daily was initiated and gradually increased during the next 4 weeks to 1,600 mg three times daily (4,800 mg daily; 75 mg/kg/day). There was near complete disappearance of the choreiform movements in her extremities, minimal persistent disarticulation, and improved attention and performance in school. No dizziness, nausea, or sedation at the time of the peak dose was observed. She did complain of an occasional increase in the choreiform movements at the end of the dose intervals, with resolution of these symptoms within 30 minutes of taking the gabapentin.

Two months after a 6-month course of gabapentin was discontinued, she observed a slight increase in the involuntary movements of her left face and tongue, with dysarthric speech, which worsened after lack of sleep and at the end of the day. Repeated erythrocyte sedimentation rate, antinuclear antibodies, C3 complement levels, antiphospholipid antibody titers, and antistreptolysin-O titers were normal.

Discussion

This patient qualifies under the rubric of the delayed-onset movement disorder after childhood central nervous system injury, namely a right parietal, cortical, and subcortical embolic infarct associated with *S. viridans* infective endocarditis. She described episodes of paresthesia on her left side and clumsiness of her left hand since the time of the infective endocarditis, which was indicative of her original central nervous system insult, but she did not manifest hemichorea/hemiballismus until at least 8 years later. A number of triggers for the delayed onset can be postulated. It is possible that hypoperfusion of an old penumbra during mitral valvuloplasty contributed to the emergence of the new signs. In addition, estrogenic effects on the D2 receptors with the advent of puberty or the stress of heart surgery under hypothermia could have been precipitating factors. A review by Jankovic and Scott [3] describes the typical delayed-onset movement disorder after a childhood injury as having a latency of 4.9 ± 7.8 years and a predominance of segmental or unilateral movements, as was observed with the authors' patient. However, these have been predominantly dystonic in character. None had chorea/ballismus as a manifestation of their movement disorder, as observed in this patient.

The evaluation for pediatric movement disorders of this type was pursued, as illustrated in Table 1. Other causes of the hemichorea/hemiballismus (Table 2) were excluded. The family history was not suggestive of Huntington's disease, and there was no history of drug intake. Her cardiac surgery and postoperative period were also unremarkable. No earlier signs of chorea, such as akathisia, dysarthria, or personality changes, were evident on careful chart review. That her initial endocarditis was documented as *S. viridans* and not the group A beta-hemolytic strain also argues against a latent Sydenham's chorea being reactivated. Furthermore, pathologic examination of her mitral valve did not demonstrate Aschoff bodies, such as are observed in rheumatic heart valve disease, or changes

Table 1. Causes of choreoathetosis/ballismus in children

Benign: hereditary chorea
Immunologic: systemic lupus erythematosus, antiphospholipid antibody syndrome, Henoch-Schönlein purpura, multiple sclerosis, Behçet's disease, polyarteritis nodosa
Infectious/postinfectious: Sydenham's chorea, subacute sclerosing panencephalitis, encephalitis, toxoplasmosis, syphilis, diphtheria, typhoid
Vascular: postpump (cardiac surgery) chorea, poststroke chorea, moyamoya disease, cerebral palsy
Neurometabolic/degenerative: juvenile Huntington's disease, neuroanthocytosis, propionic acidemia, Wilson's disease, Hallervorden-Spatz syndrome, Lesch-Nyhan disease, glutaric acidemia, pyruvate decarboxylase deficiency, GM ₂ gangliosidosis, phenylketonuria, Leigh's disease
Metabolic: hyperthyroidism, chorea gravidarum, Addison's disease, hypo/hyponatremia, hypo/hypercalcemia, hypo/hyperglycemia, liver failure, renal failure, porphyria, vitamins B ₁ and B ₁₂ deficiency
Drugs: metoclopramide, dopaminergics, cocaine, amphetamines, phenytoin, carbamazepine, valproic acid, ethosuximide, lithium, oral contraceptives, isoniazid, tricyclic antidepressants, antihistamines, anticholinergics, methylphenidate
Paroxysmal: paroxysmal dystonic (nonkinesigenic) choreoathetosis, paroxysmal kinesigenic choreoathetosis
Toxins: alcohol intoxication and withdrawal, anoxia, carbon monoxide, manganese, mercury, thallium, toluene
Tumors
Psychogenic

Data from Tuite and Lange [11].

typical of Libman-Sacks disease. The magnetic resonance imaging scan dated her stroke as old and localized it appropriately for the production of left-sided paresthesia.

Treatment of hemichorea secondary to stroke in adults is usually aggressive because of concomitant hemiballismus. The most effective drugs in large clinical trials have been phenobarbital, haloperidol, and reserpine, all of which have significant adverse effects [4]. Alternatively, gamma-aminobutyric acid (GABA)-ergic medications, such as sodium valproate, clonazepam, and baclofen [5], have been demonstrated to be effective for childhood

Table 2. Investigations in a case of choreoathetosis/ballismus in children

Complete blood count, peripheral smear, platelet count, erythrocyte sedimentation rate
Magnetic resonance imaging of the brain
Prothrombin time, partial thromboplastin time
Antinuclear antibody titer, lupus anticoagulant, antiphospholipid antibody syndrome
Antistreptolysin-O titer, throat culture, pregnancy test
Serum copper, ceruloplasmin, and 24-hour urinary copper, slit lamp eye examination for Kayser-Fleischer rings
Serum electrolytes, glucose, calcium, magnesium, uric acid, lactate, ammonia, liver function tests
Urinary organic acids, genetic testing for Huntington's disease
Thyroid function tests (triiodothyronine, thyroxine, thyrotropin)
Fluorodeoxyglucose positron emission tomography of the brain
Single-photon emission computed tomography of the brain

Data from Tuite and Lange [11].

Figure 1A (normal)

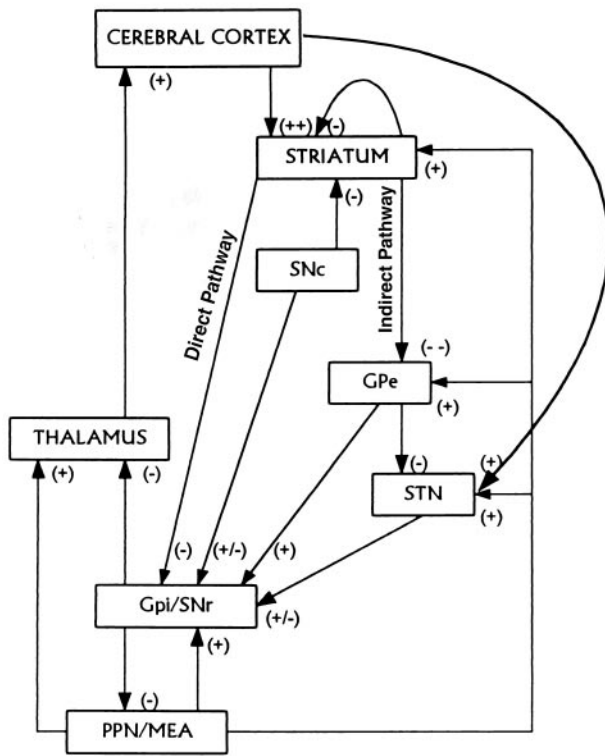


Figure 1B (in chorea)

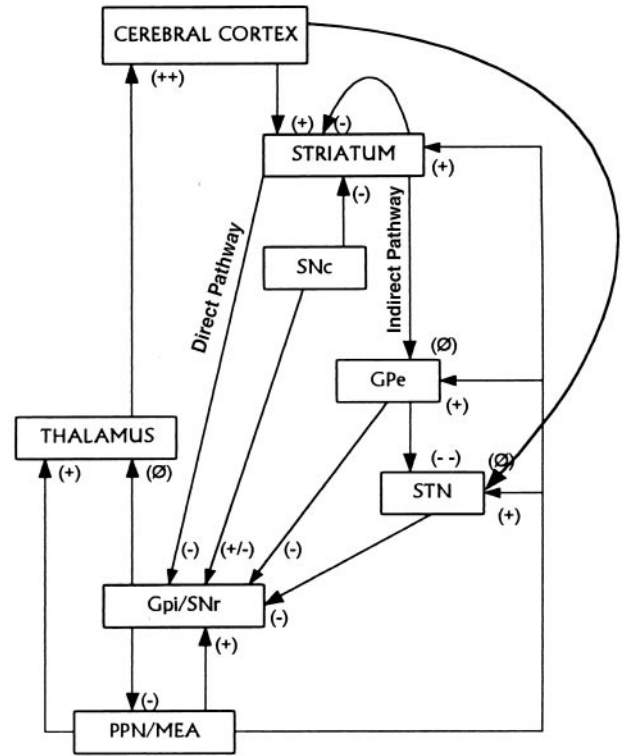


Figure 1. Basal ganglia movement modulation circuitry: (A) normal and (B) in chorea. Gpe: globus pallidus externa; Gpi: globus pallidus interna; PPN/MEA: pedunculopontine nucleus/midbrain extrapyramidal area; SNc: substantia nigra pars compacta; SNr: substantia nigra pars reticulata; STN: subthalamic nucleus; Striatum: caudate and putamen; +: excitatory input; -: inhibitory input; ∅: neutral input.

movement disorders caused by static encephalopathy, stroke, and closed head injury [6]. Carbamazepine has also been demonstrated to be effective in pediatric movement disorders, including nonhereditary chorea [7]. The major side effects from these drugs, hepatotoxicity and nausea, as well as the requirements for frequent blood monitoring, make their use less attractive. On the other hand, gabapentin has putative GABA-ergic effects and transient side effects (sedation, dizziness), with no proven toxicity or drug interactions to date [8]. It was recently demonstrated to be successful in the treatment of a 4-year-old female with familial paroxysmal choreoathetosis and to be well tolerated [9].

Figure 1A illustrates the normal basal ganglia circuitry, with the presumed mechanism of production of chorea illustrated in Figure 1B [10]. Thalamic stimulation of the motor cortex is enhanced as the final common pathway. Gabapentin has been demonstrated in animal models to increase GABA turnover rates in selective areas of the brain, specifically the thalamus. Its beneficial action in our patient may be related to increased inhibition of thalamic activity, thus dampening thalamic excitatory output to the cortex.

The introduction of gabapentin in this patient was slow, with titration within 4 weeks to 4,800 mg/day, equivalent to a dose of 75 mg/kg daily. No dose escalation was required during the subsequent 6 months. A 2-month trial discontinuation during the summer school break resulted

in recurrence of the choreiform movements of the tongue and left side of the face and dysarthric speech; autoimmune markers remained negative. One can infer that the movement disorder was caused by a static lesion because inflammatory and autoimmune chorea do not follow this type of course [11]. In the case of Sydenham's chorea the natural history is 3-6 months of chorea, with spontaneous resolution [12,13]. Antiphospholipid antibody syndrome tends to be complicated by recurrent episodes of microvascular thrombosis when anticoagulation therapy is not introduced [1]. The long-term efficacy and safety of gabapentin remains to be determined.

The authors thank Mya Jewers for assistance with manuscript preparation.

References

- [1] von Schevin E, Athreya BH, Rose CD, Goldsmith DP, Morton L. Clinical characteristics of antiphospholipid antibody syndrome in children. *Pediatrics* 1996;129:339-45.
- [2] Gordis L, Markowitz M. Rheumatic fever. In: Schaeffer AJ, ed: Major problems in clinical pediatrics. Philadelphia: WB Saunders, 1972:147-55.
- [3] Jankovic J, Scott BL. Delayed onset progressive movement disorders after static brain lesions. *Neurology* 1996;46:68-74.
- [4] Dewy RB, Jankovic J. Hemiballism-hemichorea, clinical and pharmacologic findings in 21 patients. *Arch Neurol* 1989;46:862-7.

- [5] **James Rowan A.** Valproate. In: Engel J, Pedley TA, eds. *Epilepsy: A comprehensive textbook*, 1st ed. New York: Lippincott-Raven, 1998:1599-607.
- [6] **Pranzatelli MR.** Antidyskinetic drug therapy for pediatric movement disorders. *J Child Neurol* 1996;11:355-69.
- [7] **Roig M, Montserrat L, Gallart A.** Carbamazepine: An alternative drug for the treatment of nonhereditary chorea. *Pediatrics* 1988;82:492-5.
- [8] **Taylor CP.** Emerging perspectives on the mechanism of action of gabapentin. *Neurology* 1994;44 (Suppl 5):S10-6.
- [9] **Chudnow RS, Mimbela RA, Owen DB, Roach S.** Gabapentin for familial paroxysmal dystonia choreoathetosis. *Neurology* 1997;49:1441-2.
- [10] **Wichmann T, Delong MR.** Physiology of the basal ganglia and pathophysiology of movement disorders of basal ganglia origin. In: Watts RL, Koller WC, eds. *Movement disorders/neurological principles and practice*. New York: McGraw-Hill, 1997:87-97.
- [11] **Tuite PJ, Lang AE.** Syndromes of disordered postures and movement. In: Berg BO, ed. *Principles of child neurology*, 1st ed. New York: McGraw-Hill, 1996:1513-41.
- [12] **Marques-Diaz MJ, Mercadante MT, Tucker D, Lombroso P, Sydenham's chorea.** *Psychiatry Clin North Am* 1997;20:809-20.
- [13] **Cardoso F, Eduardo C, Silva AP, Mota CC.** Chorea in 50 consecutive patients with rheumatic fever. *Mov Disord* 1997;12:701-3.