

Patterns of motor control reorganization in a patient with mirror movements

P. Balbi^{a,*}, L. Trojano^a, M. Ragno^b, A. Perretti^c, L. Santoro^c

^aSalvatore Maugeri Foundation, IRCCS, Rehabilitation Centre of Telesse, loc. S. Stefano in Lanterria, 82037, Telesse Terme (BN), Italy

^bDepartment of Neurology, C. and G. Mazzoni Hospital, Ascoli Piceno, Italy

^cDepartment of Neurological Sciences, Federico II University, Naples, Italy

Accepted 18 August 1999

Abstract

Objective: To explore motor control reorganization in a 40-year-old, left-handed patient with perinatally acquired mirror movements.

Methods: We performed simultaneous bilateral recordings of motor evoked potentials (MEPs) following focal transcranial magnetic stimulation (fTMS) and of central silent period (cSP) during unilateral voluntary contraction in abductor pollicis brevis (APB) and abductor digiti minimi (ADM) muscles.

Results: For both muscles the MEP study showed bilateral fast-conducting corticospinal projections from the right undamaged hemisphere, and residual contralateral projections from the left hemisphere. The cSP findings differed in the two muscles: the mirror phenomenon was bilateral in the ADM, but present only on the right side in the APB muscles; the mirror activity of right ADM and APB muscles was inhibited only by fTMS of the ipsilateral right motor cortex; the mirror phenomenon in the left ADM muscle was inhibited only by fTMS of the contralateral right motor cortex.

Conclusions: Mirror movements of right APB and ADM muscles were sustained by the ipsilateral connections from the undamaged motor cortex, while the mirror phenomenon in the left ADM muscle could be explained by hypothesizing a bilateral activation of motor cortices. This previously unreported electrophysiological picture demonstrates that different patterns of motor control may realize after perinatal cerebral lesions, even in different distal muscles of the same patient. © 2000 Elsevier Science Ireland Ltd. All rights reserved.

Keywords: Mirror movements; Motor evoked potentials; Silent period; Motor control; Perinatal cerebral lesion

1. Introduction

Mirror movements are involuntary movements on one side of the body which mimic the motor pattern of a voluntary contralateral movement. Mirror movements are common in young children and usually disappear after the first decade of life (Nass, 1985; Cohen et al., 1991; Müller et al., 1997). In some rare cases persistent mirror movements are inherited with autosomal dominance and incomplete penetrance and occur without other neurological manifestations (Haerer and Currier, 1966). Otherwise, this condition can be associated with various congenital malformations (Schott and Wyke, 1981; Forget et al., 1986; Schwankhaus et al., 1989; Kanouchi et al., 1997; Mayston et al., 1997), or it can occur after early unilateral lesions of motor pathways (Forget et al., 1986; Farmer et al., 1991; Carr et al., 1993; Kanouchi et al., 1997; Nirkko et al., 1997).

In patients with hemiplegic cerebral palsy and mirror movements the corticospinal axons from the undamaged motor cortex project to homologous motor neuron pools on both sides of the spinal cord (Britton et al., 1991; Farmer et al., 1991; Carr et al., 1993; Kanouchi et al., 1997; Nirkko et al., 1997); and in fact ipsilateral fast-conducting corticospinal connections from the undamaged hemisphere have been demonstrated by electrical or magnetic cortical stimulation in these cases (Carr et al., 1993; Netz et al., 1997; Nirkko et al., 1997). Thus, the undamaged hemisphere may become responsible for motor control of both body sides, as has been demonstrated by a recent functional magnetic resonance (fMRI) study (Nirkko et al., 1997).

It can be hypothesized, however, that this picture does not characterize every patient with perinatally acquired mirror movements, and that different patterns of motor output reorganization may be determined by several lesion-related variables. Carr et al. (1993) identified two possible types of motor reorganization after early cerebral lesions and suggested that their realization could depend on timing of

* Corresponding author. Tel.: +39-0824-909-258; fax: +39-0824-909-614.

E-mail address: balpie@iol.it (P. Balbi)

the lesion. The site of the perinatal lesion may also play a role in determining the reorganization patterns. If this were the case, different patterns of motor cortical reorganization could be detected in these patients, and even in different muscles of a single subject, provided that the lesion did not uniformly affect the damaged motor pathway.

We report the electrophysiologic evaluation of a patient with a perinatal left-hemisphere lesion who complained of mirror movements in the upper right limb when voluntarily moving the left, unaffected arm.

Our aim was two-folded: to verify whether our patient showed the pattern of motor cortical reorganization described in previous studies on similar patients, and whether the same pattern could be observed in two different distal muscles.

To identify the kind of motor reorganization we studied motor cortical activation during unilateral intended movements, combining MEPs and cSP recordings, as recently performed in patients with familial mirror movements (Cincotta et al., 1996).

2. Materials and methods

2.1. Case report

VA was a 40-year-old policeman with no family case history of mirror movements. His developmental milestones are reported to be normal. Notwithstanding some difficulties in learning complex motor skills, VA eventually achieved normal motor control and could play several sports (tennis, volley-ball) as an amateur. He was strongly left-handed (80% on the Oldfield questionnaire; Oldfield, 1971), but could write with either hand, and was capable of mirror writing. Since childhood VA presented involuntary movement of his right arm when he moved the left one; these movements did not interfere with his day to day activities. He himself did not report contralateral mirror activity during voluntary movement of the right arm.

He came to our observation in January 1997 when, after a closed-head injury which caused a 2-min loss of consciousness, he was admitted to Mazzoni Hospital (Ascoli Piceno, Italy) for a clinical and radiological check-up. At that time, the patient was co-operative and well oriented in time and space. The physical examination was unremarkable, except for mild hypoplasia of the right limbs (the patient wore shoes of different sizes). The neurological examination disclosed brisk tendon reflexes and mildly increased muscle tone in the right limbs. On both sides of the body strength was normal and the patient could perform independent arm and finger movements, both on verbal command and by imitating. However, transitive and, above all, intransitive hand and wrist movements of the left, unaffected arm evoked sustained, repetitive mirror movements on the right, affected side (grade 3, according to Woods and Teuber) (Woods and Teuber, 1978); milder mirror move-

ments were present for more proximal movements (Woods and Teuber's grade 2). Barely discernible but repetitive mirror phenomena were evident in the left arm as well (Woods and Teuber's grade 1).

Neuropsychological assessment on a battery of standard tests did not reveal any defect in attention, language, memory, praxis or abstract/logical thinking.

A brain MRI scan (Fig. 1) showed a hyperintense lesion in the periventricular region of the left hemisphere with enlargement of the left ventricle trigone, consistent with perinatal ischaemic damage, involving also the posterior limb of the internal capsule and, marginally, the thalamus. Mild unilateral atrophy of the left cerebral peduncle was also observed.

The patient gave informed consent to the study, which was approved by the local Ethics Committee.

2.2. Motor cortex stimulation

During the electrophysiologic examination the patient sat in an armchair with both forearms resting on a table. MEPs were recorded with surface electrodes (DANTEC 13L42) in a belly-tendon montage from left and right abductor pollicis brevis (APB) and abductor digiti minimi (ADM) muscles.

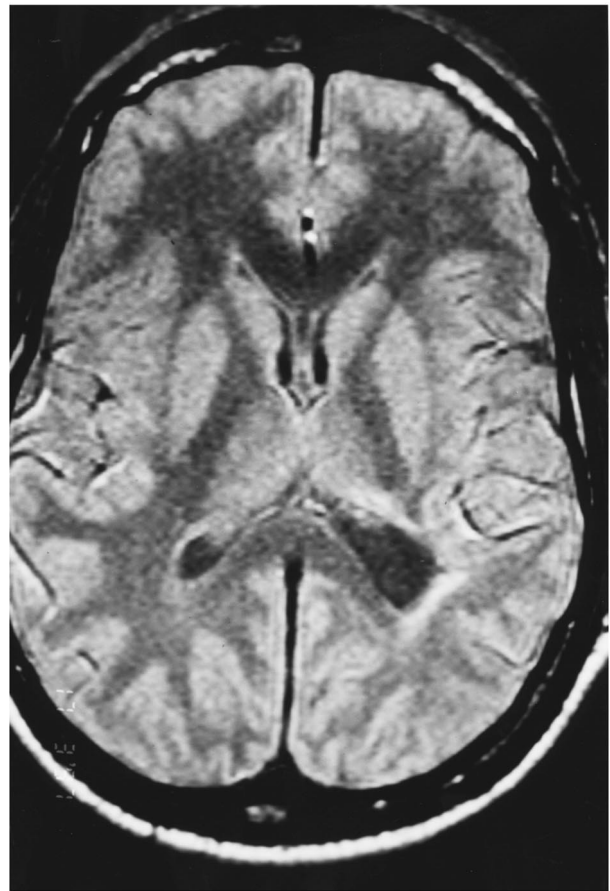


Fig. 1. Brain MRI scan showing the left periventricular lesion, involving also the posterior limb of the internal capsule and, marginally, the thalamus.

Focal transcranial magnetic stimulation (fTMS) was carried out using a DANTEC Mag2 magnetic stimulator with a 'figure-of-eight' focal coil (double 60 mm). The coil was placed tangentially over the hand motor cortex of each hemisphere. The intersection of the two wings (stimulating point) was positioned on the line joining the vertex and the earlobe at 5 cm lateral to the midline. Optimal coil position for each examined muscle was determined by moving the coil with displacements of 1 cm in every direction.

To achieve the most effective coil orientation on a transverse plane, the handle of the coil was held between 180° and 225° (coil orientation at '0°' when handle pointing toward the occiput, rotation in a counterclockwise direction) when stimulating the right hemisphere, and between 180° and 135° when stimulating the left hemisphere (Brasil-Neto et al., 1992).

For each hemisphere a stimulus intensity threshold was detected, defined as the lowest stimulator output able to produce an MEP with amplitude greater than or equal to 50 μ V in at least half of 6 consecutive trials. The stimulus intensity was set at 10% of the maximal output above the intensity threshold.

MEPs were recorded separately from relaxed APB and ADM on both sides. Signals were amplified and filtered (bandpass 20–2000 Hz); analysis time was 100 ms.

We defined the cSP as a period of EMG suppression following unilateral fTMS delivered during a tonic voluntary muscle contraction (cSP post-MEP). cSP was simultaneously recorded in right and left homologous hand muscles in four conditions: (1) left hand contraction–right hemisphere stimulation, (2) left hand contraction–left hemisphere stimulation, (3) right hand contraction–right hemisphere stimulation, (4) right hand contraction–left hemisphere stimulation. For each condition 4 traces were superimposed for purpose of analysis. The same paradigm was separately applied for APB and ADM muscles. Moreover, the entire cSP study was performed on two separate occasions: one at submaximal effort and the other at approximately 20% of the patient's maximal force. Analysis time was 500 ms, with 100 ms preceding the fTMS. Since the onset of cSP could be hidden by the MEP, the duration of the silent period was measured from the onset of MEP to the restoration of EMG discharge after the MEP.

3. Results

3.1. Motor evoked potentials

The intensity thresholds able to evoke an MEP in contralateral muscles was slightly higher for damaged than undamaged hemisphere stimulation (65% versus 55% of maximum output).

The undamaged hemisphere fTMS (Fig. 2A,C) could evoke MEPs from the relaxed contralateral muscles (latency: APB = 23.4 ms, ADM = 22.7 ms; amplitude:

APB = 6 mV, ADM = 4.1 mV). The same stimulus always evoked ipsilateral muscle responses with latencies identical to the contralateral ones. The amplitudes of the ipsilateral responses were 3.5 mV for the ADM muscle and 0.4 mV for the APB muscle.

The fTMS of the damaged hemisphere (Fig. 2B,D) evoked MEPs from relaxed contralateral APB and ADM (latency: APB = 22.7 ms, ADM = 22.7 ms; amplitude: APB = 0.6 mV, ADM = 0.7 mV). The damaged hemisphere fTMS evoked no ipsilateral responses in either examined muscle.

3.2. Central silent period

The degree of background EMG activity was different during submaximal and minimal effort while cSP duration was identical under both conditions. Therefore, we will describe in detail only the findings obtained at submaximal contraction.

3.2.1. APB recordings (Fig. 3)

(a) *Left voluntary contraction.* The voluntary contraction of the left APB muscle also gave rise to weak but clear EMG activity in the right APB muscle (mirror phenomenon). During this bilateral muscle activity, the undamaged (right) hemisphere fTMS produced a cSP in the left APB muscle (duration = 102 ms). Moreover, the same stimulus was also able to inhibit the ipsilateral mirror contraction; cSP post-MEP duration was identical to that recorded on the left side (Fig. 3A).

Stimulation of the damaged (left) hemisphere evoked an MEP in the right APB muscle, without inhibiting the continuous mirror contraction (no cSP post-MEP). The same stimulus did not interfere with the EMG activity of the ipsilateral left APB muscle (Fig. 3B).

(b) *Right voluntary contraction.* The voluntary contraction of the right APB muscle did not elicit EMG mirror activity on the left side. During this activity, the undamaged hemisphere fTMS evoked an isolated MEP in the left APB muscle and did not inhibit the steady EMG activity of the right muscle (Fig. 3C).

The stimulation of the damaged hemisphere showed a cSP from the contralateral APB muscle (duration = 109 ms) (Fig. 3D).

3.2.2. ADM recordings (Fig. 4)

(a) *Left voluntary contraction.* During voluntary contraction of the left ADM muscle we recorded mirror activity in the right ADM muscle. Focal stimulation of the undamaged hemisphere inhibited both contralateral (voluntary) and ipsilateral (mirror) ADM muscle contraction. Duration of cSP was identical (125 ms) on both sides (Fig. 4A).

After damaged hemisphere fTMS, an MEP without post-MEP cSP was barely discernible among the right mirror EMG activity; the same stimulus did not inhibit EMG activity of the left ADM muscle (Fig. 4B).

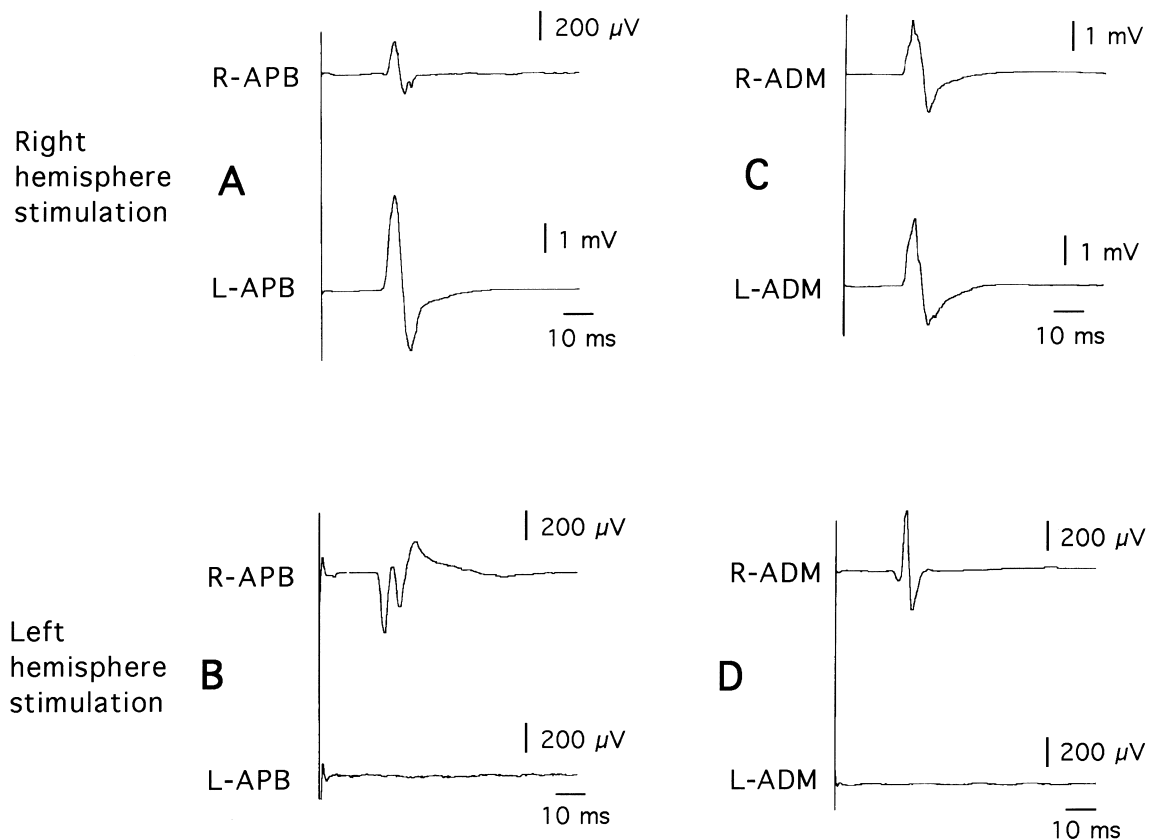


Fig. 2. MEPs from bilateral recordings of APB and ADM muscles following right and left motor cortex fTMS (single trial on each trace).

(b) *Right voluntary contraction.* Voluntary contraction of the right ADM induced mirror activity on the contralateral muscle, a result never recorded from the APB muscle. During this task, undamaged hemisphere fTMS evoked an MEP without post-MEP cSP in the right ADM muscle (no inhibition of ipsilateral, voluntary activity). The same stimulus inhibited mirror activity of the left ADM muscle; cSP duration was 82 ms (Fig. 4C).

The damaged hemisphere fTMS evoked a cSP from the right ADM muscle (133 ms); mirror activity in the left ADM muscle was not completely inhibited by the focal ipsilateral stimulus (Fig. 4D).

4. Discussion

Mild hypoplasia and hyperreflexia of right limbs and MRI findings in our patient were consistent with the diagnosis of a mild perinatal lesion of the left central motor pathways. These findings, together with the lack of family history, suggested that our patient's mirror movements were of the sporadic congenital form. However, the clinical picture was quite uncommon because mirror movements were predominant in the right, affected arm when the patient performed actions with the left arm. On the contrary, mirror movements are often reported to prevail in the unaffected arm

(Britton et al., 1991; Farmer et al., 1991; Nirkko et al., 1997) or to be symmetric after age 10 years (Nass, 1985) in such patients.

To identify the pattern of our patient's motor cortical reorganization we adopted and extended a recently reported electrophysiologic procedure (Cincotta et al., 1996) combining the study of MEP and post-MEP cSP.

While the MEP study in our patient produced similar findings in APB and ADM muscles, the cSP findings differed in these two muscles. During unilateral voluntary contraction of APB muscles, mirror EMG activity was present only on the right side during contraction of the left arm. cSP results showed that only left damaged hemisphere stimulation could inhibit the voluntary contraction on the right side. On the other hand, the mirror movements in the right APB were completely inhibited by undamaged hemisphere fTMS only. These findings strongly suggest that voluntary contraction of the right APB muscle was exclusively sustained by activation of the damaged, but still active, motor pathway from the left hemisphere. The mirror movements on the right side, however, were sustained by the presence of right-hemisphere fast-conducting cortico-spinal connections, projecting bilaterally and activated when the patient performed voluntary actions with the left arm (Fig. 5A). This electrophysiological picture has never been reported in previous studies.

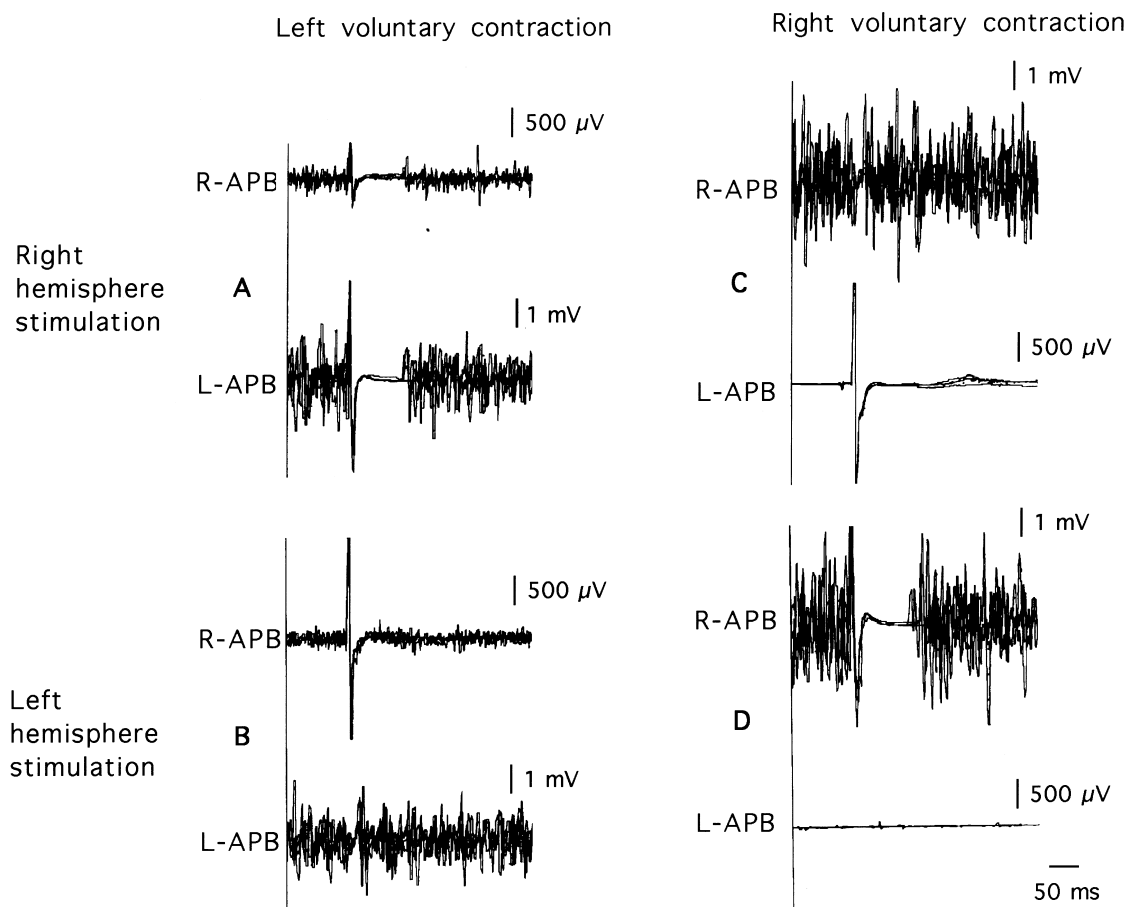


Fig. 3. Bilateral recordings of cSP from APB muscles during unilateral voluntary contractions (4 traces superimposed on each panel).

Electrophysiologic findings in ADM muscles differed in several respects from those in APB muscle. First, unilateral contractions gave rise to mirror EMG activity bilaterally. Second, MEP from the right ADM muscle showed greater amplitude after ipsilateral fTMS than after contralateral stimulation. However, only left fTMS could inhibit voluntary contraction of the right ADM muscle, thus demonstrating that the contralateral affected motor pathway was alone responsible for voluntary motor control of the right side, despite the strong ipsilateral connections.

Finally fTMS of the damaged hemisphere during contraction of the right ADM muscle induced a cSP on the right side, but was unable to inhibit the mirror activity of the muscle on the left side; this mirror activity was inhibited by right hemisphere fTMS only. These findings, together with the absence of ipsilateral left cortico-spinal connections strongly suggest that the mirror activity of the left hand could be due to the simultaneous activation of both hemispheres (Fig. 5B). This bilateral cortical activation has been hypothesized in patients with familial mirror movements (Cohen et al., 1991; Cincotta et al., 1996), but has never been demonstrated in patients with the sporadic syndrome.

In synthesis, the genesis of mirror movements on the right

side during voluntary contractions of the left unaffected arm was identical in APB and ADM muscles: the undamaged motor cortex was activated for voluntary left side movements but determined the mirror phenomenon in the right hand via its ipsilateral projections. The mirror movements on the left hand were seen instead only in ADM muscle and were determined by the simultaneous activation of damaged and undamaged motor cortices. These findings suggest that different patterns of cortical reorganization took over the motor control of our patient's hand muscles.

After early unilateral cerebral lesions, central motor pathways may undergo different mechanisms of functional recovery and the presence of mirror movements is considered the clinical evidence of such a reorganization. In a seminal study on 33 subjects with hemiplegic cerebral palsy Carr et al. (1993) described two patterns of motor reorganization. The first one (in subjects with mirror movements) was characterized by bilateral short-latency MEPs after stimulation of the undamaged hemisphere and no MEP following damaged hemisphere fTMS. In these patients the undamaged hemisphere had taken over the motor control of both arms by the branching of cortico-spinal axons that innervate homologous right and left spinal motor neuron pools. Recently, Nirkko et al. (1997) have confirmed this

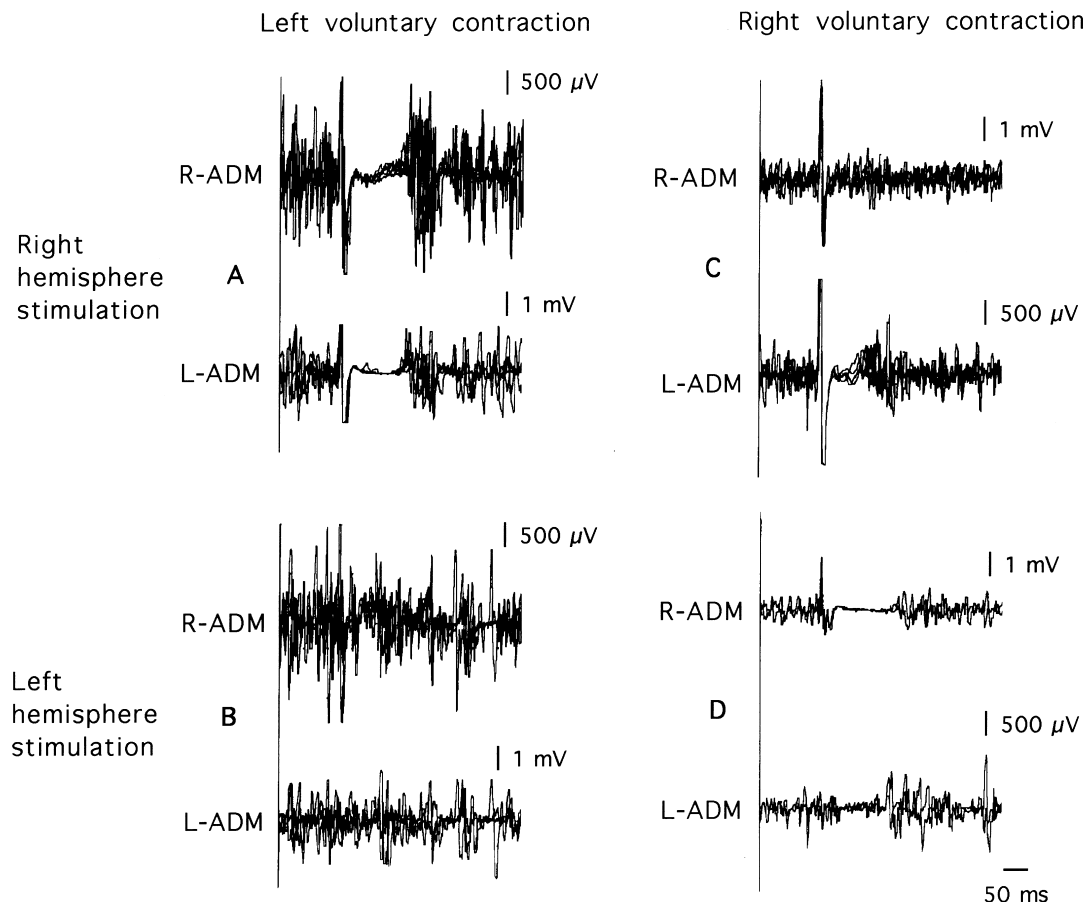


Fig. 4. Bilateral recordings of cSP from ADM muscles during unilateral voluntary contractions (4 traces superimposed on each panel).

kind of motor recovery by means of a functional magnetic resonance study.

The second pattern of central motor reorganization (in subjects without mirror movements) was characterized by the presence of ipsilateral MEPs smaller and slower than the contralateral ones after undamaged hemisphere fTMS. Some patients from this group (those with the best motor recovery) showed contralateral MEPs after stimulation of the damaged hemisphere. The authors hypothesized that in these cases motor pathways from the undamaged hemisphere were distributed as non-branched projections.

Our patient showed some features of each of the two groups identified by Carr et al. (1993). He had mirror movements and exhibited bilateral short-latency MEPs following undamaged hemisphere fTMS found in the first group, and short-latency contralateral MEP after fTMS of the damaged hemisphere seen in the second group. Moreover, in our patient the motoneuronal spinal pool innervating muscles of the right, affected, arm received both ipsi- and contralateral fast-conducting cortico-spinal projections; this finding has never been reported in patients with sporadic mirror movements, although it is common in the familial, symmetric form (Cohen et al., 1991; Cincotta et al., 1996).

Our patient's clinical and electrophysiologic abnormalities could be explained by a very early cerebral lesion

sparing some corticospinal connections from the damaged hemisphere. This lesion could have determined the branching of ipsilateral corticospinal fibers from the unaffected hemisphere, but the role of this ipsilateral motor pathway could have been limited by the residual projections from the damaged motor cortex.

We suggest that, with regard to the APB muscle motor control, the residual motor cortex of the damaged hemisphere may have recovered both the motor activation of the right arm, and the inhibition of homologous motor areas of the contralateral hemisphere. This could explain the lack of any active role of the undamaged hemisphere in ipsilateral movement control; these persistent ipsilateral connections were active only during left voluntary movements, without supplying any functional advantage to the patient's motor performances (Turton et al., 1996; Netz et al., 1997).

As to ADM muscles in the same subject, the lesion could have also impaired transcallosal inhibition of homologous motor areas exerted by the cortical areas of the damaged hemisphere. In this case the undamaged hemisphere would be activated during the ipsilateral muscle contractions, thus generating contralateral mirror movements.

In conclusion, this paper demonstrates that not all patients with perinatally acquired mirror movements present a

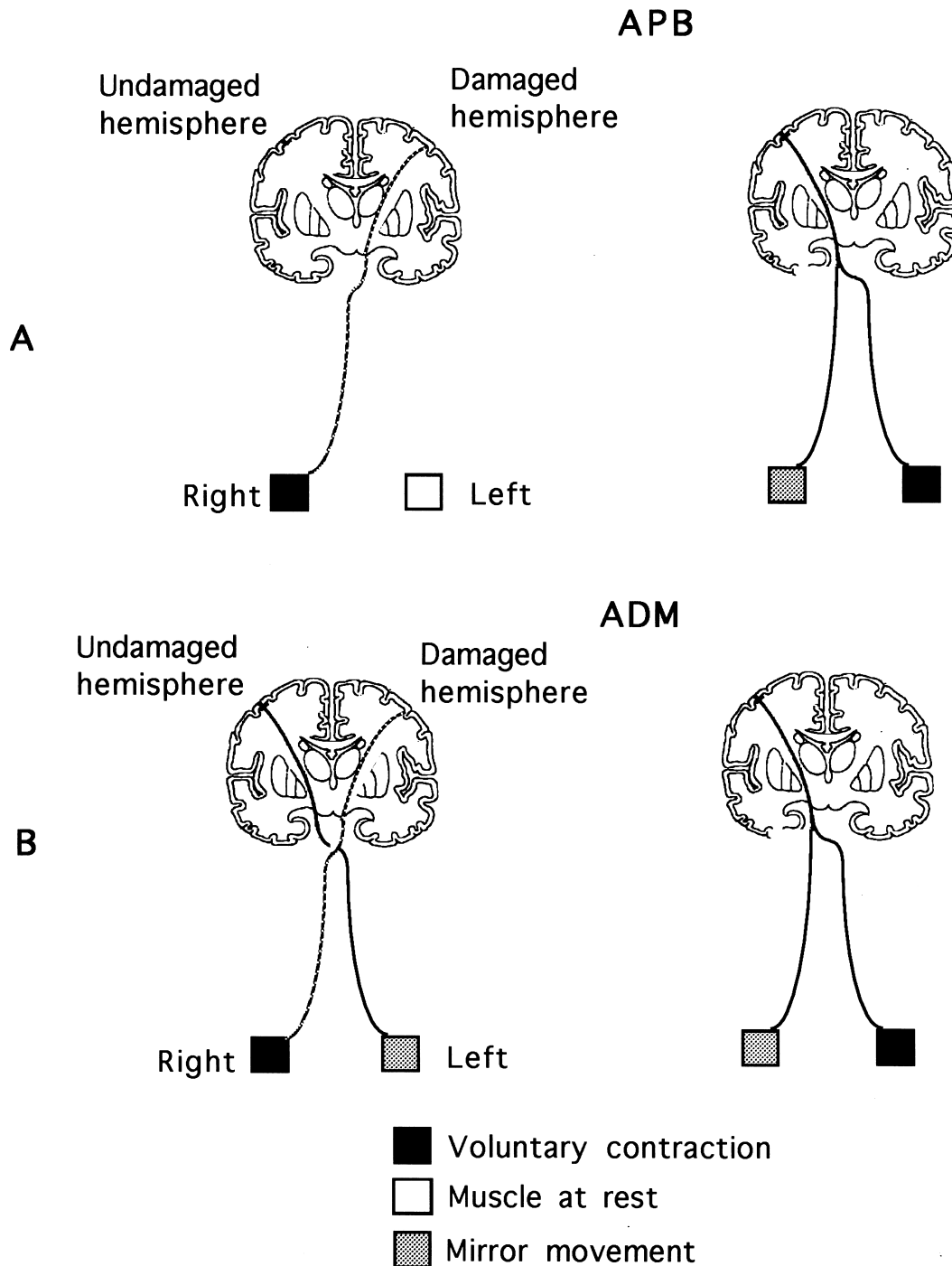


Fig. 5. Patterns of motor activation during voluntary unilateral contraction of APB and ADM muscles (full lines depict cortico-spinal projections from the undamaged hemisphere; dotted lines show the damaged cortico-spinal pathway).

homogenous pattern of motor cortical reorganization, which can differ even in two distal muscles in the same subject. Mirror movements are often reported to be more evident in distal than in proximal muscles and to be elicited more easily by some tasks than by others (Woods and Teuber, 1978). However, to the best of our knowledge, this is the first report of a patient showing different patterns of motor cortical reorganization in two distal muscles.

A general model of motor reorganization in patients with early unilateral cerebral lesion and mirror movements should thus take into account several variables, with timing of the lesion and its extension upon critical cortical regions playing a crucial role. To formulate a comprehensive interpretation of motor reorganization, further detailed neurophysiological data, inclusive of the study of cSP and of multiple muscle recordings, are necessary.

Acknowledgements

We thank the patient VA for his co-operation throughout the experimental sessions.

References

- Brasil-Neto JP, Cohen LG, Panizza M, Nilsson J, Roth BJ, Hallett M. Optimal focal transcranial magnetic activation of the human motor cortex: effects of coil orientation, shape of the induced current pulse, and stimulus intensity. *J Clin Neurophysiol* 1992;9:132–136.
- Britton TC, Meyer B-U, Beneck R. Central motor pathways in patients with mirror movements. *J Neurol Neurosurg Psychiatry* 1991;54:505–510.
- Carr J, Harrison LM, Evans AL, Stephens JA. Patterns of central motor reorganization in hemiplegic cerebral palsy. *Brain* 1993;116:1223–1247.
- Cincotta M, Lori S, Gangemi PF, Barontini F, Ragazzoni A. Hand motor cortex activation in a patient with congenital mirror movements: a study of the silent period following focal transcranial magnetic stimulation. *Electroenceph clin Neurophysiol* 1996;101:240–246.
- Cohen LG, Meer J, Tarkka I, Bierner S, Leiderman DB, Dubinsky RM, Sanes JN, Jabbari B, Branscum B, Hallett M. Congenital mirror movement: Abnormal organization of motor pathways in two patients. *Brain* 1991;114:381–403.
- Farmer SF, Harrison LM, Ingram DA, Stephens JA. Plasticity of central motor pathways in children with hemiplegic cerebral palsy. *Neurology* 1991;41:1505–1510.
- Forget R, Boghen D, Attig E, Lamarre Y. Electromyographic studies of congenital mirror movements. *Neurology* 1986;36:1316–1322.
- Haerer AF, Currier RD. Mirror movements. *Neurology* 1966;16:757–760.
- Kanouchi T, Yokota T, Isa F, Ishii K, Senda M. Role of ipsilateral motor cortex in mirror movements. *J Neurol Neurosurg Psychiatry* 1997;62:629–632.
- Mayston MJ, Harrison LH, Quinton R, Stephens JA, Krams M, Bouloux P-MG. Mirror movements in X-linked Kallmann's syndrome. I: a neurophysiological study. *Brain* 1997;120:1199–1216.
- Müller H, Kass-Iliyya F, Reitz M. Ontogeny of ipsilateral corticospinal projections: a developmental study with transcranial magnetic stimulation. *Ann Neurol* 1997;42:705–711.
- Nass R. Mirror movement asymmetries in congenital hemiparesis: the inhibition hypothesis revisited. *Neurology* 1985;35:1059–1062.
- Netz J, Lammers T, Hömberg V. Reorganization of motor output in the non-affected hemisphere after stroke. *Brain* 1997;120:1579–1586.
- Nirkko AC, Rösler KM, Ozdoba C, Heid O, Schroth G, Hess CV. Human cortical plasticity: functional recovery with mirror movements. *Neurology* 1997;48:1090–1093.
- Oldfield RC. The assessment and analysis of handedness: the Edinburgh Inventory. *Neuropsychologia* 1971;9:97–113.
- Schott GD, Wyke MA. Congenital mirror movements. *J Neurol Neurosurg Psychiatry* 1981;44:586–599.
- Schwankhaus JD, Currie J, Jaffe MJ, Rose SR, Sherins RJ. Neurologic findings in men with isolated hypogonadotropic hypogonadism. *Neurology* 1989;39:223–226.
- Turton A, Wroe S, Trepte N, Fraser C, Lemon RN. Contralateral and ipsilateral EMG responses to transcranial magnetic stimulation during recovery of arm and hand function after stroke. *Electroencephal clin Neurophysiol* 1996;101:316–328.
- Woods BT, Teuber HL. Mirror movements after childhood hemiparesis. *Neurology* 1978;28:1152–1158.