

Risk factors and outcome of patients with carotid artery stenosis presenting with lacunar stroke

D. Inzitari, MD; M. Eliasziw, PhD; B.L. Sharpe, BScN; A.J. Fox, MD; and H.J.M. Barnett, MD, for the North American Symptomatic Carotid Endarterectomy Trial Group

Article abstract—*Objective:* To examine the relationship between carotid artery stenosis, other risk factors, and lacunar stroke. *Background:* Carotid artery stenosis in patients presenting with lacune stroke may be coincidental or causal. The distinction by risk factor profile is uncertain. The risk and cause of subsequent stroke, and benefit of carotid endarterectomy (CE) is unknown. *Methods:* Stroke in patients entering the North American Symptomatic Carotid Endarterectomy Trial were classified as nonlacunar, possible lacune (symptoms without CT lacunae), or probable lacune (symptoms with CT lacunae). *Results:* Of 1,158 patients with hemispheric stroke, 493 had features of lacunar stroke (283 possible and 210 probable). Lacunar stroke presented more commonly in patients with milder (<50%) degrees of internal carotid artery (ICA) stenosis ($p = 0.003$). History of diabetes and hyperlipidemia, not hypertension, were associated independently even after accounting for the degree of stenosis. Medically treated patients presenting with nonlacunar stroke had a low risk of subsequent lacunar events of 2.9% at 3 years in comparison with 9.2% for probable lacunar presentation ($p = 0.03$). For patients with 50 to 99% ICA stenosis, the relative risk reductions (RRRs) in stroke from CE were 35% when the presenting stroke was probable lacunar versus 61% when the stroke was nonlacunar. Patients presenting with a possible lacunar stroke had a 53% RRR. *Conclusions:* History of diabetes and hyperlipidemia were more important than arterial hypertension as risk factors for patients with lacunar stroke. Patients presenting with lacunar stroke more often had milder ICA stenosis. Although CE reduced the risk of stroke in all patients with 50 to 99% ICA stenosis, lesser benefits were observed in patients presenting with lacunar stroke. **Key words:** Lacunes—Ischemic stroke—Carotid artery stenosis—Carotid endarterectomy—Arteriosclerosis.

NEUROLOGY 2000;54:660–666

Ever since Fisher made his clinicopathologic observations,^{1,2} the term *lacunar infarction* has become established in the literature. Subsequent pathologic evidence is sparse. Among patients with cerebral infarction of diverse cause, a number of distinct clinical syndromes have been identified that are associated with small deep infarcts or lacunes. These are presumed to result from the occlusion of single perforating arteries with characteristic arteriolosclerotic vascular lesions including lipohyalinosis.

The concept of the lacunar hypothesis has been a subject of controversy. The lacunar syndromes have not been found to be exclusively pathognomonic of small-artery disease.³ Cardioembolism^{4,5} and large-artery atherosclerosis^{6,7} have been implicated as potential causes in a small number of patients presenting with the clinical and radiologic features consistent with lacunar stroke. Carotid disease has been reported to produce these lesions by embolic⁷ or hemodynamic⁸ mechanisms. Imaging techniques sensitive enough to reveal abnormalities in the small penetrating arteries are lacking.

Lacunar infarction has been described in association with selective risk factors. The association varies in different reported series. Different risk profiles, especially implicating arterial hypertension and diabetes mellitus,⁹ have been described in patients with single or multiple lacunar lesions.¹⁰ Patients with lacunar lesions in the centrum semiovale have been reported to have risk factors and mechanisms distinct from those with lesions in the deep basal structures.¹¹ The current study examined the role of internal carotid artery (ICA) stenosis and other vascular risk factors in the presence of lacunar stroke, and for the first time examined the outcome in medically or surgically treated patients presenting with lacunar syndrome and ICA stenosis.

Methods. The North American Symptomatic Carotid Endarterectomy Trial (NASCET) was a large, randomized trial that evaluated the benefit of carotid endarterectomy (CE) in patients with ICA stenosis who had symptoms in the appropriate territory. Patients with infarcts compatible with lacunes were not excluded from randomization as

From the Department of Neurological and Psychiatric Sciences (Dr. Inzitari), University of Florence, Italy; the Departments of Clinical Neurological Sciences (Drs. Barnett, Eliasziw, and Fox) and Epidemiology and Biostatistics (Dr. Eliasziw), University of Western Ontario, London, Ontario; and the John P. Robarts Research Institute (Drs. Barnett and Eliasziw, and B. Sharpe), London, Ontario, Canada.

Supported by grant R01-NS-24456 from the National Institute of Neurological Disorders and Stroke.

Received June 11, 1999. Accepted in final form September 25, 1999.

Address correspondence and reprint requests to Dr. H.J.M. Barnett, Robarts Research Institute, 100 Perth Drive, PO Box 5015, London, Ontario, Canada, N6A 5K8; e-mail: barnett@rri.on.ca

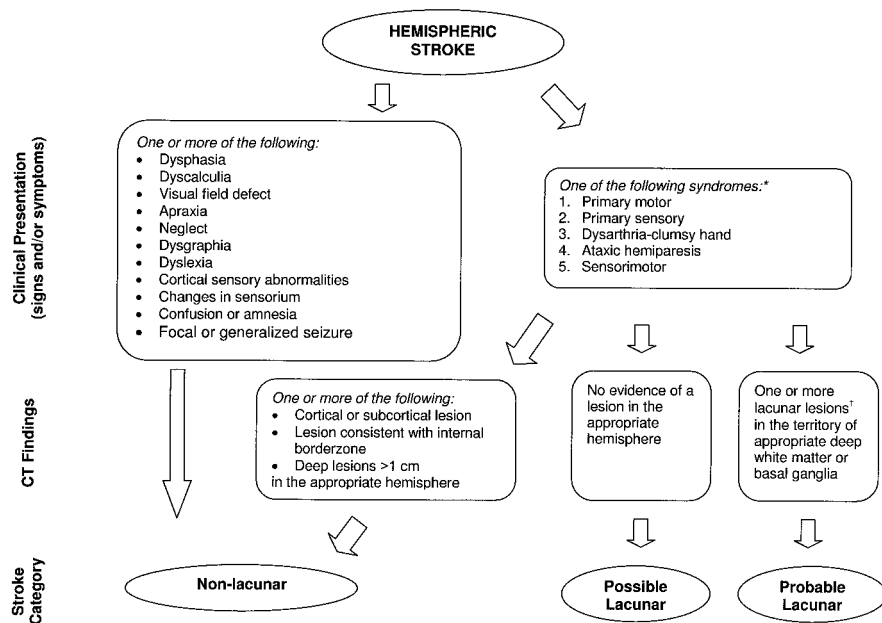


Figure 1. Clinical and radiologic criteria used to classify hemispheric stroke. *The syndromes were based on signs or symptoms in one or more areas involving the face, arm, or leg. †A lacunar lesion was identified as round or oval in shape, measuring ≤ 1 cm, located in a territory supplied by deep or superficial small perforating arteries, not in the cortical territories, and without characteristics of internal border zone infarcts.

long as carotid lesions appropriate to the symptoms were present on angiography. The identification of such patients with systematic angiographic assessment of the carotid lesions and the detailed recording of risk factors in a large group of stroke patients provided the data for this study. Complete baseline data for clinical risk factors were available for all patients. Only 8% of the laboratory values were unavailable.

Patients with ischemic symptoms, retinal or hemispheric, were recruited if their last appropriate symptoms occurred within 180 days of randomization, and if no cardiac source of embolism was identified. Other exclusion criteria included life-threatening or other disabling conditions that could interfere with the likelihood of 5-year survival, and patients who were medically unfit for surgery. Full details of the study protocol have been reported elsewhere.¹²

At entry, selective carotid angiography (biplane, anterior or posterior, lateral or oblique projections) and head CT were mandatory for all patients. Hard copies of all angiograms and CT brain scans were reviewed at the central data office. The degree of stenosis was assessed using previously reported criteria.¹³ For the purpose of the current study, severity of ICA stenosis was divided into three categories: mild (<50%), moderate (50 to 69%), and severe (70 to 99%).

All NASCET patients with hemispheric stroke as the entry event were included in the current study. The definition of lacunar stroke in NASCET was a combination of clinical information recorded in the case report forms (past medical history and details of symptoms and signs) and CT scans obtained on entry. MR images were not used because of their extreme sensitivity and their absence from the earlier part of the study. The CT scans were reread for the current study to assess systematically the existence of lesions and to classify them subsequently according to site, size, number, and presumed age. Clinical and radiologic assessments were performed independently from one another (D.I.). Using this information, the presumed type of stroke in each patient was classified into one of three categories: nonlacunar, possible lacunar, and probable lacu-

nar (figure 1). A nonlacunar diagnosis was made automatically in the presence of defined symptoms or signs. For the remaining stroke events, a distinction was made among the five classic lacunar syndromes.¹⁴ If CT showed a cortical or subcortical lesion, or lesions consistent with internal border zone infarct in the appropriate hemisphere, even if these lesions were combined with CT lacunar lesions, the infarct was categorized as nonlacunar. The remaining strokes were divided according to the CT images into those with no lesions and those with lacunar lesions in the appropriate hemisphere. Patients with clinical lacunar syndromes and one or more lacunar lesions in the hemisphere appropriate to symptoms were categorized as having probable lacunar stroke. Patients with a clinical presentation consistent with a lacunar syndrome, but without any lesion visible in the appropriate hemisphere, were classified as possible lacunar stroke. A distinction was made between patients in whom more than one body area was involved and those in whom only one area was the site of symptoms and signs. Individuals with lacunar lesions detected by brain imaging alone in the absence of an appropriate clinical history were not considered for the purposes of this study to have a lacunar stroke. Patients with lesions on CT who had symptoms lasting less than 24 hours were not designated as having lacunar stroke.

To be defined as a lacunar lesion by CT the following criteria had to be met: 1) round or oval in shape, 2) measuring ≤ 1 cm, 3) located in the typical territory supplied by deep or superficial small perforating arteries, 4) not in cortical territories, and 5) without the morphologic and topographic distribution consistent with partial internal border zone infarcts (multiple, discrete rounded lesions forming a linear chain of lesions in the internal watershed zone, according to the definition of Bladin and Chambers¹⁵). Probable lacunar strokes were subdivided according to the imaging identification of a single lacune, or of lacunes in multiple territories, provided one was ipsilateral to the symptomatic artery. Lacunes in the centrum semiovale included either a single lacune causing the symptoms or additional clinically silent lesions. Particular attention was given to examining the cortical regions on

the CT scan to identify all possible lesions that could account for the clinical symptoms other than a deep lesion.

All outcome stroke events were classified regarding their underlying cause (lacunar, large-artery, or cardioembolic). Lacunar events occurring during patient follow-up were defined by the same procedure used to define entry stroke. The criteria for cardioembolic stroke have been described in detail elsewhere.¹⁶ They included atrial fibrillation, myocardial infarction and its thrombotic or cardiac wall sequelae, the presence of valvular lesions, and the need for cardiac interventional procedures.

Validation of the clinical and radiologic definitions. The validity of the lacunar definitions was assessed by comparing the diagnosis made by D.I. with an independent diagnosis made by a stroke neurologist from a chart review conducted in 92 NASCET patients in a single hospital. Sensitivity and specificity of diagnosing lacunar stroke (possible and probable combined) was calculated using criteria agreed to for the current study versus conclusions drawn from the independent chart review. Using this method, the lacunar stroke definition proved to be 84% sensitive and 74% specific. For testing the reliability of the radiologic definition, three observers (one neuroradiologist [A.J.F.] and two neurologists) examined the images in 53 brain scans of 106 hemispheres. The kappa agreement for rating nonlacunar, lacunar, or no lesion in the hemisphere appropriate to a clinical event was 0.73. Overall, the definition of lacunar stroke appears to be valid and reliable.

Statistical analysis. Ordinal regression modeling was used to assess the relative contribution of different patient characteristics to the type of stroke, after controlling for the potentially confounding effects of other patient factors. All continuous variables were dichotomized to obviate linearity assumptions. Adjusted odds ratios (ORs), as measures of association, with corresponding 95% CIs were used in reporting the results.

The risks of stroke at 3 years, ipsilateral to the symptomatic randomized artery, were derived from Kaplan-Meier event-free survival curves for both medically and surgically treated patients. The primary analysis, estimating the risks of each cause of stroke, was based on the entire group of hemispheric stroke patients who entered the NASCET. In an additional analysis, a comparison of stroke risks between medically and surgically treated patients was performed on the subset of patients who had 50 to 99% ICA stenosis. Patients with ICA stenosis less than 50% were not considered because they do not benefit from CE.¹⁷ Differences among the risks were assessed for statistical significance using a logrank test, and relative risk reductions (RRRs) with 95% CIs were computed.

Results. Among the 1,158 patients who entered the NASCET with a hemispheric stroke, 665 (57.5%) were considered to be nonlacunar, 283 (24.4%) were rated possible, and 210 (18.1%) were rated as having probable lacunar stroke. More than half of the patients with a lacunar stroke presented with a primary motor syndrome, and approximately one-quarter of patients presented with sensorimotor deficits. The distribution of lacunar syndromes was similar among patients with possible or probable lacunar stroke (table 1). Patients with probable lacunar lesions were 2.4 times as likely to have two or more body areas affected ($p < 0.001$) than those designated as possible. Slightly less than half the patients had two or more lacu-

Table 1 Details of lacunar stroke in the North American Symptomatic Carotid Endarterectomy Trial

Characteristic	Possible* lacunar, % (n = 283)	Probable lacunar, % (n = 210)
Lacunar syndrome		
Primary motor	53.7	60.5
Primary sensory	6.4	3.3
Dysarthria-clumsy hand	4.6	7.1
Ataxic hemiparesis	7.8	10.0
Sensorimotor	27.5	19.1
No. of body areas involved		
One	22.6	11.0
Two or more	77.4	89.0
No. of lacunes on CT		
One	—	58.6
Two or more	—	41.4
Lacunes in centrum semiovale	—	34.3

* Possible = the absence of a CT lesion.

nar lesions on CT, and approximately one-third of the lesions were located in the centrum semiovale.

No difference in age, gender, or race was noted across the three groups (table 2). The most significant finding was that lacunar stroke was more likely to be associated with milder degrees of ICA stenosis (OR = 1.42, $p = 0.003$), especially when the stroke was designated as probable. A subgroup analysis using finer gradations of ICA stenosis (figure 2) supported this finding. Probable lacunar stroke occurred in 12.2% of the patients with a 70 to 99% stenosis and increased to 21.1% in patients with < 50% stenosis. No relationship with plaque irregularity and ulceration was observed (OR = 1.07). There was a lower prevalence of previous TIA or stroke among lacunar patients (OR = 0.78, $p = 0.038$), even after adjusting for all other factors.

Only a history of diabetes mellitus and history of hyperlipidemia remained associated independently with lacunar stroke (OR = 1.37, $p = 0.049$, and OR = 1.33, $p = 0.020$ respectively) in the final model (table 3). A subgroup analysis of the 210 patients with probable lacunar stroke did not identify any particular combination of risk factors associated with multiple lacunes on CT. However, patients ≥ 65 years (OR = 1.9, $p = 0.04$) and with cholesterol levels ≥ 6.5 mmol/L (OR = 2.4, $p = 0.02$) were found to be related to the presence of lacunes in the centrum semiovale. All other factors were not significant and had adjusted ORs relatively close to one. The small number of missing laboratory values had no effect on the analyses.

Although the large-artery lesion was the predominant cause of subsequent ipsilateral stroke in medically treated patients (figure 3), there was a threefold increase in the risk of lacunar stroke in patients who presented with probable lacunar stroke in comparison with those with nonlacunar stroke (9.2% versus 2.9%, $p = 0.03$). Cardioembolism as a cause of stroke was rare and less frequent in patients presenting with a lacunar syndrome (0.8% versus 2.3%).

Among the medically treated patients presenting with

Table 2 Relation of patient characteristics to presenting category of stroke

Characteristic	Nonlacunar, % (n = 665)	Possible lacunar, % (n = 283)	Probable lacunar, % (n = 210)	Adjusted OR*	Adjusted 95% CI*
Age ≥ 65 y	62.4	62.9	58.6	0.97	0.75–1.26
Male sex	70.1	70.7	74.3	1.17	0.89–1.53
Nonwhite race	9.9	5.7	10.5	0.81	0.53–1.23
History of					
TIA or stroke	43.3	39.6	34.8	0.78†	0.62–0.99
Hypertension	61.1	57.2	65.2	1.09	0.85–1.39
Diabetes mellitus	24.4	24.0	32.4	1.43†	1.04–1.98
MI or angina	31.4	32.9	36.7	1.12	0.87–1.43
Intermittent claudication	12.6	14.5	15.7	1.08	0.77–1.51
Hyperlipidemia	28.1	36.0	33.8	1.34†	1.03–1.73
Smoking within past year	37.6	42.1	39.5	1.16	0.91–1.50
ICA stenosis < 50%	50.1	55.5	62.4	1.42‡	1.12–1.79
Irregular/ulcerated ICA plaque	48.9	47.0	52.9	1.07	0.85–1.35
Intracranial artery disease	35.5	31.1	36.2	0.96	0.75–1.24
Systolic BP > 160 mm Hg	24.1	19.4	19.5	0.86	0.63–1.17
Diastolic BP > 90 mm Hg	13.7	9.5	10.5	0.76	0.51–1.14
Hematocrit > 0.45 L/L	16.1	16.3	16.2	0.99	0.72–1.36
Glucose > 6.8 mmol/L	29.3	24.7	32.9	0.83	0.61–1.13
Creatinine > 115 μmol/L	20.2	20.5	21.0	1.04	0.76–1.43
Urea nitrogen > 7.5 mmol/L	20.3	23.7	19.5	1.03	0.76–1.39
Cholesterol > 6.5 mmol/L	17.4	20.1	17.6	1.04	0.76–1.42
Triglyceride > 2.6 mmol/L	18.1	16.3	21.0	0.96	0.71–1.32

* Adjusted for all other patient characteristics in the ordinal regression model.

† History of TIA or stroke, $p = 0.038$; diabetes mellitus, $p = 0.029$; hyperlipidemia, $p = 0.027$.

‡ $p = 0.003$.

OR = odds ratio; MI = myocardial infarction; ICA = internal carotid artery; BP = blood pressure.

nonlacunar stroke and a 50 to 99% ICA stenosis, the risk of a subsequent stroke from any cause in the same territory at 3 years was 24.9%, in comparison with 9.7% for the surgically treated patients (figure 4, left bars). This decrease in stroke represented an RRR of 61% in favor of CE (95% CI, 34 to 82%; $p = 0.002$). Patients presenting with a possible lacunar stroke (see figure 4, middle bars) had a lower risk of subsequent stroke, but a similar benefit from CE (RRR, 53%; 95% CI, –62 to 88%; $p = 0.22$). In contrast, the risk of stroke from any cause was reduced by CE to a

lesser extent for patients presenting with probable lacunar stroke (RRR, 35%; 95% CI, –100 to 81%; $p = 0.53$). This risk factor and the outcome analyses were repeated by excluding the 87 patients with only one area affected. The results were virtually indistinguishable from those already reported.

Discussion. This study took advantage of the prospective accumulation of data in 493 patients who had clinical and radiologic evidence suggesting that their hemispheric ischemic events were of lacunar type. Caution must be exercised in making comparisons between the current observations and other reports in the literature. First, patients in the nonlacunar “control” group in this study had overt evidence of large-artery disease and did not consist of the usual normal subjects with whom lacunar syndromes have been compared previously. Second, no patients were accepted into the current study who failed to fulfill the clinical criteria for lacunar syndromes. Unlike other reports appearing in the literature, patients with radiologic findings alone were not considered to have lacunar strokes. Lastly, the definition of a lacunar stroke is an evolving process.

Table 3 Final ordinal regression model

Characteristic	Adjusted OR*	Adjusted 95% CI*	p Value
History of			
TIA or stroke	0.79	0.62–0.99	0.044
Diabetes mellitus	1.37	1.01–1.86	0.049
Hyperlipidemia	1.33	1.05–1.69	0.020
ICA stenosis < 50%	1.41	1.12–1.79	0.003

* Adjusted for all other patient characteristics in the ordinal regression model.

ICA = internal carotid artery.

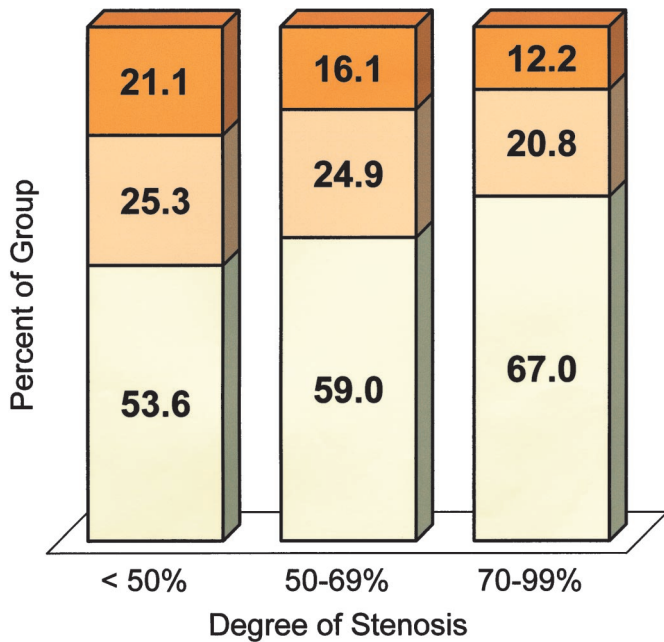


Figure 2. Relationship between category of stroke and degree of internal carotid artery (ICA) stenosis. Lacunar stroke was more likely to occur in patients with milder degrees of ICA stenosis than with severe (70 to 99%) stenosis. Probable lacunar (top)—possible lacunar (middle)—non-lacunar (bottom).

There is uncertainty with regard to considering lacunar strokes that involve clinically one body area alone. In the current study these patients were delineated from the patients with two or more body parts involved. Patients with one body area affected were infrequent, and their inclusion as having lacu-

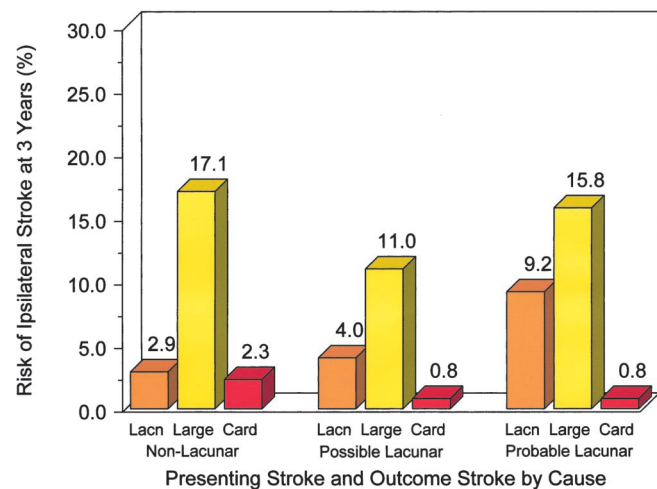


Figure 3. Risk of ipsilateral stroke, by cause, at 3 years for each category of presenting stroke in all medically treated patients. For example, patients presenting with a probable lacunar stroke had a 9.2% risk of a subsequent lacunar stroke (Lacn), a 15.8% risk of a large-artery stroke (Large), and a 0.8% risk of a cardioembolic stroke (Card). The number of patients in the nonlacunar group was 350, in the possible lacunar group was 141, and in the probable lacunar group was 103.

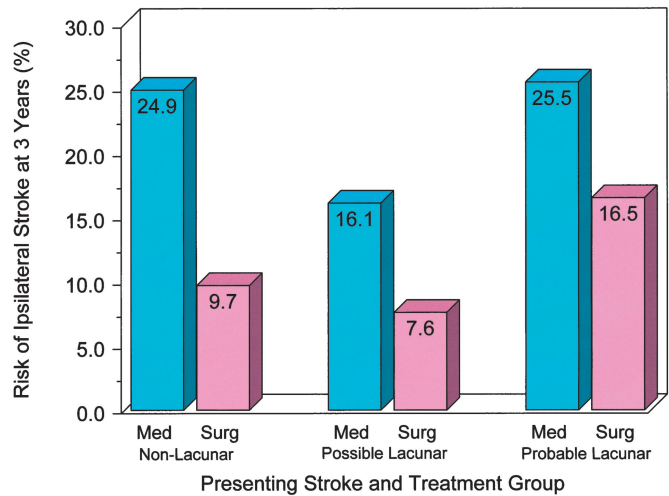


Figure 4. Risk of ipsilateral stroke at 3 years by presenting stroke category and treatment group for patients with 50 to 99% internal carotid artery stenosis. The numbers of patients represented in each bar, from left to right, are 172, 160, 57, 69, 41, and 38. Med = medically treated; Surg = surgically treated.

nar stroke did not alter the results for either the risk factors or the outcomes.

The current study depended, in most patients, on a single CT scan. The timing of the films may have preceded evidence of a visible lesion that later films would have revealed. Only direct visualization of intrinsic disease in the penetrating arteries would be able to confirm their role in producing lacunar stroke. This type of imaging is beyond current capability.

The more conservative definition of the size of a lacune in a CT scan was employed in this study. A maximum diameter of ≤ 1 cm, rather than the 1.5 cm used in most previous clinicoradiologic studies, was chosen to restrict the identification of any lacune to the territory of a single perforating artery. For similar reasons the North Manhattan Stroke cohort,¹⁸ in a large study of lacunar infarctions, utilized the maximum diameter of ≤ 1 cm. Larger lesions may be more likely related to hemodynamic or embolic mechanisms.^{19,20}

A total of 43% of patients in NASCET with hemispheric stroke as the entry event had clinical and radiologic characteristics compatible with lacunar stroke. These patients were more likely to have a lower degree of ICA stenosis, confirming a similar observation reported by the European Carotid Surgery Trial investigators.²¹ This suggests that in some patients the carotid artery lesions may be coincidental to the lacunar symptoms and the result of coexisting, intrinsic small-artery disease. Alternatively it could be speculated that in the presence of stenosing carotid lesions the particles forming emboli are smaller and reach the small penetrating arteries before they lodge. Hemodynamic failure suggested by others⁸ in association with small deep infarcts can-

not be excluded in these patients with severe carotid lesions.

Prior TIA and stroke were less common and the degree of stenosis in the carotid artery was less severe in the patients presenting with lacunar compared with nonlacunar stroke. A history of diabetes and hyperlipidemia were found to be linked more closely to lacunar stroke than was arterial hypertension. Of the two factors considered commonly to be the most important determinants of lacunar infarction—arterial hypertension and diabetes mellitus—only diabetes was associated markedly with lacunar stroke in this study, and it did not interact with hypertension. Diabetes is generally considered related to lacunar infarction by changes in the small blood vessels. The prevalence of hypertension in the overall NASCET population (approximately 60%) was similar to that usually found among stroke patients. The association with hypertension in previous clinical case-control studies has differed according to the selection of control subjects. Studies comparing lacunar with nonlacunar stroke patients generally failed to find important differences in blood pressure or in the prevalence of hypertension.²²⁻²⁶ By contrast, hypertension usually proved to be associated strongly with lacunar stroke when normal subjects were used as control subjects.²⁷

A few studies have observed that the risk profile is different between stroke patients with single and with multiple lacunar lesions. Hypertension,¹⁰ hypertension and diabetes mellitus,²⁸ diabetes alone,²⁹ higher blood pressure values,²⁵ and clinical evidence of systemic hypertensive arteriolar disease³⁰ have been reported to be associated more definitely with multiple lacunar lesions. In the current study, patients with single compared with multiple lacunar lesions did not have different risk profiles, including ICA stenosis and hypertension.

For patients with 50 to 99% ICA stenosis, the largest reduction (61%) in stroke risk by CE was observed in those presenting with a nonlacunar stroke. This was expected because CE is directed toward preventing large-artery strokes. CE was least effective in patients presenting with a probable lacunar stroke, but nevertheless reduced the risk of subsequent stroke by 35%. The magnitude of reduction in stroke risk for patients presenting with a possible lacunar stroke was in between the other two (53%). The smaller reductions observed in the lacunar patients may have been due to the higher incidence of lacunar strokes during follow-up, events for which CE is not expected to prevent. These observations regarding the benefit of CE need to be interpreted cautiously because the sample sizes for the lacunar groups were small, and the corresponding estimates of RRR had wide CIs. Nonetheless, on the balance of the outcome results it appears reasonable to recommend CE for patients presenting with lacunar stroke provided they have 50 to 99% ICA stenosis.

Acknowledgment

The authors acknowledge the support of all participants in NASCET, and SmithKline Beecham for providing Ecotrin for all NASCET patients.

References

1. Fisher CM. Lacunes: small, deep cerebral infarcts. *Neurology* 1965;15:774-784.
2. Fisher CM. Lacunar stroke and infarcts: a review. *Neurology* 1982;32:871-876.
3. Boiten J, Lodder J. Lacunar infarcts. Pathogenesis and validity of the clinical syndromes. *Stroke* 1991;22:1374-1378.
4. Santamaria J, Graus F, Rubio F, Arbizu T, Peres J. Cerebral infarction of the basal ganglia due to embolism from the heart. *Stroke* 1983;14:911-914.
5. Gorsselink EL, Peeters HP, Lodder J. Causes of small deep infarcts detected by CT. *Clin Neurol Neurosurg* 1984;86:271-273.
6. Kappelle LJ, Koudstaal PJ, van Gijn J, Ramos LM, Keunen JE. Carotid angiography in patients with lacunar infarction. A prospective study. *Stroke* 1988;19:1093-1096.
7. Ghika J, Bogousslavsky J, Regli F. Infarcts in the territory of the deep perforators from the carotid system. *Neurology* 1989;39:507-512.
8. Waterston JA, Brown MM, Butler P, Swash M. Small deep cerebral infarcts associated with occlusive internal carotid artery disease. A hemodynamic phenomenon? *Arch Neurol* 1990;47:953-957.
9. Bamford JM, Warlow CP. Evolution and testing of the lacunar hypothesis. *Stroke* 1988;19:1074-1082.
10. Boiten J, Lodder J, Kessels F. Two clinically distinct lacunar infarct entities? A hypothesis. *Stroke* 1993;24:652-656.
11. Boiten J, Rothwell PM, Slattery J, Warlow CP for the European Carotid Surgery Trialists' Collaborative Group. Frequency and degree of carotid stenosis in small centrum ovale infarcts as compared to lacunar infarcts. *Cerebrovasc Dis* 1997;7:138-143.
12. North American Symptomatic Carotid Endarterectomy Trial (NASCET) Steering Committee. North American Symptomatic Carotid Endarterectomy Trial. Methods, patient characteristics, and progress. *Stroke* 1991;22:711-720.
13. Fox AJ. How to measure carotid stenosis. *Radiology* 1993;186:316-318.
14. Bamford JM. Lacunar syndromes—are they still worth diagnosing? In: Donnan GA, Norrving B, Bamford JM, Bogousslavsky J, eds. *Lacunar and other subcortical infarctions*. Oxford: Oxford University Press, 1995:32-43.
15. Bladin CF, Chambers BR. Clinical features, pathogenesis and computed tomographic characteristics of internal watershed infarction. *Stroke* 1993;24:1925-1932.
16. Barnett HJM, et al. The causes and severity of ischemic stroke in patients with internal carotid artery stenosis. *JAMA* 2000 (in press).
17. Barnett HJM, Taylor DW, Eliasziw M, et al. Benefit of carotid endarterectomy in symptomatic patients with moderate and severe stenosis. *N Engl J Med* 1998;339:1415-1425.
18. Gan R, Sacco RL, Kargman DE, Roberts JK, Boden-Albala B, Gu Q. Testing the validity of the lacunar hypothesis: the Northern Manhattan Stroke Study experience. *Neurology* 1997;48:1204-1211.
19. Miller VT. Lacunar stroke. A reassessment. *Arch Neurol* 1983;40:129-134.
20. Lammie GA, Wardlaw JM. Small centrum ovale infarcts—a pathological study. *Cerebrovasc Dis* 1999;9:82-90.
21. Boiten J, Rothwell PM, Slattery J, Warlow CP, for the European Carotid Surgery Trialists' Collaborative Group. Ischaemic lacunar stroke in the European Carotid Surgery Trial: risk factors, distribution of carotid stenosis, effect of surgery and type of recurrent stroke. *Cerebrovasc Dis* 1996;6:281-287.
22. van Gijn J, Kraaijeveld CL. Blood pressure does not predict lacunar infarction. *J Neurol Neurosurg Psychiatry* 1982;45:147-150.

23. Landi G, Cella E, Boccardi E, Musicco M. Lacunar versus nonlacunar infarcts: pathogenetic and prognostic differences. *J Neurol Neurosurg Psychiatry* 1992;55:441-445.
24. Lodder J, Bamford JM, Sandercock PA, Jones LN, Warlow CP. Are hypertension or cardiac embolism likely causes of lacunar infarction? *Stroke* 1990;21:375-381.
25. Chamorro A, Saiz A, Vila N, et al. Contribution of arterial blood pressure to the clinical expression of lacunar infarction. *Stroke* 1996;27:388-392.
26. Boiten J, Luijckx GJ, Kessels F, Lodder J. Risk factors for lacunes. *Neurology* 1996;47:1109-1110.
27. You R, McNeil JJ, O'Malley HM, Davis SM, Donnan GA. Risk factors for lacunar infarction syndromes. *Neurology* 1995;45:1483-1487.
28. Mast H, Thompson JL, Lee SH, Mohr JP, Sacco RL. Hypertension and diabetes mellitus as determinants of multiple lacunar infarcts. *Stroke* 1995;26:30-33.
29. Mochizuki Y, Oishi M, Takasu T. Cerebral blood flow in single and multiple lacunar infarctions. *Stroke* 1997;28:1458-1460.
30. Spolveri S, Baruffi MC, Cappelletti C, et al. Vascular risk factors linked to multiple lacunar infarcts. *Cerebrovasc Dis* 1998;8:152-157.

rtPA intravenous thrombolysis in anterior choroidal artery territory stroke

P. Trouillas, MD, PhD; L. Derex, MD; N. Nighoghossian, MD; J. Honnorat, MD; W. Li, MD;
P. Neuschwander, MD; G. Riche, MD; J.C. Getenet, MD; Y. Berthezene, MD; F. Turjman, MD;
and J.C. Froment, MD

Article abstract—*Objective:* To study the possible specific response to recombinant tissue plasminogen activator (rtPA) thrombolysis of anterior choroidal artery (AChA) stroke. *Background:* Outcome and response after rtPA thrombolysis are possibly better in small-vessel infarcts, but a specific study of AChA stroke has not yet been performed. *Methods:* The authors proposed an open trial of IV rtPA within 7 hours in patients age 20 and 81 years with all types of internal carotid artery territory stroke if the baseline Scandinavian Stroke Scale (SSS) score was less than 48. A dose of rtPA 0.8 mg/kg was infused over 90 minutes. Of 114 consecutive patients, 9 patients (7.9%) exhibited hypodensity in the AChA territory on day 1 brain CT. *Results:* Seven of nine patients with AChA infarct had a primary early recovery within 6 hours after the initiation of rtPA infusion. In addition, recovery was complete in five patients and partial in two patients. No intracerebral hematoma was observed. Three patients had a “reinfarct syndrome” at 12, 25, and 48 hours respectively. However, in the two latter patients treated with IV heparin, the deficit disappeared again with the increase of heparin dose in one patient and disappeared spontaneously in the other patient. The overall outcome at day 90 was six total recoveries in nine patients (66%). Patients with a final good outcome had a slight “unstructured” hypodensity in the AChA territory on day 1 brain CT, whereas patients with a bad outcome had the classic “structured” hypodensity of AChA territory stroke. *Conclusion:* These data support a specific quick response of AChA territory stroke to IV rtPA thrombolysis, probably due to the small size of the artery and of the “clot.” The high frequency of the reinfarct syndrome is a clinical fact that is difficult to explain. Efficient heparin treatment after 24 hours may control the reinfarct syndrome in some patients. **Key words:** Recombinant tissue plasminogen activator—Intravenous—Choroidal artery—Reinfarct.

NEUROLOGY 2000;54:666-673

Open or small double-blind studies with intra-arterial or IV administration of a thrombolytic agent in acute stroke patients either in the internal carotid artery (ICA) territory or in the vertebrobasilar territory have shown that both recanalization of the occluded artery and regression of the neurologic deficit might be observed.¹⁻¹⁴ Large double-blind studies have established that IV streptokinase is inefficient and dangerous for ischemic stroke.¹⁵⁻¹⁷ Conversely,

IV recombinant tissue plasminogen activator (rtPA) is effective and safe when administered at a dose of 0.9 mg/kg within 3 hours.¹⁸ Despite the increased risk of intracranial hemorrhage, thrombolysis with rtPA within 6 hours may lead to an improvement in outcome in a target population at a dose of 1.1 mg/kg¹⁹ and in selected patients at a dose of 0.9 mg/kg.²⁰ Besides the large controlled studies, small open studies with accurate clinical observation of the patients

From the Cerebrovascular Unit and Ataxia Research Center (Drs. Trouillas, Derex, Nighoghossian, Honnorat, Riche, Neuschwander, Getenet, and Li) and the Department of Neuroradiology (Drs. Berthezene, Turjman, and Froment), Hôpital Neurologique, Lyon, France.

Study funded by ARNEL.

Received December 7, 1998. Accepted in final form September 24, 1999.

Address correspondence and reprint requests to Dr. Paul Trouillas, Unité Cérébrovasculaire et Centre de Recherches sur l'Ataxie, Hôpital Neurologique, 59 Boulevard Pinel, 69003 Lyon, France.

and careful definition of the arteries involved may provide additional information regarding the specific sensitivity of subgroups of patients. In our series of 114 consecutive patients with ICA territory stroke treated with IV rtPA thrombolysis, whose 43 and 100 first patients have been already published,^{21,22} we have observed particularities in the outcome of nine patients with anterior choroidal artery territory stroke. We present these patients with a special reference to the quick recovery after the initiation of IV rtPA and the “reinfarct syndrome.”

Methods. *Patients, inclusion criteria, and clinical assessment.* Beginning January 1, 1994, we proposed an open protocol of IV rtPA to all the patients presenting with symptoms of acute ICA territory stroke and meeting specific criteria²²: 1) informed consent received from each patient or their relatives, 2) patient age between 20 and 81 years, 3) onset of symptoms within 7 hours before the initiation of therapy, 4) absence of hemorrhage on baseline brain CT, 5) clinical presentation consistent with the occlusion of an ICA (middle cerebral artery [MCA; trunk or branch], anterior cerebral artery [ACA], and anterior choroidal artery [AChA]), 6) permanent or ingravescent symptomatology since the onset of stroke, and 7) baseline Scandinavian Stroke Scale (SSS) score less than 48. The inclusion criteria did not involve a limitation of clinical severity levels or radiologic hypodensities on the initial brain CT scan. The exclusion criteria were intracranial hemorrhage; systolic blood pressure > 190 mm Hg; hemodynamic shock; possible pregnancy; critical cardiac, pulmonary, renal, or hepatic condition; and classic contraindications to thrombolysis (recent surgical operation, recent history of gastrointestinal bleeding, and known coagulopathies).

Treatments. Alteplase (predominantly single-chain rtPA; Boehringer Ingelheim, Germany) was used. rtPA infusion was administered immediately after baseline brain CT at a dose of 0.8 mg/kg over 90 minutes at a constant infusion rate with an initial bolus of 10%—a procedure worked out in our institution before the results of the National Institute of Neurological Disorders and Stroke. Heparin was administered according to three protocols described previously.²² In patients with a severe clinical presentation, a complementary treatment of Mannitol was administered.^{21,22} All patients were treated and monitored in an intensive neurologic care unit for a week. Patients with a clinical or echocardiographically detected major cardiac source of emboli underwent oral antivitamin K anticoagulant therapy after heparin, with internal normalized ratio (INR) between 2 and 3, except in patients in whom this treatment was contraindicated.

Outcome assessment. SSS assessment was performed on days 1 (24 ± 6 hours), 7, 30, and 90. This neurologic grading scale (ranging from 2 to 58) is used commonly in acute carotid artery territory stroke trials and it assesses level of consciousness, orientation, motor function, and language.²³ The clinical regression of neurologic symptoms within 3 hours after the beginning of thrombolysis was documented. A recovery with an SSS score of 48 was considered to be a major neurologic improvement and defines “rapid regressors.” The same recovery at 24 hours defines “day 1 major neurologic improvement.” Reinfarct syn-

drome was defined on the basis of a complete regression of the motor or aphasic deficit followed by the recurrence of the neurologic deficit in the same territory within 48 hours after onset, without CT evidence of hemorrhagic transformation. Outcome at day 90 and 1 year was assessed according to a modified Rankin scale—a classic 0-to-6 evaluation of neurologic handicap in ischemic stroke trials,²⁴ in which complete recovery corresponds to scores 0 and 1. Intracerebral parenchymatous hematomas were defined according to Pessin.²⁵

Radiologic assessment. Brain CT scans were obtained before treatment, at 24 ± 6 hours, and on day 7, and were reviewed without knowledge of treatment assignment and clinical data. The images observed at days 1 and 7 were studied in terms of morphology, particularly assessing the “structured” or “unstructured” aspect of the hypodensity.²² The topography of the images was studied according to the CT templates of Damasio²⁶ for vascular territories of MCA and ACA, and that of Hupperts et al.²⁷ for the AChA territory.

Etiologic data. All early survivors underwent neck ultrasound and echocardiography, either transthoracic (TTE) or transesophageal (TEE). All patients with AChA stroke had TEE.

Results. *Patient reports.* By January 30, 1997, 114 consecutive patients had been studied. Of these, nine patients (7.9%) exhibited hypodensity in the posterior two-thirds of the posterior leg of the internal capsule on the day 1 brain CT scan, which is compatible with the diagnosis of an ischemic event in the AChA territory. These patients are reported here. The three patients with moderate or poor prognosis are reported first, followed by a discussion of the six patients who experienced total recovery. A secondary evaluation of the visual field was performed by Goldman campimetry.

Patient 1. This 63-year-old right-handed man presented with sudden right hemiplegia and some speech difficulties (figure 1A). On admission, the hemiplegia was severe, with total paralysis of the inferior and superior limbs without facial palsy. A right Babinski’s sign was found. The patient had a slight expression aphasia. The baseline SSS score was 28. IV rtPA thrombolysis was initiated 300 minutes after the onset of symptoms. The SSS score was 29 at 24 hours. Efficient IV heparin was administered at the 24th hour. Neck ultrasonography showed bilateral ICA stenosis. The patient was discharged under oral anticoagulant therapy. The SSS score was 40 at day 30 and 43 at day 90. The day 90 modified Rankin Scale score was 3.

Patient 2. This 67-year-old right-handed man with a past history of hypercholesterolemia presented with sudden right hemiplegia and aphasia (figure 1B). On admission, clinical examination showed dense hemiplegia involving the face, associated with partial sensory loss and a nonfluent aphasia. The baseline SSS score was 22. Brain CT showed a remote left insular infarct. IV rtPA thrombolysis was initiated 210 minutes after the onset of symptoms. On day 1 the patient remained hemiplegic and his SSS score was 22. Efficient IV heparin was started on day 1. On day 7, the deficit of the lower limb had resolved partially, whereas the aphasia and upper limb sensory-motor deficit persisted. Day 7 brain CT showed a structured hypodensity in the retrolenticular part of the left

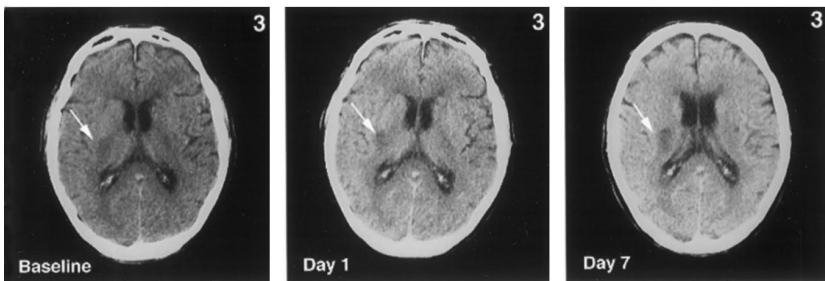
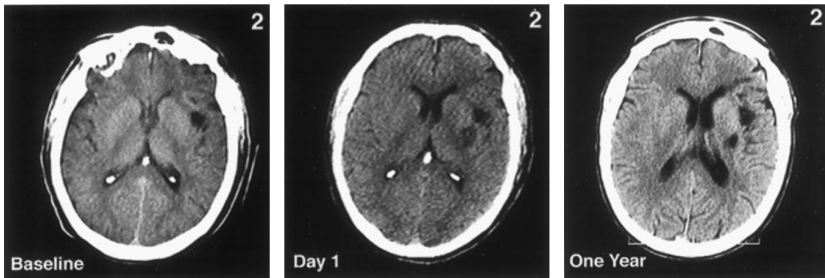
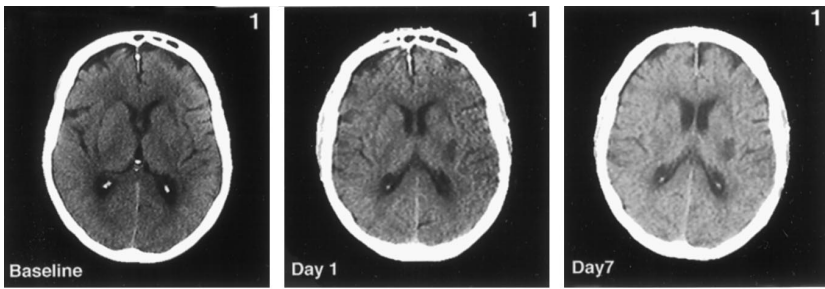


Figure 1. Patients 1 through 3. Brain CT scans of patients with anterior choroidal artery (AChA) stroke experiencing a primary or secondary unfavorable evolution. In all three patients, the hypodense area on the day 1 brain CT scan is well defined, dark, and corresponds to the “definite” AChA territory. The hypodense area remains unchanged (Patient 1) or becomes darker and larger (Patient 3) on day 7 brain CT. In Patient 2 (day 7 brain CT unavailable), a remote left insular infarct was observed and the ischemic lesion persisted at 1 year. A, first column; B, second column; C, third column.

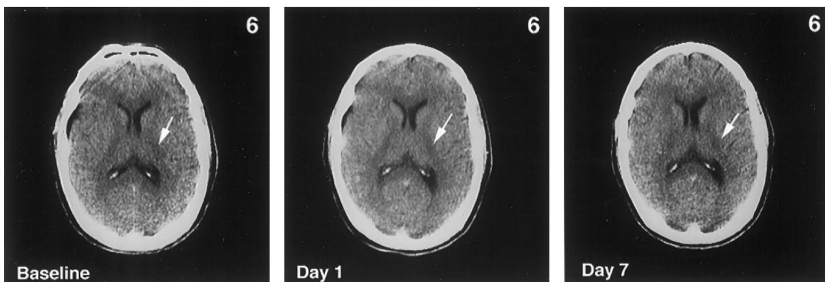
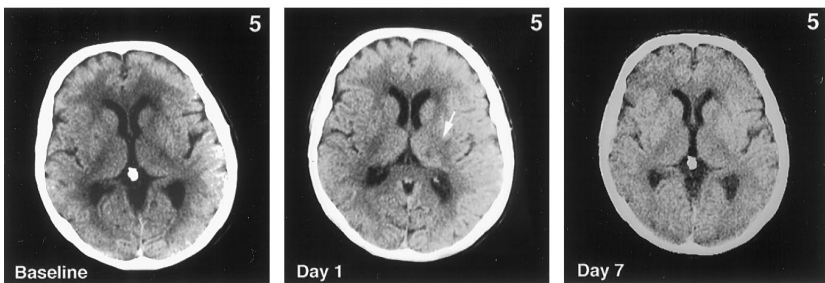
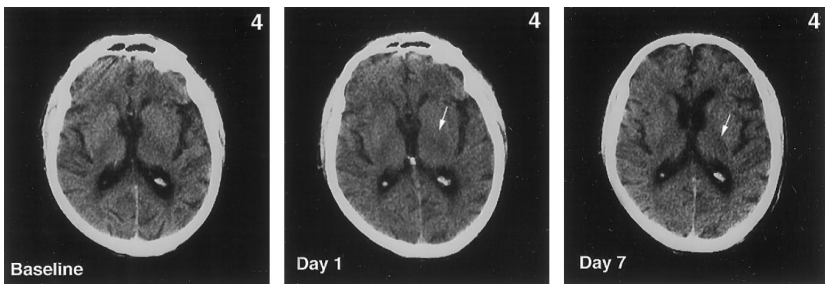


Figure 2. Patients 4 through 6. Brain CT scans of patients with anterior choroidal artery stroke showing a primary or secondary favorable evolution. The day 1 brain CT scan shows poorly limited and slight hypodensities (“unstructured”) in Patients 4 and 5, and slight abnormalities in Patient 6. On the day 7 brain CT scan, only a faint hypodense area is observed in Patients 4 and 6. A, first column; B, second column; C, third column.

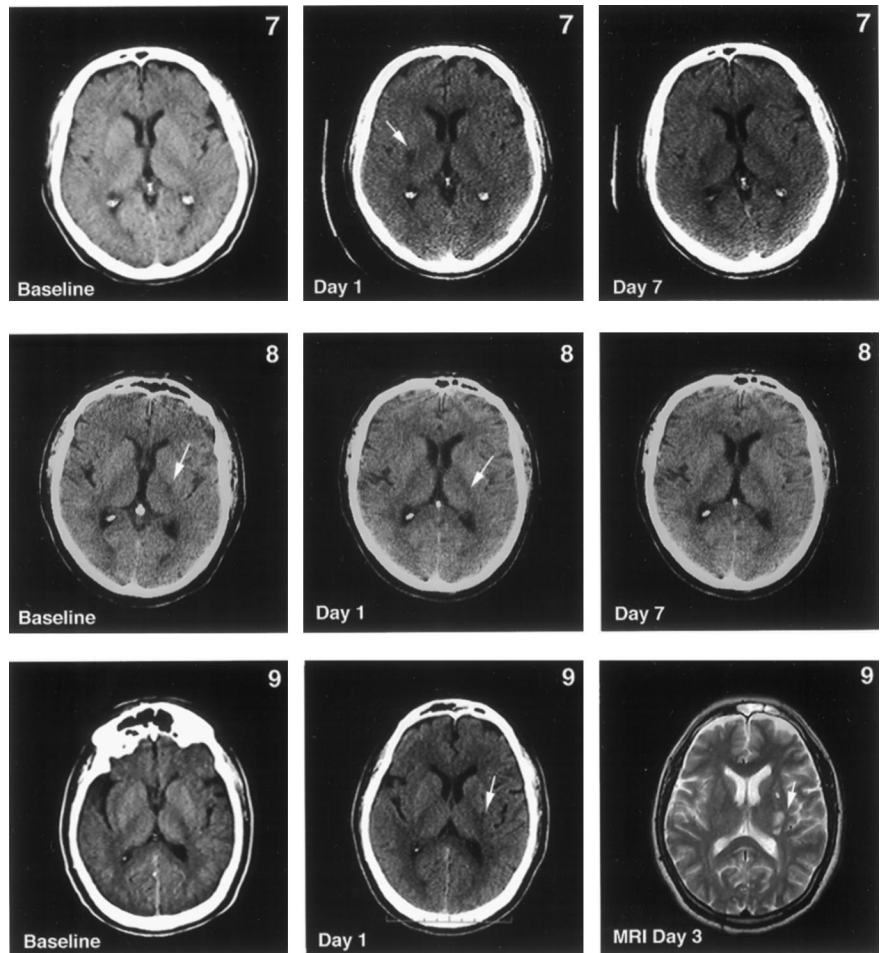


Figure 3. Patients 7 through 9. Brain CT scans of patients with anterior choroïdal artery stroke showing a primary or secondary favorable evolution (continued). The day 1 brain CT scan shows a clear, hypodense area in Patient 7, and shows slight abnormalities in Patients 8 and 9. The day 7 brain CT scan shows slight hypodensity in Patient 7. In Patient 9, T2-weighted MRI on day 3 showed a slight fragmented hyperintensity. A, first column; B, second column; C, third column.

internal capsule. The etiologic workup was negative. The day 90 modified Rankin Scale score was 5.

Patient 3. This 68-year-old right-handed man with a past medical history of hypertension and angor pectoris presented with a fluctuating left hemiplegia involving the face (figure 1C). On admission, complete left anesthesia to pinprick and tactile stimuli was observed. The baseline SSS score was 26. IV rtPA thrombolysis was initiated 290 minutes after the onset of symptoms. At the 3-hour examination, the deficit had regressed considerably. The patient was able to raise his left arm and leg. The sensory deficit had cleared. His SSS score was 45. No heparin was administered. During the following hours, the deficit resolved completely. Twelve hours after the initiation of thrombolysis, the patient had a recurrence of left hemiplegia, with central facial palsy and dysarthria. His SSS score was 26. Day 1 brain CT showed hypodensity in the retrolenticular part of the right internal capsule. Efficient IV heparin was started at the 24th hour. The patient remained hemiplegic on day 7. Cerebral angiography showed a mild right proximal ICA stenosis and a stenosis of the carotid siphons. The patient was assigned oral antivitamin K therapy. The SSS score was 32 on day 30 and 39 on day 90. The day 90 modified Rankin Scale score was 5.

Patient 4. This 81-year-old man, not strictly right-handed, with a history of hypertension and hypercholesterolemia, developed a sudden right hemiplegia involving the face (figure 2A). On admission, the upper limb was plegic whereas the leg could be raised with flexion of the knee. A

slight right hypoesthesia to tactile stimuli was observed. The baseline SSS score was 32. IV rtPA thrombolysis was initiated 240 minutes after the onset of symptoms. By the end of thrombolysis, recovery was observed, and the patient had recovered completely at 2 hours. Immediate IV heparin was administered. The patient had a recurrence of right hemiplegia at the 25th hour. Results of the activated partial thromboplastin time (aPTT) value were released and showed that the heparin therapy was underdosed. The pace of the continuous heparin infusion was raised. Thirty minutes later, the deficits had cleared. The day 1 SSS score was 58. Day 1 brain CT showed slight, unstructured hypodensity in the retrolenticular part of the left internal capsule. The patient's etiologic workup was negative. The patient was discharged under ticlopidine. The day 90 modified Rankin Scale score was 0. At 1 year the patient was asymptomatic.

Patient 5. This 56-year-old right-handed hypertensive man presented with a progressive right hemiplegia involving the face (figure 2B). The baseline SSS score was 22. rtPA IV thrombolysis was initiated 240 minutes after the onset of symptoms. At 1 hour, the deficit had cleared. His day 1 SSS score was 58. Efficient IV heparin was administered at the 24th hour. Day 1 CT showed polycyclic hypodensity in the retrolenticular part of the internal capsule. At the 48th hour, a recurrence of the same deficit was observed under heparin, but cleared spontaneously 1 hour later. The patient's etiologic workup showed a mild left ICA stenosis. The patient was discharged under ticlopi-

Table 1 Thrombolysis of anterior choroidal artery territory infarcts: etiologic and clinical data

Cases	CVRF	Age	Sex	Symptomatology	Baseline Scandinavian Stroke Scale	Interval (mn)	Primary recovery	Onset of primary recovery after initiation of thrombolysis (minutes)	Cause
1	None	63	M	Right hemiplegia, Slight aphasia	28	300	None	—	ICA stenosis >70%
2	Hypercholesterolemia	67	M	Right hemiplegia, Aphasia	22	210	None	—	Undetermined
3	Hypertension	68	M	Left hemiplegia, Fluctuating	26	290	Almost complete	180	Proximal and distal ICA atheroma
4	Hypertension, hypercholesterolemia	81	M	Right hemiplegia, No aphasia	32	240	Complete	120	Undetermined
5	Hypertension	56	M	Right hemiplegia, no aphasia, progressive	22	240	Complete	60	Left ICA atheromatous plaque
6	Diabetes, Hypercholesterolemia	48	M	Right hemiplegia, slight aphasia, fluctuating	22	140	Complete	10	Atrial septal aneurysm
7	Dyslipidemia	53	M	Left hemiplegia, progressive	26	180	Almost complete	60	Atrial septal aneurysm
8	Hypertension, Hypercholesterolemia	62	M	Right hemiplegia, no aphasia, progressive	28	345	Complete	60	Myocardial akinesia
9	Diabetes, Hypercholesterolemia	51	M	Right hemiplegia, no aphasia	30	410	Complete	15	PFO, myocardial hypokinesia, aortic arch atheroma

dine. On day 90 the patient had resumed his work as a chimney cleaner. The day 90 modified Rankin Scale score was 0.

Patient 6. This 48-year-old right-handed man with a past medical history of diabetes mellitus and hypercholesterolemia presented with fluctuating right hemiplegia (figure 2C). On admission he was hemiparetic and dysarthric. Mild hypoesthesia was noted in the right lower limb. The baseline SSS score was 22. IV rtPA thrombolysis was initiated 140 minutes after the onset of symptoms. The deficit had cleared by the end of the rtPA infusion. Immediate IV heparin was administered. His day 1 SSS score was 58. Day 1 brain CT showed slight, unstructured hypodensity in the posterior two-thirds of the internal capsule. The patient's etiologic workup disclosed a large atrial septal aneurysm. The patient was discharged under oral antivitamin K therapy. The day 90 modified Rankin Scale score was 0. The patient was asymptomatic at 1 year.

Patient 7. This right-handed 53-year-old man with a past medical history of hypercholesterolemia presented with progressive left hemiplegia (figure 3A). On admission, left pinprick hypoesthesia was observed. The baseline SSS score was 26. IV rtPA thrombolysis was initiated 180 minutes after the onset of symptoms. A major neurologic improvement was observed by the end of thrombolysis. His SSS score at that time was 48. On day 1 the patient was able to walk. Slight pinprick hypoesthesia of the left arm persisted. Day 1 brain CT showed hypodensity in the retrolenticular part of the right internal capsule. Efficient IV heparin was administered on day 1. On day 7 his SSS score was 58. TEE disclosed an atrial septal aneurysm. Neck ultrasound was normal. The patient was dis-

charged under ticlopidine on day 9. The day 90 modified Rankin Scale score was 0. The SSS score was 58 at 1 year.

Patient 8. This 62-year-old right-handed man had a previous medical history of hypercholesterolemia, hypertension, and coronary disease (figure 3B). He had progressive right hemiplegia excluding the face. The baseline SSS score was 28. rtPA IV thrombolysis was initiated 345 minutes after the onset of symptoms. Regression of the deficit was observed 15 minutes after initiation of thrombolysis for the leg and 15 minutes later for the arm. A relapse of right hemiplegia occurred 30 minutes later and lasted 15 minutes. However, the patient was asymptomatic again 1 hour later. Immediate, efficient IV heparin was administered. Day 1 brain CT showed slight hypodensity in the left AChA territory. His SSS score was 58 on days 1 and 7. Neck ultrasound was normal. TEE showed myocardial inferobasal akinesia. The patient was assigned oral antivitamin K therapy. The day 90 modified Rankin Scale score was 0. He was asymptomatic at 1 year.

Patient 9. This 51-year-old right-handed smoker had a past medical history of diabetes mellitus and hypercholesterolemia (figure 3C). He presented with sudden right hemiplegia excluding the face. On admission the patient was hemiparetic. Brain CT revealed slight left retrolenticular hypodensity. The baseline SSS score was 30. IV rtPA thrombolysis was initiated 410 minutes after the onset of symptoms. The motor deficit cleared over 15 minutes. His SSS score was 58 on day 1. Day 1 brain CT showed slight left unstructured retrolenticular hypodensity extending upward to the posterior paraventricular part of the corona radiata. Efficient IV heparin was started on day 1. Neck ultrasound was normal. TEE showed myocardial apical

Table 2 Thrombolysis of anterior choroidal artery territory infarcts: thrombolytic procedures and postthrombolysis course

Cases	Immediate heparin	Delayed heparin (24 h)	Quick recovery (<3 h)	“Reinfarct syndrome”	Time of “reinfarct syndrome” (h)	Recovery of “reinfarct syndrome”	Antivitamin K until day 90	Total recovery at day 90
1	0	+	0	0	—	—	+	0
2	0	+	0	0	—	—	0	0
3	0	+	+	+	12	0	+	0
4	+	0	+	+	25	+	0	+
5	0	+	+	+	48	+	0	+
6	+	0	+	0	—	—	+	+
7	0	+	+	0	—	—	0	+
8	+	0	+	0	—	—	+	+
9	0	+	+	0	—	—	0	+

hypokinesia, a patent foramen ovale with a right/left shunt, and aortic arch atheroma. The day 90 modified Rankin Scale score was 0. The patient was asymptomatic at year 1.

Summary of the data. A summary of data concerning clinical presentation, interval of treatments, time of reinfarct, early aspects of the response to thrombolysis, and outcome parameters is presented in tables 1 and 2.

Discussion. *Baseline clinical presentation.* Nine patients (7.9%) in a series of 114 consecutive patients with ischemic stroke in the ICA territory exhibited hypodensity in the posterior two-thirds of the posterior leg of the internal capsule on day 1 brain CT—consistent with AChA territory ischemia. This series of AChA strokes is the first described within 7 hours after onset. The frequency of this localization among hemispheric stroke is close to that observed by Hupperts et al. (10.5%),²⁷ but higher than that of the Lausanne registry.²⁸

Eight of nine patients had a baseline clinical presentation involving hemiplegia with an equal deficit in the affected two limbs and in the different segments of the affected limb (“homogenous” deficit). A striking contrast was noted between the heaviness of the paralysis and the complete conservation of consciousness and eye movements. Another relevant characteristic was the paradoxical lack of aphasia in right-handed patients with a heavy right-side hemiplegia due to a left-side stroke (four of seven patients). A fluctuating aspect of the hemiplegia was noted in two patients. A pure motor deficit was observed in four of nine patients (44.4%).

No patient had the classic presentation with hemiplegia, hemianesthesia, and hemianopia, as in the original description,²⁹ and no patient had hemianopia. Another classic presentation of AChA stroke, ataxia,^{27,30,31} was not observed. Despite the limited number of patients in our series, these data may indicate that the hyperearly symptomatology of this type of infarct is different from the late clinical aspects hitherto described,²⁷⁻³⁸ suggesting that the lat-

ter may need time to develop and correspond to deeper or larger ischemic injuries.

Specific good outcome rate. The natural outcome of AChA stroke observed within 7 hours after the onset of symptoms is not known. However, spontaneous, early spectacular regression of AChA stroke has not been documented.²⁷ Conversely, in this series, seven of nine patients had an excellent and quick neurologic improvement in response to IV rtPA thrombolysis at a dose of 0.8 mg/kg administered over 90 minutes: complete recovery in five patients and near-complete recovery in two patients. The response took place during thrombolytic infusion or by the end of thrombolysis in five patients, providing an unexpected clinical situation.

On day 90, the outcome included six complete recoveries (66%) (modified Rankin Scale score, 0), one moderate outcome (modified Rankin Scale score, 3), and two poor outcomes (modified Rankin Scale score, 5). In our series of 100 patients,²² the overall good result rate was 45%, whereas univariate statistical analysis disclosed that stroke of small-size vessels, including AChA, had a better outcome than those of large-size vessels. These results are in keeping with those of the National Institute of Neurological Disorders and Stroke double-blind study, which demonstrated that stroke affecting “small vessels” had higher rates of good outcome and response after IV rtPA of 0.9 mg/kg—a dose close to ours.¹⁸ AChA strokes might have been included in this subgroup because they are considered small-vessel strokes.^{27,33} However, according to the etiologic data of our series (see table 2), the AChA “clot” may have an embolic origin in some patients, either of cardiac or carotid origin. The intrinsic small-vessel disease is questionable in our series, as in another series.³⁵

The quick response of AChA territory strokes to IV rtPA thrombolysis can be interpreted as rapid recanalization after the initiation of thrombolysis. This therapeutic, dramatic effect might be due precisely to the small size of the “clot” compared with

the concentration of circulating rtPA—a fact that is well established in experimental thrombolysis.^{39,40}

No patient showed either hemorrhagic petechial transformation or parenchymal hematoma, despite anticoagulant therapies.

Reinfarct syndrome. We observed a reinfarct syndrome in three patients (33%) that took place in one patient within 24 hours (12th hour) and in two patients after 24 hours (25th hour and 48th hour). The frequency of the reinfarct syndrome was 3% in our study of rtPA thrombolysis, and is observed in AChA stroke (2%) and the deep lenticulostriate branch of the MCA (1%).²² Thus, the reinfarct syndrome seems to be related specifically to AChA stroke and other small-vessel strokes. The interpretation of the reinfarct syndrome and of its high frequency in AChA stroke is difficult. The cause of the reinfarct syndrome remains speculative. Reperfusion injury could take place and explain the occurrence of relapse in some patients. Recurrence or extension of thrombosis appears to be an alternative explanation. The rethrombosis may be of local origin, due to the recurrence of the clot at the same small-vessel level, or it may be due to embolism. In two of three patients with reinfarct syndrome, AChA stroke was associated with a potential atheromatous origin at the proximal ICA level—a fact that does not favor the “local” origin hypothesis.

From a therapeutic point of view, the two patients who experienced a reinfarct syndrome after 24 hours were under heparin administration and they recovered, one spontaneously and the other one with an increase in the dose of the infused heparin. Immediate heparinization after thrombolysis is not, however, advised because of its potential hazards. We have shown that protocols of heparin given immediately after IV rtPA thrombolysis are related to the increase of the occurrence of intracerebral hematomas.²² Conversely, heparinization at 24 hours, after checking the 24-hour CT scan, is a reasonable approach to cover this reinfarct syndrome risk 24 hours after IV rtPA thrombolysis.

Radiologic data. The three patients who did not experience total recovery, either after a primary AChA stroke (Patients 1 and 2) or after a reinfarct syndrome (Patient 3) had classic “structured” hypodensities in the retrolenticular part of the internal capsule on days 1 and 7 brain CT (figure 1, A through C). The six patients with complete recovery, either primary (Patients 6 through 9) or secondary after relapse (Patients 4 and 5), exhibited slight hypodensities in the AChA territory on day 1 brain CT, with blurred limits and faint darkness, which we call “unstructured” hypodensities.^{21,22} On day 7 brain CT in these six patients, the hypodense area was small and lacked the characteristics of the classic AChA territory infarct. In two patients it had nearly disappeared. Hyperperfusion is known to be the main phenomenon following recanalization in occlusion–reperfusion paradigms.^{41,42} We hypothesize that these “unstructured” hypodensities, like those of the

MCA territory, are not classic ischemic hypodensities, but are hyperperfusion images secondary to reperfusion with lower degrees of ischemia.²² In one patient who underwent early MRI, T2-weighted images showed fragmented images (see figure 3C), compatible with hyperperfused areas.

Practical consequences and conclusion. In our experience, quick and considerable clinical recovery after the initiation of IV rtPA thrombolysis is consistent with AChA territory stroke, and could represent a diagnostic indication. Given the persisting risk of reinfarct syndrome after 24 hours in this subset of patients, we firmly advise the use of IV efficient heparin in AChA rtPA-treated strokes at 24 hours, after day 1 brain CT has ruled out hemorrhagic transformation.

Acknowledgment

The authors thank Monique Billaud and Serge Balter for their excellent technical assistance in the preparation of the figures.

References

1. Zeumer H, Freitag HJ, Brzyska U, Nunzig HP. Local intra-arterial fibrinolysis in acute vertebrobasilar occlusion. Technical developments and recent results. *Neuroradiology* 1989;3:336–340.
2. Zeumer H. Vascular recanalizing techniques in interventional neuroradiology. *J Neurol* 1985;231:287–294.
3. Maisa D, Theron J, Pelouze GA, et al. Local fibrinolytic therapy in ischemic carotid pathology. *Ann Vasc Surg* 1988;2:205–214.
4. Del Zoppo GJ, Ferbert A, Otis S, et al. Local intra-arterial fibrinolytic therapy in acute carotid territory stroke. A pilot study. *Stroke* 1988;19:307–313.
5. Hacke W, Zeumer H, Ferbert A, Bruckmann H, Del Zoppo GJ. Intra-arterial thrombolytic therapy improves outcome in patients with acute vertebrobasilar occlusive disease. *Stroke* 1988;19:1216–1222.
6. Theron J, Courtheoux P, Cascasco A, et al. Local intra-arterial fibrinolysis in the carotid territory. *Am J Neuroradiol* 1989;10:753–765.
7. Mori E, Tabuchi M, Yoshida T, Yamadori A. Intracarotid urokinase with thromboembolic occlusion of the middle cerebral artery. *Stroke* 1988;19:802–812.
8. Möbius E, Berg-Dammer E, Kuhne D, Nahser HC. Local thrombolytic therapy in acute basilar artery occlusion. Experience with 18 patients. In: Hacke W, del Zoppo GJ, Hirschberg M, eds. *Thrombolytic therapy in acute ischemic stroke*. New York: Springer-Verlag, 1991:213–215.
9. Von Kummer R, Hacke W. Safety and efficacy of intravenous tissue plasminogen activator and heparin in acute middle cerebral artery stroke. *Stroke* 1992;23:646–652.
10. Brott TG, Haley EC, Levy DE, et al. Urgent therapy for stroke: pilot study for tissue plasminogen activator administered within 90 minutes. *Stroke* 1992;23:632–640.
11. Haley EC, Levy DE, Brott TG, et al. Urgent therapy for stroke: pilot study of tissue plasminogen activator administered 91–180 minutes from onset. *Stroke* 1992;23:641–645.
12. del Zoppo GJ, Poeck K, Pessin MS, et al. Recombinant tissue plasminogen activator in acute thrombotic and embolic stroke. *Ann Neurol* 1992;32:78–86.
13. Mori E, Yoneda Y, Tabuchi M, et al. Intravenous recombinant tissue plasminogen activator in acute carotid artery territory stroke. *Neurology* 1992;42:976–982.
14. Haley EC, Brott TG, Sheppard GL, et al. Pilot randomized trial of tissue plasminogen activator in ischemic stroke. *Stroke* 1993;24:1000–1004.
15. Multicentre Acute Stroke Trial–Italy (MAST-I) Group. Randomised controlled trial of streptokinase, aspirin, and combination of both in treatment of acute ischemic stroke. *Lancet* 1995;346:1509–1514.
16. Donnan GA, Davis SM, Chambers BR, et al. Trials of strep-

- tokinase in severe acute ischaemic stroke. *Lancet* 1995;345:578–579.
17. The Multicenter Acute Stroke Trial–Europe Study Group. Thrombolytic therapy with streptokinase in acute ischemic stroke. *N Engl J Med* 1996;335:145–150.
 18. The National Institute of Neurological Disorders and Stroke rtPA Stroke Study Group. Tissue plasminogen activator for acute ischemic stroke. *N Engl J Med* 1995;333:1581–1587.
 19. Hacke W, Kaste M, Fieschi C, et al. The efficacy of IV-rtPA in acute ischemic stroke: first results of the ECASS Group. Intravenous thrombolysis with recombinant tissue plasminogen activator for acute hemispheric stroke. The European Cooperative Acute Stroke Study (ECASS). *JAMA* 1995;274:1017–1025.
 20. Hacke W, Kaste M, Fieschi C, et al. Randomized, double-blind, placebo-controlled trial of thrombolytic therapy with intravenous alteplase in acute ischaemic stroke (ECASSII). *Lancet* 1998;352:1245–1251.
 21. Trouillas P, Nighoghossian N, Getenet JC, et al. Open trial of intravenous tissue plasminogen activator in acute carotid territory stroke. Correlation of outcome with clinical and radiological data. *Stroke* 1996;27:882–890.
 22. Trouillas P, Nighoghossian N, Derex L, et al. Thrombolysis in a series of 100 patients of acute carotid territory stroke with intravenous tissue plasminogen activator. Determination of etiological, topographical and radiological outcome factors. *Stroke* 1998;29:2529–2540.
 23. Scandinavian Stroke Study Group. Multicenter trial of hemodilution in ischemic stroke. Background and study protocol. *Stroke* 1985;16:885–890.
 24. Van Swieten JC, Koudstaal PJ, Visser MC, Schouten HJA, Van Gijn J. Inter-observer agreement for the assessment of handicap in stroke patients. *Stroke* 1988;19:604–607.
 25. Pessin MS. Hemorrhagic transformation in the natural history of acute embolic stroke. In: Hacke W, del Zoppo GJ, Hirschberg M. *Thrombolytic therapy in acute ischemic stroke*. New York: Springer-Verlag, 1991:67–74.
 26. Damasio H. A computed tomographic guide to the identification of cerebral vascular territories. *Arch Neurol* 1983;40:138–142.
 27. Hupperts RMM, Lodder J, Heuts-van Raak EPM, Kessels F. Infarcts in the anterior choroidal artery territory. Anatomical distribution, clinical syndromes, presumed pathogenesis and early outcome. *Brain* 1994;117:825–834.
 28. Bogousslavsky J. Topographic patterns of cerebral infarcts. Correlations with etiology. *Cerebrovasc Dis* 1991;1:61–68.
 29. Foy Ch, Chavany JA, Hillemand P, Schiff–Wertheimer S. Oblitération de l'artère choroïdienne antérieure. Ramollissement de son territoire cérébral. Hémiparésie, hémianesthésie, hémianopsie. *Bull Soc Ophtalmol Paris* 1925;37:221–223.
 30. Bogousslavsky J, Regli F, Delaloye D, Delaloye–Bischoff A, Uske A, Despland PA. Hemiataxie et déficit sensitif ipsilatéral. Infarctus du territoire de l'artère choroïdienne antérieure. Diaschisis cérébelleux croisé. *Rev Neurol (Paris)* 1986;142:671–676.
 31. Ghika JA, Bogousslavsky J, Regli F. Infarcts in the territory of the deep perforators from the carotid system. *Neurology* 1989;39:507–512.
 32. Helgason C, Caplan LR, Goodwin J, Hedges T. Anterior choroidal artery territory infarction. Report of patients and review. *Arch Neurol* 1986;43:681–686.
 33. Bruno A, Graff–Radford NR, Biller J, Adams HP Jr. Anterior choroidal artery infarction: a small vessel disease. *Stroke* 1989;20:616–619.
 34. Mohr JP, Steinke W, Timsit SG, Sacco RL, Tatemichi TK. The anterior choroidal artery does not supply the corona radiata and lateral ventricular wall. *Stroke* 1991;22:1502–1507.
 35. Leys D, Mounier–Vehier F, Lavenu I, Rondepierre P, Pruvot JP. Anterior choroidal artery territory infarcts: study of presumed mechanisms. *Stroke* 1994;25:837–842.
 36. Cambier J, Gravelleau P, Decroix JP, Elghozi D, Masson M. Le syndrome de l'artère choroïdienne antérieure. Etude neuropsychologique de 4 cas. *Rev Neurol (Paris)* 1983;139:553–559.
 37. Decroix JP, Gravelleau P, Masson M, Cambier J. Infarction in the territory of the anterior choroidal artery. A clinical and computerized tomographic study of 16 patients. *Brain* 1986;109:1071–1085.
 38. Boiten J, Lodder J. Lacunar infarcts. Pathogenesis and validity of the clinical syndromes. *Stroke* 1991;22:1374–1378.
 39. Zivin JA, Fisher M, De Girolami U, Hemenway CC, Stashak JA. Tissue plasminogen activator reduces neurological damage after cerebral embolism. *Science* 1985;230:1289–1292.
 40. Zivin JA, Fisher M, Lyden PD, et al. Tissue plasminogen activator: reduction of neurologic damage after experimental embolic stroke. *Arch Neurol* 1988;45:387–391.
 41. Traupe H, Kruse E, Heiss WD. Reperfusion of focal ischemia of varying duration: postischemic hyper- and hypoperfusion. *Stroke* 1982;13:615–622.
 42. Müller TB, Haraldseth O, Unsgard G. Characterization of the microcirculation during ischemia and reperfusion in the penumbra of a rat model of temporary middle cerebral artery occlusion: a laser Doppler flowmetry study. *Int J Microcirc* 1994;14:289–295.

Neurology[®]

rtPA intravenous thrombolysis in anterior choroidal artery territory stroke

P. Trouillas, L. Derex, N. Nighoghossian, et al.

Neurology 2000;54;666

DOI 10.1212/WNL.54.3.666

This information is current as of February 8, 2000

Updated Information & Services	including high resolution figures, can be found at: http://www.neurology.org/content/54/3/666.full.html
References	This article cites 37 articles, 22 of which you can access for free at: http://www.neurology.org/content/54/3/666.full.html#ref-list-1
Citations	This article has been cited by 2 HighWire-hosted articles: http://www.neurology.org/content/54/3/666.full.html#otherarticles
Permissions & Licensing	Information about reproducing this article in parts (figures, tables) or in its entirety can be found online at: http://www.neurology.org/misc/about.xhtml#permissions
Reprints	Information about ordering reprints can be found online: http://www.neurology.org/misc/addir.xhtml#reprintsus

Neurology® is the official journal of the American Academy of Neurology. Published continuously since 1951, it is now a weekly with 48 issues per year. Copyright . All rights reserved. Print ISSN: 0028-3878. Online ISSN: 1526-632X.

