

Cerebral Infarction with ICA Occlusion after Gamma Knife Radiosurgery for Pituitary Adenoma: A Case Report

Y.J. Lim, W. Leem, J.T. Park, T.S. Kim, B.A. Rhee, G.K. Kim

Department of Neurosurgery, Kyung Hee University Hospital, Seoul, Korea

Key Words

Gamma knife · Pituitary adenoma · Internal carotid artery occlusion · Cerebral infarction · Stereotactic radiosurgery

Abstract

Cranial irradiation may lead to accelerated atherosclerotic changes to small or medium sized arteries, but stroke associated with pituitary irradiation is not frequent. A patient treated with Gamma Knife radiosurgery (GKRS) for a pituitary adenoma suffered a cerebral infarction with internal carotid artery occlusion 4 years after radiosurgery. The patient was a 35-year-old male presenting with a visual disturbance. Endocrinological tests were normal. MRI revealed a 4.3 by 4.3 cm diameter invasive macroadenoma of the pituitary, projecting toward the suprasellar region and with cavernous sinus involvement with encasement of both internal carotid arteries (ICAs). GKRS was performed for residual tumor after a transcranial resection. The maximum dose was 40 Gy and the dose to the right carotid artery was below 20 Gy. The delayed hemiparesis was accompanied by a right capsular lacunar infarct shown on MRI. The images also showed a marked reduction in tumor size. Total, right ICA occlusion was confirmed by Doppler ultrasound. The patient had no history or signs of heart disease or metabolic disorder which could predispose to cerebrovascular complications. His hemiparesis and facial palsy recovered completely with conservative management. It is suggested that the possibility of carotid artery damage is considered during dose planning for pituitary adenomas.

Copyright © 1999 S. Karger AG, Basel

KARGER

Fax +41 61 306 12 34
E-Mail karger@karger.ch
www.karger.com

© 1999 S. Karger AG, Basel
1011-6125/99/0725-0132\$17.50/0

Accessible online at:
www.karger.com/journals/sfn

Young Jin Lim, MD, PhD, Department of Neurosurgery,
Kyung Hee University Hospital,
1, Hoeki-Dong, Dongdaemun-Gu, Seoul (Korea)
Tel. +82 2 958 8385, Fax +82 2 958 8380
E-Mail saraband@elim.net

Introduction

Pituitary insufficiency, visual dysfunction, dysfunction of the cranial nerves in the cavernous sinus, and vascular complications occasionally follow irradiation of pituitary tumors [1].

Despite numerous publications on radiation-induced acute vascular changes, delayed effects have not been well studied. Cerebrovascular accidents with intracranial artery occlusion after conventional radiation therapy have been reported in about 4.7–7.2% of cases [2, 3]. However, there is no literature about this complication after radiosurgery for the treatment of pituitary adenomas.

We report a case of cerebral infarction with internal carotid artery occlusion following Gamma Knife radiosurgery (GKRS) for a residual post-operative invasive macroadenoma.

Case Report

A 35-year-old male patient was admitted following a six-month history of visual disturbance. Neurological examination revealed a left homonymous hemianopsia and decreased visual acuity. MRI showed a 4.3×4.3 cm pituitary mass projecting towards the suprasellar region with encasement of both internal carotid arteries (fig. 1). The endocrinological findings were within the normal range. A subfrontal craniotomy with subtotal tumor removal was performed. The histological diagnosis was pituitary adenoma. After operation, the visual disturbance was markedly improved. Six months later, he was treated with GKRS for the residual tumor (fig. 2). The tumor volume was 8.3 cm³. Dose planning was performed using axial and coronal T1-weighted enhanced images. The margin dose was 12 Gy at the 50% isodose. Four 8 mm collimators and four 14 mm collimators were used. The dose to the carotid artery was less than 20 Gy.

Four years after GKRS, he was hospitalized due to the sudden development of a left hemiparesis and left facial palsy. MRI revealed a small lacunar infarction in the right internal capsular area and right internal carotid artery (ICA) occlusion in the cavernous sinus (fig. 3 a and b). Complete occlusion of the right ICA was confirmed on carotid vascular Doppler ultrasound (fig. 4). This patient had never suffered from diabetes mellitus or hypertension. His blood pressure was normal and the serum cholesterol level was 171 mg/dl. He had no abnormal findings on echocardiography or on 24-hour Holter monitoring. He was managed with conservative treatment and the neurological deficits recovered completely.

Discussion

Therapeutic options for pituitary adenomas have widened. Management by medical treatment, surgery, or radiotherapy is possible [4, 5], and treatment

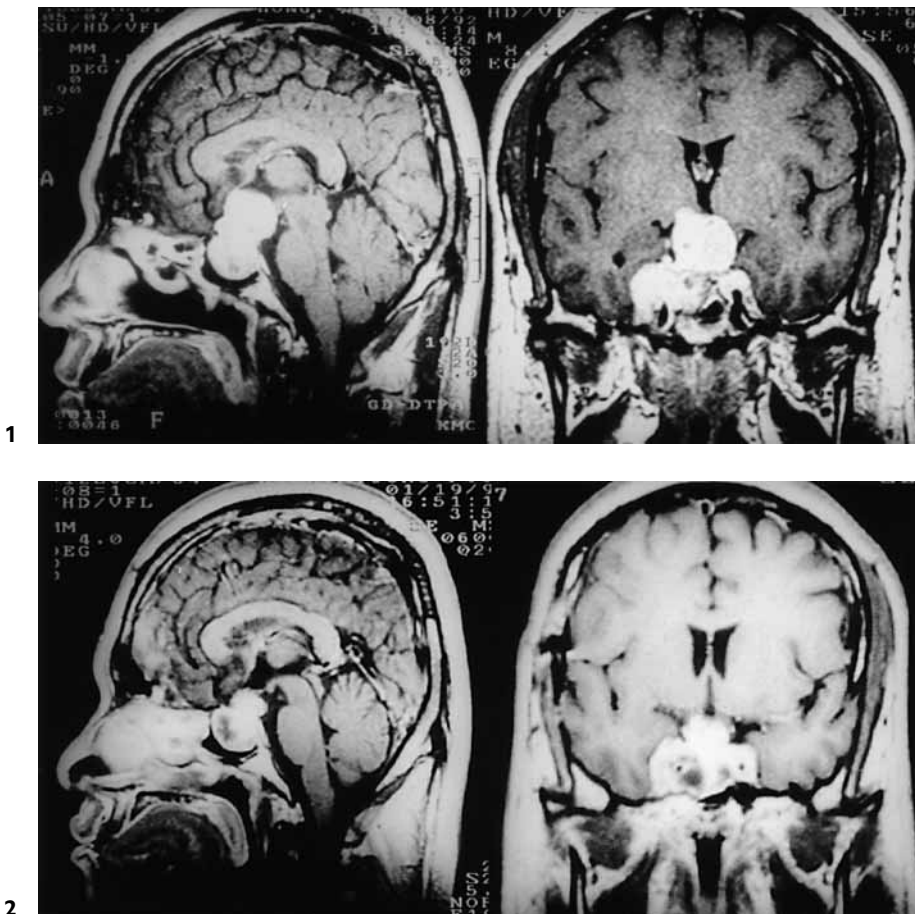


Fig. 1. Preoperative Gd-DTPA enhanced sagittal and coronal MRI scan showing a pituitary macroadenoma with infra-suprasellar extension which invaded to both cavernous sinuses.

Fig. 2. Gd-DTPA enhanced sagittal and coronal MRI scans, six months after operation, showing subtotal removal of tumor mass. Both internal carotid artery are patent. Gamma Knife was performed at this time.

success depends on various factors, including tumor size, invasiveness, localization, direction of growth and hormonal activity. Better surgical results with pituitary adenomas have been obtained with improving microsurgical techniques. Even so, in most cases of nonfunctioning adenomas, total surgical resection is often impossible due to their large size and the invasion into surrounding structures. Patients treated with surgery alone have been documented to have recurrence rates ranging from 21% to 86% [6–9]. Conventional

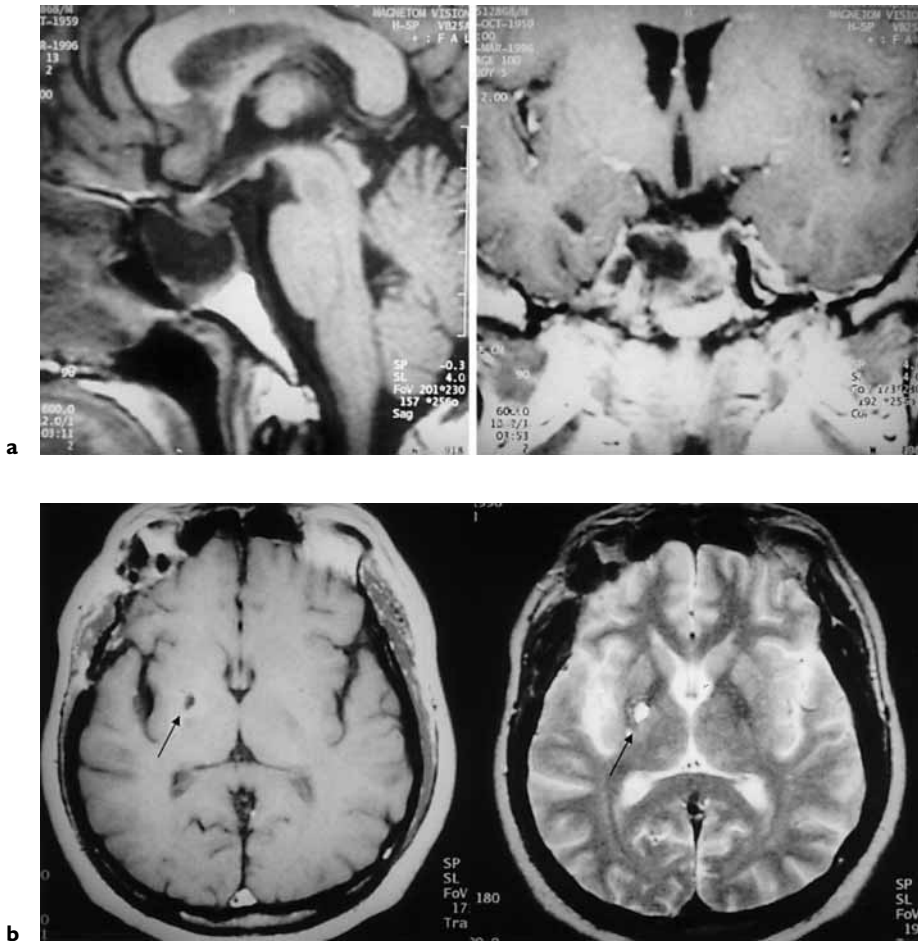


Fig. 3. **a** Four years after radiosurgery follow-up sagittal and coronal MRI scans show markedly reduced tumor size and loss of flow-void signal at the right internal carotid artery. **b** T1 and T2 transaxial MRI scans reveal lacunar infarction at the right internal capsular area (arrow).

radiotherapy has long been used postoperatively for residual tumor or in case of recurrence. Those series of patients where postoperative radiation therapy was used generally report a local tumor control rate of 85–90% at 10 years and a reduced recurrence rate [6, 10–15]. However, the major drawback of postoperative conventional radiation therapy is a high complication rate, including panhypopituitarism and visual disturbances. Cerebral stroke is one of the complications reported after radiation treatment for pituitary adenomas [2, 3].

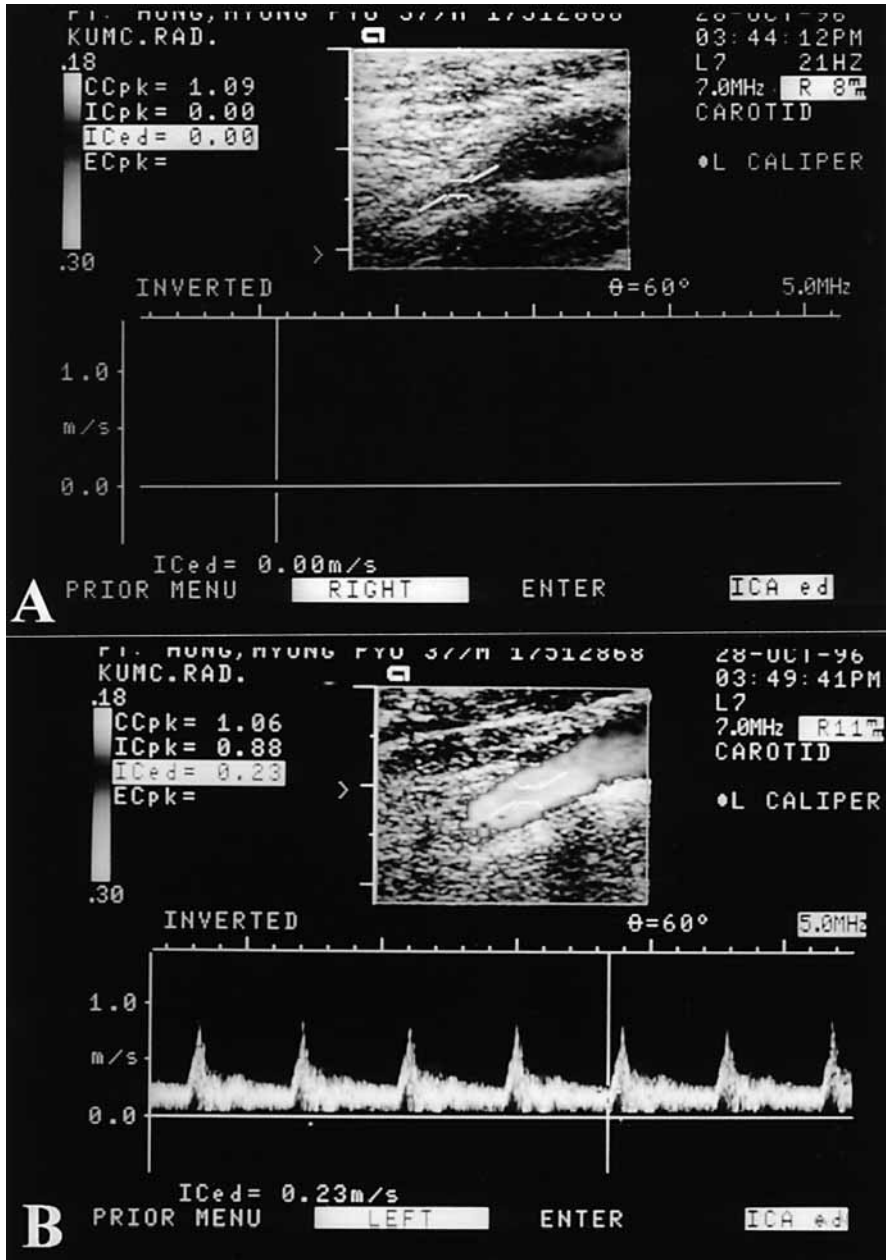


Fig. 4. Carotid vascular Doppler ultrasound. **a** Complete occlusion of right proximal internal carotid artery with no flow wave. **b** Normal left internal carotid artery.

Radiosurgery as an effective and safe adjuvant postoperative treatment modality has been performed in many institutions recently. Few complications are reported after radiosurgery for pituitary adenomas relative to conventional radiation therapy. In some series, complications such as pituitary insufficiency and visual disturbance occurred in 1–2% of cases [16, 17].

Accelerated atherosclerosis is a well-recognized complication of irradiation [18]. Small-vessel changes include fibrinoid necrosis, endothelial damage, adventitial fibrosis, and perivascular infiltrates of lymphocytes [19]. Medium and large-vessel changes include atherosclerotic changes, such as plaques, calcification, fragmentation of the internal elastic lamina, fibrosis of the vessel wall, and fat laden macrophages [20]. Small arteries of the vasa vasorum become fibrotic and may contribute to the atherosclerotic changes of large vessels. The atherosclerotic process may progress to total occlusion and, if the carotid arteries are involved, a picture of moyamoya disease [19, 20].

Zawadzki et al. [21] classified the angiographic findings of post-radiation arterial occlusion into 3 groups as follows:

- (1) Stenosis or occlusion of the internal carotid artery and/or its branches,
- (2) Proximal occlusion of the internal carotid artery associated with Moyamoya disease, characterized by an irregular vascular network and leptomeningeal, transdural anastomoses,
- (3) Diffuse cerebral arteritis.

There are various factors related to the occurrence of cerebral stroke after irradiation of pituitary adenomas. According to Silverberg et al. [22], hypercholesterolemia, hyperlipidemia and old age are definitely related to the risk of stroke. However, radiation technique, radiation fraction and radiation duration in conventional radiation treatment are not related, and the role of radiation dose is unproven. Rajakulasingam et al. [23] suggested that the age of patients at the time of radiation therapy might be one of the most relevant factors for the development of arterial occlusion. These authors suggested that the wall of the truncal artery of infants and younger children might be more vulnerable to the radiation effect than the adult artery. In reviewing a series of patients receiving radiation therapy for non-functioning adenomas of the pituitary gland at the University of Pittsburgh, a number of cases were found to suffer subsequent cerebral infarctions. It was suggested that radiation therapy would not be expected to be related to the development of a subsequent stroke in adults [3]. These authors also reviewed previously reported cases of intracranial arterial occlusion after radiotherapy and were unable to find a clear correlation between this complication and radiation dose [3, 24]. In reviewing 156 patients irradiated for pituitary adenomas, Flickinger et al. [3] found that seven suffered strokes.

The occurrence of these strokes was delayed 3.2–14.6 years after irradiation. Multivariate analysis found that the risk of stroke was related to age but not to the dose of radiation. There was no significant difference in stroke incidence between the irradiated group and a non-irradiated control population. Hashimoto et al. [2] reported the long-term follow-up of 139 patients with pituitary tumors who received radiation therapy. Strokes developed in ten after they received doses that varied between 50 and 60 Gy (mean 56.4 Gy), and brain necrosis developed in three. This complication could reasonably be expected to be related in some way to the radiation dose.

Darmody et al. [25] reported the occurrence of stroke in patients treated with more than 105 Gy, and there was large vessel occlusion with dose of 35.6 Gy in Bowen's series [1]. Although most reported cases received irradiation doses of at least 40 Gy, carotid damage has been reported with doses as low as 10 Gy in Murros' series [19]. The possibility remains that patients treated to higher radiation doses may be at a higher risk for the subsequent development of cerebral infarction. Even so, the dose given to the carotid artery with currently used GKRS dose for pituitary adenomas seems inadequate to produce clinically relevant arterial damage.

No case of cerebral stroke due to carotid artery occlusion following radiosurgery for a pituitary adenoma had previously been documented. Nonetheless, various complications after radiosurgery for pituitary adenomas have been reported in many series since 1990 [16, 17, 26–28]. Predisposing factors such as diabetes mellitus, hypertension, heart diseases, hypercholesterolemia or hyperlipidemia to induce stroke were not found in this case, and carotid stenosis is very rare in oriental people compared with occidentals. The occurrence of cerebral stroke should be considered as one of the possible delayed complications of GKRS for pituitary adenomas.

Conclusion

A patient treated with GKRS for a pituitary adenoma developed ICA occlusion and stroke four years after treatment. There were no other predisposing factors that could explain this event. It is suggested that the possibility of carotid artery damage be considered during dose planning for pituitary adenomas and that special care be taken.

References

- 1 Bowen J, Paulsen CA: Stroke after pituitary irradiation. *Stroke* 1992;23:908–911.
- 2 Hashimoto N, Handa H, Yamashita J, Yamagami T: Long-term follow-up of large or invasive pituitary adenomas. *Surg Neurol* 1986;25:49–54.

- 3 Flickinger JC, Nelson PB, Taylor FH et al.: Incidence of cerebral infarction after radiotherapy for pituitary adenoma. *Cancer* 1989;63:2404–2408.
- 4 Andrews DW: Pituitary adenomas. *Curr Opin Oncol* 1994;6:53–59.
- 5 Marks LB: Conventional fractionated radiation therapy vs radiosurgery for selected benign intracranial lesions (arteriovenous malformations, pituitary adenomas, and acoustic neuromas). *J Neuro-Oncol* 1993;17:223–230.
- 6 Ciric I, Mikhael M, Stafford T et al.: Transsphenoidal microsurgery of pituitary macroadenomas with long-term follow-up results. *J Neurosurg* 1983;59:395–401.
- 7 Comtois R, Beauregard H, Somma M et al.: The clinical and endocrine outcome to transsphenoidal microsurgery of non-secreting pituitary adenomas. *Cancer* 1991;68:860–866.
- 8 Hayes TP, Davis RA, Raventos A: The treatment of pituitary chromophobe adenomas. *Radiology* 1971;98:149–153.
- 9 Ray BS, Patterson RH: Surgical experience with chromophobe adenomas of the pituitary gland. *J Neurosurg* 1971;34:726–729.
- 10 Chun M, Masko GB, Hetelekidis S: Radiotherapy in the treatment of pituitary adenomas. *Int J Radiat Oncol Biol Phys* 1988;15:305–309.
- 11 Erlichman C, Meakin JW, Simpson WJ: Review of 154 patients with nonfunctioning pituitary tumors. *Int J Radiat Oncol Biol Phys* 1979;5:1981–1986.
- 12 Flickinger JC, Nelson PB, Martinez AJ et al.: Radiotherapy of nonfunctional adenomas of the pituitary gland. Results with long-term follow-up. *Cancer* 1989;63:2409–2414.
- 13 Grigsby PW, Simpson JR, Emami BW et al.: Prognostic factors and results of surgery and post-operative irradiation in the management of pituitary adenomas. *Int J Radiat Oncol Biol Phys* 1989;16:1411–1417.
- 14 McCollough WM, Marcus RB, Rhoton AL et al.: Long-term follow-up of radiotherapy for pituitary adenoma: The absence of late recurrence after ≥ 4500 cGy. *Int J Radiat Oncol Biol Phys* 1975;35:1574–1582.
- 15 Tran LM, Blount L, Horton D et al.: Radiation therapy of pituitary tumors: Results in 95 cases. *Am J Clin Oncol* 1991;14:25–29.
- 16 Stephanian E, Lunsford LD, Coffey RJ, Bissonette DJ, Flickinger JC: Gamma Knife surgery for sellar and suprasellar tumors. *Neurosurg Clin N Amer* 1992;3:207–215.
- 17 Thorén M, Rahn T, Guo LY, Werner S: Stereotactic radiosurgery with cobalt-60 gamma unit in the treatment of growth hormone producing pituitary tumors. *Neurosurgery* 1991;29:663–668.
- 18 Conomy J, Kellermayer R: Delayed cerebrovascular consequences of therapeutic radiation: A clinico-pathologic study of a stroke associated with radiation-related carotid arteriography. *Cancer* 1975;36:1702–1708.
- 19 Murros KE, Toole JA: The effect of radiation on carotid arteries. *Arch Neurol* 1989;46:449–455.
- 20 Mori K, Takeuchi J, Ishikawa M et al.: Occlusive arteriopathy and brain tumor. *J Neurosurg* 1978;49:22–35.
- 21 Zawadzki MB, Anderson M, De Armond S et al.: Radiation-induced large intracranial vessel occlusive vasculopathy. *Amer J Radiol* 1980;134:51–55.
- 22 Silverberg G, Britt R, Goffinet D: Radiation-induced carotid artery disease. *Cancer* 1978;41:130–137.
- 23 Rajakulasingam K, Cerullo LJ, Raiimondi AJ: Childhood Moyamoya syndrome: Postirradiation pathogenesis. *Childs Brain* 1979;5:467–475.
- 24 Hirata Y, Matsukado Y, Mihara Y et al.: Occlusion of the internal carotid artery after radiation therapy for the chiasmal lesion. *Acta Neurochir(Wien)* 1985;74:141–147.
- 25 Darmody W, Thomas LM, Gurdjian ES: Post-irradiation vascular insufficiency syndrome. *Neurology* 1967;17:1190–1192.
- 26 Motti EDF, Losa M, Pieralli S et al.: Stereotactic radiosurgery of pituitary adenomas. *Metabolism* 1996;45:111–114.
- 27 Lim YJ, Leem W, Kim TS, Rhee BA, Kim GK: Four years' experiences in the treatment of pituitary adenomas with Gamma Knife radiosurgery. *Stereotact Funct Neurosurg* 1998;70(suppl 1):95–109.
- 28 Kondziolka D, Claassen D, Linskey ME, Flickinger JC, Lunsford LD: Cranial nerve sensitivity and radiosurgery; Results with the rat optic chiasm model. *Acta Neurochir* 1993;122:147