

A Case of Very Large Cyst Formation with Gamma Knife Radiosurgery for an Arteriovenous Malformation

M.S Kim, S.I. Lee, J.H. Sim

Department of Neurological Surgery, Inje University, Pusan Paik Hospital,
Pusan, Korea

Key Words

Arteriovenous malformation · Stereotactic radiosurgery · Cyst · Ommaya reservoir · Gamma Knife · Complications

Abstract

A 17-year-old male patient underwent Gamma Knife radiosurgery (GKRS) for a left parietal arteriovenous malformation (AVM), which presented with hemorrhage. The 15.0 cm³ nidus was covered with the 50% isodose. The maximum dose was 50 Gy and the margin dose was 25 Gy. Eleven months later he developed a right hemiparesis and MRI showed a large cyst. Cerebral angiography showed partial obliteration of the AVM nidus. Stereotactic removal of cyst fluid (about 70 cm³) was performed, and an Ommaya reservoir was inserted. Cyst formation after GKRS for cerebral arteriovenous malformation is a side effect of radiosurgery about which we need to learn more.

Copyright © 1999 S. Karger AG, Basel

Introduction

Stereotactic Bragg peak proton beam irradiation of arteriovenous malformations (AVMs) was begun in the 1960s by Kjellberg and associates [1]. Over 5,000 cases of AVM have been treated with stereotactic radiosurgery and a favorable outcome has been obtained in most cases. It takes 2–3 years for complete angiographic obliteration to occur. The treatment is uncom-

KARGER

Fax +41 61 306 12 34
E-Mail karger@karger.ch
www.karger.com

© 1999 S. Karger AG, Basel
1011–6125/99/0725–0168\$17.50/0

Accessible online at:
www.karger.com/journals/sfn

Moo Seong Kim, MD
Neurosurgical Department, Inje University, Pusan Paik
Hospital, 633-165 KaeKeum Dong Jin-Ku, Pusan (Korea)
Tel. +82 51 890 6085, 6874; Fax +82 51 893 9368, 898 4244
E-Mail nsmsk@ijnc.inje.ac.kr; KIMMS@mediKorea.net

monly associated with complications, including brain swelling, cerebral ischemia, radionecrosis and demyelination. Delayed cyst formation after Gamma Knife radiosurgery (GKRS) for cerebral arteriovenous malformation is very rare, with about 10 cases reported in the literature [2–4]. The mechanism underlying delayed cyst formation after GKRS for cerebral arteriovenous malformation is obscure.

From October 1994 to October 1998, 82 patients with AVM were treated by the authors with GKRS. In one of these cases, a 17-year-old male patient, the treatment was associated with an intracerebral hematoma. Eleven months later, a huge cyst developed. Stereotactic cyst aspiration was performed and an Ommaya reservoir was inserted.

Case Report

A 16-year-old male was admitted in September 1996, with an acute onset right hemiparesis and dysphasia. A computerized tomographic scan revealed a large hematoma in the left parietal region. A cerebral angiogram showed a left-sided AVM fed by the left middle cerebral artery. The diameter of the nidus was about 5 cm (fig. 1).

The patient (now ages 17) underwent GKRS in February 1997. The maximum dose was 50 Gy, and the margin dose was 25 Gy. The AVM volume was 15.01 cm³. At follow-up in January 1998, he had developed a progressive right hemiparesis. MRI showed a huge cyst associated with the left parietal AVM. Angiography showed approximately 80% reduction in the size of the AVM nidus (fig. 2).

In January, 1998, stereotactic cyst aspiration was performed and 60 cm³ of xanthochromic fluid was aspirated. An Ommaya reservoir was inserted. The cytology of the cystic fluid was negative for tumor cells. After surgery the symptoms improved and CT showed that the cyst had disappeared.

Discussion

The progressive occlusion of an AVM after GKRS usually takes from 1 to 3 years. The mechanism of the occlusion of AVM is thought to be radiation induced endothelial proliferation, collagen deposition, progressive endothelial hypertrophy and finally luminal closure [5, 6]. Pollock et al. [7] reported 64% complete angiographic obliteration, 28% decreased nidus, and seven no change in cases. They observed a 4.8% annual risk of hemorrhage during the first 2 years after GKRS. Steiner et al. [8] reported 35 cases (3.5%) where delayed complications, such as headache and radiation necrosis, occurred during a 4–56 months follow-up (mean 9.9 months) in 1,000 cases of AVMs. Lunsford et al. [9] reported a complete obliteration rate at

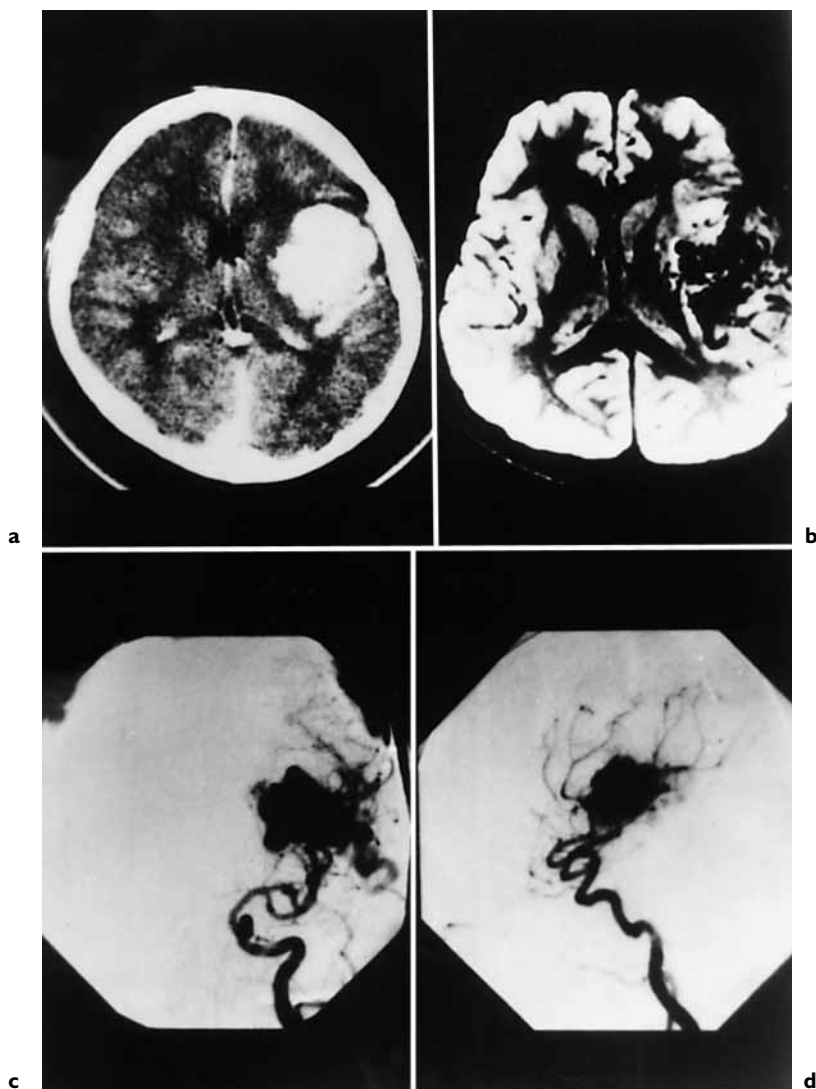


Fig. 1. **a, b** CT scan and MRI revealed a large hematoma with on AVM in the left fronto-temporal. **c, d** Four-vessel angiography disclosed an AVM at the location of the hematoma.

2 years, which varied according to lesion volume; for 1 cm³ 100%, 1–4 cm³ 85%, and 4–10 cm³ 58%. Moreover, he reported a 4.4% complication rate. Lindquist [10] observed three AVM patients with delayed cyst formation who remained asymptomatic. Forster [3] also observed three AVM patients who developed asymptomatic cysts. One of these underwent surgery to rule

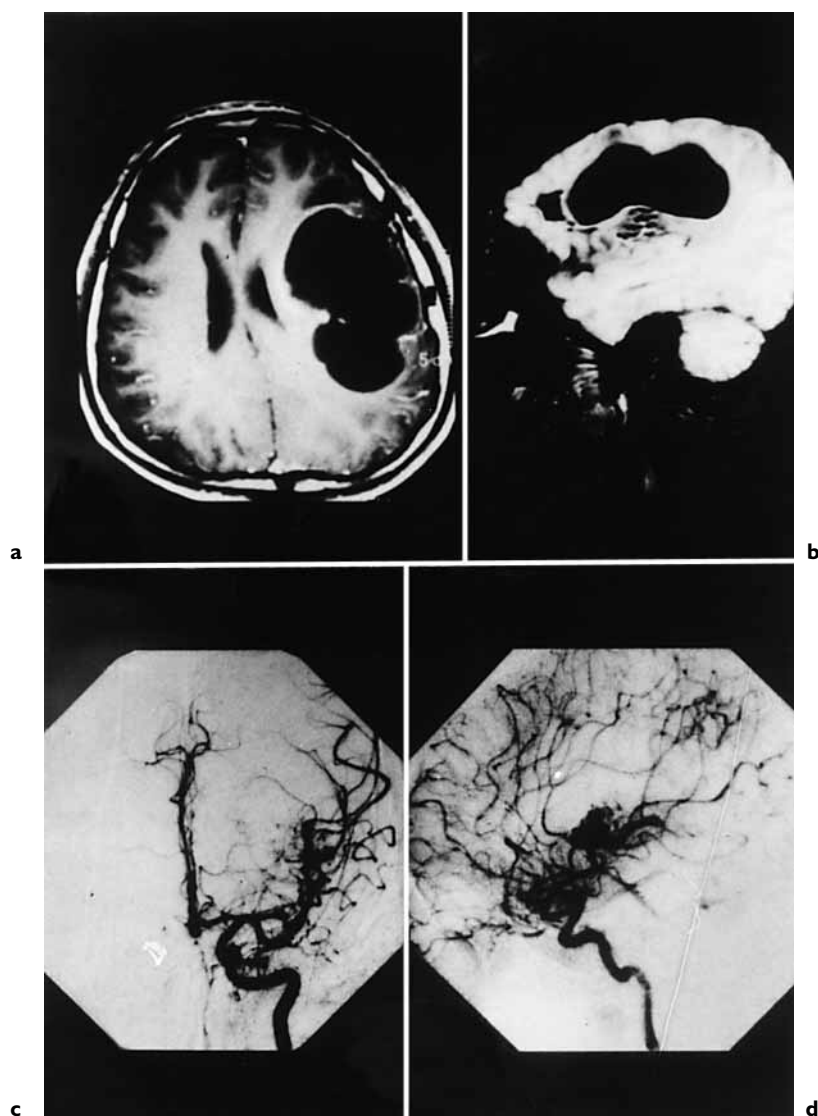


Fig. 2. **a, b** Sequential T1-weighted MR images obtained 11 months after radiosurgery showing an enlarging hypointense cyst. **c, d** Angiogram obtained 11 months after radiosurgery showing partial obliteration of the AVM nidus.

out the possibility of neoplastic changes. However, the pathological study disclosed nothing of note other than gliosis and a spongiform changes.

Tanaka et al. [2] reported two cases of cyst formation after GKRS for AVM. A 26-year-old male had microsurgery for an AVM with a left frontal

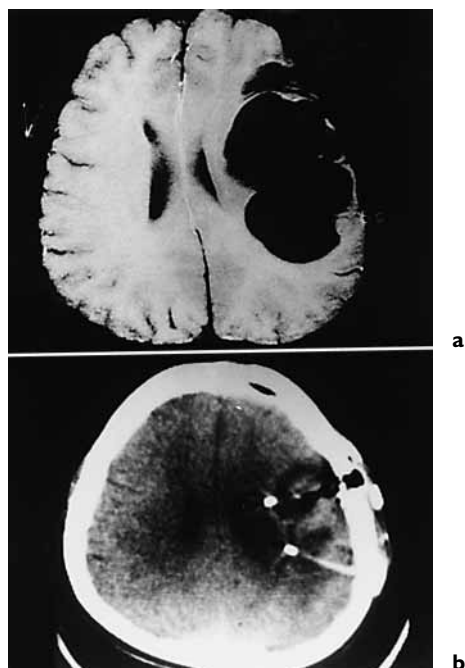

Fig. 3. **a** MRI showed an enlarged huge cyst. **b** Two Ommaya reservoirs inserted in the cyst.

intracerebral hematoma. GKRS was performed for a residual AVM, the diameter of which was 20 mm. The maximum dose was 34 Gy and the margin dose was 16 Gy. At 15 months after the treatment, the AVM had completely disappeared. However, about 3 years later, the patient developed a headache and MRI showed a large cyst in the irradiated region. A biopsy was taken and a cystoperitoneal shunt was inserted. Histological examination showed gliosis. The other case reported by this group concerned an 11-year-old boy. Ventricular drainage had been performed following a left thalamic and intraventricular hemorrhage. The diameter of the nidus was 23 mm. At GKRS, the maximum dose was 44.5 Gy and the margin dose was 20 Gy. After 24 months the AVM was obliterated. About 1 year later, the patient developed a headache and a tremor in his right hand. The MRI showed a large cyst. A biopsy was taken and an Ommaya reservoir was inserted. Histological examination showed gliosis.

Hara et al. [11] reported two symptomatic patients. The location of each of the cysts corresponded to the location of an initial hematoma. Surgical intervention was undertaken and histological examination of the nidus showed the majority of vessels were obliterated and hyalinized. Some thick-walled

recanalizing vessels and/or patent blood vessels were observed within these obstructed vessels.

Yamamoto et al. [12, 13] described AVMs where late cysts developed. One was a 25-year-old person. The region which had received a high radiation dose became surrounded by edema at the 79th month after radiosurgery. The other cyst in this material was observed at autopsy. Follow-up angiogram had shown complete nidus obliteration. Histological examination of the resected nidus showed that many of the AVM vessels were occluded due to intimal hypertrophy. Nonetheless, there were still patent vascular channels in the nidus, which were not observed angiographically.

The mechanism of delayed cyst formation remains obscure. Four different mechanisms are cited for the formation of cysts associated with brain tumors [14]:

- (1) An intratumoral cyst may be due to degenerative changes of the neoplastic tissue; as seen in astrocytomas and hemangioblastomas.
- (2) A peritumoral cyst may arise because of a block in CSF circulation, as occurs with meningiomas.
- (3) A cyst with a wall composed of glial or connective tissue may be caused by a glial reaction.
- (4) A cyst may be formed by intratumoral or intracerebral hemorrhage.

These same mechanisms may occur with an AVM. It is thought that there may have been three different mechanisms leading to cyst formation in presence of an AVM. These are hemorrhage, exudation or a breakdown of the blood-brain barrier. Once hemorrhage occurs, however, it may produce a pseudo-aneurysm with an extremely thin wall. Then serum may be exuded from its wall. Furthermore, relatively high blood flow values and increased permeability through incompletely occluded blood vessel walls within the treated nidus, whether angiographically visible or not, may enhance cyst formation within the region. Radiosurgically-induced degeneration, coagulation necrosis to liquefaction necrosis continues for several years after radiosurgery [14]. Furthermore, the location of the initial hematoma may facilitate the accumulation of cystic fluid due to increased permeability through the residual nidus following treatment. An autopsy report from an AVM patient who died from an unrelated cause 27 months after treatment was reported by Fujino et al. [15]. This report disclosed exudation of albuminous fluid within the treated nidus.

Cyst formation after GKRS for cerebral AVM can occur and long-term MRI follow-up studies should be performed.

References

- 1 Kjellberg RN, Hanamura T, Davis KR, Lyons SL, Adams RD: Bragg-peak proton-beam therapy for arteriovenous malformations of the brain. *N Eng J Med* 1983;309:269–274.
- 2 Tanaka T, Kobayashi T, Kida Y: Two cases of cyst formation after Gamma Knife radiosurgery for AVM. Presented at the 5th International Workshop on Cerebrovascular Surgery, Fukuoka, Japan. 1997, pp 3–5.
- 3 Forster DMC: Complication management. Presented at the 2nd Congress of the International Stereotactic Radiosurgery Society, Boston, Mass, 1995, pp 14–17.
- 4 Yamamoto M, Ide M, Jimbo M, Takakura K, Lindquist C, Steiner L: Neuroimaging studies of postobliteration nidus changes in cerebral arteriovenous malformations treated by Gamma Knife radiosurgery. *Surg Neurol* 1996;45:110–122.
- 5 Karlsson B, Kihlström L, Lindquist C, Steiner L: Gamma Knife Surgery for previously irradiated arteriovenous malformation. *Neurosurgery* 1998;42:1–6.
- 6 Schneider BE, Eberhard DA, Steiner LE: Histopathology of arteriovenous malformations after Gamma Knife radiosurgery. *J Neurosurg* 1997;87:352–357.
- 7 Pollock BE, Lunsford LD, Kondziolka D, Maitz A, Flickinger JC: Patient outcome after stereotactic radiosurgery for ‘operable’ arteriovenous malformations. *Neurosurgery* 1994;35:1–8.
- 8 Steiner L, Lindquist C: Radiosurgery in cerebral arteriovenous malformation; in Tasker RR (ed) *Neurosurgery; State of the Art Reviews. Stereotactic Surgery*. Philadelphia, Hanley and Belfus, 1987, pp 329–336.
- 9 Lunsford LD, Kondziolka D, Flickinger JC, Bissonette DJ, Jungreis CA, Maitz AH, Horton JA, Coffey RJ: Stereotactic radiosurgery for arteriovenous malformation of the brain. *J Neurosurg* 1991;75:512–524.
- 10 Lindquist C: Complication management. Presented at the 2nd Congress of the International Stereotactic Radiosurgery Society, Boston, Mass, 1995.
- 11 Hara M, Maeda R, Takeuchi K, Kitamura M: Biochemical analysis of cyst fluid of brain tumor. *Brain Nerve* 1974;26:1975–1082.
- 12 Yamamoto M, Jimbo J, Ide M, Kobayashi M, Toyoda C, Lindquist C, Karlsson B: Gamma Knife radiosurgery for cerebral arteriovenous malformations: An autopsy report focusing on irradiation-induced changes observed in nidus-unrelated arteries. *Surg Neurol* 1995;44:421–427.
- 13 Yamamoto M, Jimbo M, Hara M, Saito I, Mori K: Gamma Knife radiosurgery for arteriovenous malformations: Long-term follow-up results focusing on complications occurring more than 5 years after irradiation. *Neurosurgery* 1996;38:906–914.
- 14 Maiuri F, Benvenuti D, De Simon MR, Cirillo S, Correiero G, Giamundo A: Cystic lesions associated with meningiomas. *Surg Neurol* 1986;26:591–597.
- 15 Fujino H, Inomori S, Nakayama T, Shutoh T, Nagano N, Katoh E, Tashiro M, Murayama S: Pathological findings of cured arteriovenous malformation after Gamma Knife radiosurgery. Presented at the 4th Annual Meeting of the Japanese Society of Stereotactic Radiosurgery, Sendai, Japan, 1995, pp 15