

Palinopsia and polyopia in the absence of drugs or cerebral disease

Howard D. Pomeranz, MD, PhD; and Simmons Lessell, MD

Article abstract—*Objective:* To report the occurrence of palinopsia and polyopia in patients who neither used drugs nor had diseases of the cerebral hemispheres, a group in which these visual symptoms have not been reported. *Method:* The patient records in the database of an academic neuro-ophthalmology unit were reviewed. *Results:* Seventeen patients were identified in the database with the diagnosis of palinopsia or polyopia, of whom eight had diseases of the cerebral hemispheres, leaving nine patients for analysis. No patients with a history of drug toxicity were identified. In one patient the symptoms presented during an initial episode of demyelinating optic neuritis in the absence of clinical or laboratory evidence of cerebral lesions. In another patient they developed immediately after laser treatment of diabetic macular edema. A third patient developed the symptoms in association with visual loss from Leber's hereditary optic neuropathy. The other six patients were healthy individuals. *Conclusion:* Palinopsia and related visual symptoms can occur in otherwise healthy individuals and in patients with disease apparently confined to the eye or the optic nerve. **Key words:** Palinopsia—Polyopia—Visual hallucinations—After-image.

NEUROLOGY 2000;54:855–859

Palinopsia is a symptom distinct from the physiologic after-image in which images of an object persist or reappear after the patient has stopped looking at the object.¹⁻³ In some cases patients see a series of "echoes" of the object, separate from but in proximity and identical to the actual object, giving the impression of polyopia (cerebral polyopia). Eye movement may make the original object appear to leave a trail. These abnormal positive visual phenomena may occur in the same patient and may well be related pathophysiologically. Palinopsia, cerebral polyopia, and visual trailing are usually reported by patients with neurologic and psychiatric disorders or by individuals who have used or abused certain drugs. However, we have encountered these symptoms in healthy individuals who presumably had not and were not using illicit drugs, and in patients with diseases apparently limited to the retina or optic nerve. They were identified in the computerized database of the neuro-ophthalmology unit of the Massachusetts Eye and Ear Infirmary. Their case histories are the basis of this report.

Case reports. *Patients with reduced vision.* Patient 1. Two days after grid laser treatment for diabetic macular edema of her right eye, a 70-year-old woman began to notice "repetition of images." She would see a scene repeated if she looked away. For example, on one occasion she looked across the street at a blond woman and then on looking elsewhere toward a man, was startled to see the image of the blond woman in front of the man. She also noticed that when she looked at a television screen everything appeared "cracked." The symptoms cleared after several weeks only to reappear spontaneously 2 weeks later.

Her vision had been decreasing for 5 years from diabetic retinopathy and she had experienced two vitreous hemorrhages in her left eye. Glaucoma recognized 1 year earlier had been treated with a laser trabeculoplasty. She also had drug-controlled hypertension and unexplained normochromic, normocytic anemia. At the time of her palinopsia she could see only 20/100 with her right eye and hand motions with her left. Her neurologic history was positive only for 1 hour of slurred speech a year earlier. No abnormalities were found on neurologic examination. Her medications were levothyroxine, Glyburide, Clonazepam, Metformin, Metoprolol, and Enalapril.

Several months later the patient developed occlusion of the left middle cerebral artery, which rendered her aphasic and hemiplegic and prevented us from learning if her palinopsia had persisted. MRI performed after the stroke showed no lesions other than the recent brain infarction.

Patient 2. A 41-year-old woman first noticed blurred vision in both eyes while driving. Her vision gradually worsened and she realized that her color vision was impaired. There was a history of alcohol abuse but she ate well and denied using illicit drugs. Her family history was negative for eye and neurologic disorders. Shortly after her vision failed, she started to notice prolonged after-images, especially when she was tired or when she was seated in a moving vehicle. She stated that the images appeared to be "following me all the way" for up to an hour. As an example she reported that the image of a pink automobile that she had seen as she passed a parking lot remained in view for half an hour as her vehicle traveled to other areas. This symptom occurred infrequently.

Eighteen months after the onset of her visual problem her visual acuity was best corrected to 20/400 bilaterally with central scotomas and optic atrophy. Neurologic examination showed an anxious and depressed woman with

From the Department of Ophthalmology, Harvard Medical School and the Neuro-Ophthalmology Unit, Massachusetts Eye and Ear Infirmary, Boston, MA. Received August 5, 1999. Accepted in final form October 1, 1999.

Address correspondence and reprint requests to Dr. Howard D. Pomeranz, University of Maryland, Department of Ophthalmology, 419 West Redwood Street, 4th Floor, Baltimore, MD 21201.

minimal signs of a peripheral polyneuropathy. Cranial MRI and CT, EEG, and examination of the CSF gave negative results. There was a nonrecordable visual evoked response but her brainstem auditory and somatosensory evoked responses were within normal limits. Tests on the patient's blood showed that she was homoplasmic for the 11778 mitochondrial DNA mutation associated with Leber's hereditary optic neuropathy. No follow-up information is available.

Patient 3. A 39-year-old woman who was well psychiatrically, ophthalmologically, and neurologically developed pain in her left eye that was aggravated by eye movement. Within days the vision in that eye failed to the extent that she could only count fingers, but her right eye retained normal visual acuity and both of her fundi were unremarkable. Her medical history was notable for asthma and thrombophlebitis. She was being treated with Warfarin. She denied ever using illicit drugs. The patient's brother had MS. Brain MRI showed no abnormalities. Within 2 months her visual function had recovered spontaneously and completely; however, she reported that she had been seeing abnormally persistent after-images. For example she related an incident in which, "I looked at my foot, I looked away and still saw my foot." The palinoptic images were seen as a black-and-white outline. When she experimented by alternately closing each eye she found that she only saw after-images when she looked with her right eye (the unaffected eye).

The palinopsia stopped spontaneously and never recurred despite several additional attacks of optic neuritis in each eye. Several years later the development of spinal cord symptoms and signs, and the appearance of spinal cord lesions on MRI led to a diagnosis of MS. She has been stable neurologically and free of palinopsia for the past decade.

Patients with normal vision. **Patient 4.** A 32-year-old psychiatrically and neurologically healthy woman whose only previous eye problem was myopia noticed an enhanced after-image. This occurred only after viewing an illuminated stimulus, especially on her computer screen. The image of the object would persist for several seconds and could be reestablished by blinking. Sometimes the object would appear to leave a trail if she moved. On one occasion she saw multiple images of the stimulus. The after-images were always isochromatic to the stimulus, and the size of the after-image was the same as that of the stimulus, not expanding in proportion to the distance from the surface on which it was projected. She denied using medications or illicit drugs currently or previously.

Examination 6 months after the onset of her symptoms showed that her best corrected visual acuities were 20/30 in the right eye and 20/25 in the left eye with normal color vision (Ishihara), full visual fields, and normal fundi. Her neurologic examination showed no abnormalities.

Patient 5. A 42-year-old healthy man with a negative psychiatric and neurologic history whose only eye problem had been congenital color blindness, had three 15-minute episodes in which he hallucinated a wavy line. The hallucinations began in the right paracentral area and expanded to form a pattern of scintillating, concentric, angulated lines. There were no headaches then or since. After the third episode he saw colorless, pulsating dots in the left inferior quadrant of his visual field that disappeared with eye closure. Evaluation by an ophthalmologist

failed to demonstrate any abnormalities and the episodes of wavy lines continued to occur several times a year.

At age 46 he became aware that he had abnormally persistent after-images especially after awakening in the morning. They would remain for several seconds and reproduce only a portion of the previous scene. Sometimes he would see multiple after-images if he moved his eyes. The size of the images expanded in proportion to the distance from the surface against which it was projected. The images were black and white ("like a photographic negative") unless precipitated by a brightly colored stimulus, in which case the colors were "reversed." Wearing sunglasses helped.

He denied using any medications or ever using illicit drugs. A neurologic examination, several neuro-ophthalmologic examinations, and two CT scans of the brain failed to demonstrate any abnormalities. Trials of phenytoin and propranolol therapy did not relieve the symptoms.

His uncorrected visual acuity at age 47 was 20/15 in each eye. Visual fields were full and his fundi were normal. When interviewed by telephone at age 63, 17 years after onset, the patient reported that his symptoms were unchanged and that his general health had remained normal.

Patient 6. A 28-year-old woman whose previous psychiatric, neurologic, and ophthalmologic health had been good developed daily, severe, throbbing left-side headaches. At the same time she started to have multiple visual disturbances. She saw numerous small bright lights "moving like fireflies" whenever she went into a brightly lit environment. In dim light she saw "snow—like watching a television channel that isn't broadcasting." She also had daily episodes in which she would see reduplications of images ("like vibrations"). The headache improved but the visual symptoms persisted. She denied using medications or illicit drugs currently or in the past. A neurologic examination revealed no abnormalities.

Examination 6 months after onset showed that her uncorrected visual acuity was 20/15 in each eye with normal color vision (Ishihara), full visual fields, and normal fundi.

During the next year the repetitive images appeared with increasing frequency and a trial of therapy with phenytoin failed to help. Neuro-ophthalmologic and neurologic examinations continued to give unremarkable results, and no abnormalities were found on cranial CT and MRI. Neither Clonazepam nor carbamazepine therapy lessened the symptoms.

Patient 7. A 28-year-old man whose only psychiatric, ophthalmologic, or neurologic problem had been fully correctable myopia became aware of small brown spots in the visual fields of both eyes and a throbbing, mild, left supraorbital headache. Shortly thereafter he noted additional visual symptoms. After prolonged gazing at a scene, certain portions would disappear. In daylight he would see images "like sparks or fireflies" and at night he would see what resembled "particles of snow floating around." He also became aware of unusual after-images. When he looked at something he would see several adjacent ghost images. Sometimes an object at which he was looking would reappear in another area of his visual field after a short interval (figure 1).

He denied drug use or abuse. A retinal evaluation and complete neurologic examination revealed no abnormalities. Cranial CT showed only that he had a smaller right




Figure 1. Patient 7. Patient's sketch of examples of abnormal images.

hemisphere. No abnormalities were seen on EEG. A trial of phenytoin therapy did not prove helpful.

Examination at age 29 showed that his corrected visual acuities were 20/15 in each eye with normal color vision (Ishihara) and full visual fields. Slit-lamp inspection showed normal anterior segments with clear media, and his fundi were unremarkable. His only ophthalmic abnormality was ocular hypertension with applanation intraocular pressures of 23 mm Hg in the right eye and 22 mm Hg in the left eye.

When he was reevaluated at the age of 35 he reported that all of his symptoms had persisted. His findings on examination were unchanged.

Patient 8. A 42-year-old man developed abnormal after-images. During the initial episode, which occurred while driving, he noticed that the headlights of passing vehicles left a peculiar and prolonged "trail." He stopped to eat at a restaurant, and on redirecting his gaze from his dinner plate to a window, he saw a clear and distinct image of his French-fries fried potatoes superimposed on the window. This experience caused him to drive home immediately from Maine to Massachusetts in a panic. Similar episodes continued with increasing frequency. He described moving objects as leaving "a trail." For seconds a ghost image would follow a moving stimulus and would merge with the stimulus when it stopped (figure 2). His persistent or recurrent images were isochromatic to the stimulus. He was most apt to notice the after-images if he awakened in the middle of the night, when fatigued, after having several alcoholic drinks, and on emerging into the

light from a movie theater. A neurologic examination and cranial MRI gave normal results. An EEG showed left temporal high-voltage theta activity during sleep deprivation and a generalized high-voltage burst during stage-two sleep. This activity was interpreted as insignificant. His medical history was notable for two episodes of depression more than a decade earlier, which was treated successfully with tricyclic antidepressants. He also had sleep apnea. Otherwise there was no history of neurologic or ophthalmologic disease. The patient denied any prior abuse of any drugs.

Examination at age 43 showed that his visual acuities were 20/15 in both eyes with normal color vision (Ishihara), fundi, and visual fields. When reevaluated 10 months later, the findings on examination were unchanged. His visual symptoms had persisted despite a course of Clonazepam and carbamazepine therapy, and he had developed a symptom in which sounds would sometimes briefly reverberate.

Patient 9. A 20-year-old previously healthy woman incurred brief loss of consciousness and a nondisplaced right orbital fracture in a bicycle collision. No other clinical or radiologic abnormalities were discovered at the time, and she did not require surgery. Recovery was complete without evident residua. Her psychiatric, ophthalmologic, and neurologic histories were otherwise negative. She denied using illicit drugs currently or previously. Her only medication was a birth control pill. There was no pertinent family history. At age 29 she developed new symptoms. At night, illuminated areas appeared to have a purple hue. She also noticed that after looking at a bright image she

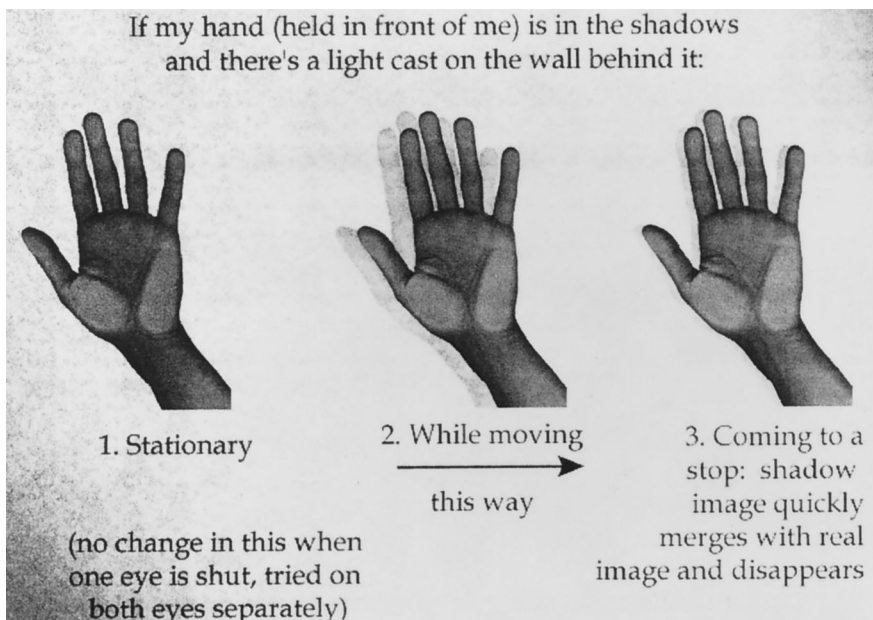


Figure 2. Patient 8. Patient's computer-assisted drawing of a palinoptic image.

would continue to see it for as long as at least 1 minute after looking away. The duration of the after-image was independent of the duration of gaze but was related to its brightness. The after-image did not appear to change size with the distance to the surface against which it was projected. Seven months later she noted additional symptoms. Moving objects appeared to leave a trail or smear and she would see repetitive images that she referred to as "echoes" of some moving objects. These symptoms were most apt to intrude in the morning, and wearing sunglasses reduced the frequency of the symptoms. Cranial MRI and neurologic examination revealed no abnormalities.

Neuro-ophthalmologic examination 8 months after onset showed that her uncorrected visual acuities were 20/15 in each eye with normal color vision (Ishihara) and full visual fields to the I4e on the Goldmann perimeter. Her anterior segments, pupils, lids, eye movements, and fundi were unremarkable. The patient refused trials of medications and no follow-up information is available.

Discussion. The following lists the circumstances in which palinopsia and related positive visual phenomena have been encountered:

Causes and associations of palinopsia

Drugs

- Marijuana^{1,2}
- Mescaline³
- Lysergic acid diethylamide¹⁻³
- 3,4-Methylenedioxymethamphetamine⁴
- Interleukin 2⁵
- Trazodone⁶
- Clomiphene citrate⁷
- Nefazodone^{8,9}

Seizures

- Temporal¹⁰
- Occipital^{11,12}
- Periodic lateralized epileptiform discharges¹³

Focal cerebral lesions

- Trauma^{14,15}
- Parasite¹⁶
- Abscess^{17,18}
- Stroke^{19,20}
- Tumor^{19,21}
- Arteriovenous malformation^{22,23}

Creutzfeldt–Jakob disease²⁴

MS²⁵

Carbon monoxide poisoning²⁶

Nonketotic hyperglycemia²⁷

Migraine²⁸

Psychiatric disease

- Schizophrenia^{29,30}
- Psychotic depression³¹
- Charles Bonnet syndrome³²

The assignment of patients among the various categories is somewhat arbitrary because there is overlap. For example, seizures undoubtedly are the mechanism for the palinopsia in some of the cases of focal cerebral lesions, and some of the patients with

ictal palinopsia have a focal cerebral lesion. The patients whose histories form the basis of the current report do not fit into any of these categories. To the best of our knowledge palinopsia and related positive visual phenomena have not been reported in healthy persons or in patients with disease confined to the eye or optic nerve. Bender et al.²¹ provide a very limited description of a case in which a hypertensive patient blind in one eye from an unspecified cause, and with hypertensive retinopathy, developed palinopsia. The information that was provided about that patient is insufficient to determine whether cerebral lesions might also have been present.

Three of our patients had subnormal visual acuities; two of them developed their symptoms shortly after vision became impaired. Visual hallucinations may be released when visual function is disrupted (the Charles Bonnet syndrome), but only rarely do those patients report palinopsia.³² None of the three patients with impaired vision reported the imagery that is *characteristic* of the Charles Bonnet syndrome; namely, images unrelated to what the individual has seen recently. Nevertheless, the symptoms might have been precipitated by the loss of vision, especially because in two of them the symptoms developed when the vision was lost. Because the remaining patients had normal visual function at the time of their symptoms, some other mechanism would have to be invoked.

None of our patients had evidence of lesions of the cerebral hemispheres at the time of their symptoms. One had the visual auras of migraine, but his symptoms did not occur with his migraines. Another patient had vascular headaches at the time her palinopsia first appeared, but her symptoms persisted after her headaches resolved. One patient experienced palinopsia as she recovered from an attack of optic neuritis, which was, in retrospect, the sentinel manifestation of MS. However, she had neither clinical nor MRI evidence of cerebral involvement then or later. MS tends not to cause symptoms of higher visual dysfunction even when it ravages the brain, but we are aware of the report of an MS patient with palinopsia.²⁵ In that patient the symptoms might have been residua of a prior bilateral optic neuritis, but MRI results were not reported in that patient. Our patient with "repetitive images" after laser treatment of diabetic retinopathy later developed a stroke, and it is possible that there was cerebral ischemia that went undetected at the time that she experienced her visual symptoms.

Although in one published case of palinopsia a patient could read an unfamiliar eye chart at which he had merely glanced when its image reappeared to him after he had looked away, the symptom generally cannot be verified.¹⁴ Therefore it remains possible, but in our opinion unlikely, that our patients fabricated their symptoms. Two of the patients were or had been depressed, and another had found his first attack of palinopsia a source of considerable anxiety, but the symptoms presented in the others at

a time when they were healthy emotionally. In none of the patients was secondary gain evident. There have been several reports of palinopsia and related positive visual phenomena developing or persisting in individuals who abused drugs even after the drug abuse had ceased.^{1,2} Although our patients denied having abused drugs, we recognize that it would not be unusual for patients to misrepresent their drug history.

It is also possible that our patients noticed and became fixated on *physiologic* after-images. However, in each patient the characteristics of the palinoptic images differed in some respect from physiologic after-images. These differences included multiple images on eye movement (Patient 5), multiple adjacent images (Patient 6), an interval between the original stimulus and the appearance of the after-image (Patient 7), trailing of the after-image (Patients 4, 8, and 9), isochromatic images (Patients 1, 2, and 4), constancy of image size regardless of the background (Patient 4), long duration (Patients 2 and 9), and seeing the images only with one eye (Patient 3).

Palinopsia is a symptom about which physicians are not apt to inquire and about which patients might not complain, especially if the patient is neurologically healthy, not on drugs, and feeling well. Patients with palinopsia might readily assume that their after-images are physiologic, and there is indeed evidence that the characteristics of the "retinal" after-image and those of palinoptic images overlap.¹³ In any case, it is likely that palinopsia and related positive visual phenomena are more prevalent, both in the healthy as a normal visual phenomenon as well as in the ill, than would be inferred from the paucity of reported patients. In light of our experience, it is clear that positive visual phenomena are not necessarily a symptom of brain disease or drug toxicity, or need have immediate or long-term consequences. However, the mechanism underlying the symptoms in these patients remains obscure.

References

1. Kawasaki A, Purvin VA. Persistent palinopsia following ingestion of lysergic acid diethylamide (LSD). *Arch Ophthalmol* 1996;114:47–50.
2. Levi L, Miller NR. Visual illusions with previous drug abuse. *J Clin Neuroophthalmol* 1990;10:103–110.
3. Critchley M. Types of visual perseveration: "paliopsia" and "illusory visual spread." *Brain* 1951;74:267–299.
4. McGuire PK, Cope H, Fahy TA. Diversity of psychopathology associated with use of 3,4-methylenedioxymethamphetamine ('Ecstasy'). *Br J Psychiatry* 1994;165:391–395.
5. Friedman DI, Hu EH, Sadun AA. Neuro-ophthalmic complications of interleukin 2 therapy. *Arch Ophthalmol* 1991;109:1679–1680.
6. Hughes MS, Lessell S. Trazodone-induced palinopsia. *Arch Ophthalmol* 1990;108:399–400.
7. Purvin VA. Visual disturbance secondary to clomiphene citrate. *Arch Ophthalmol* 1995;113:482–484.
8. Kraus RP. Visual "trails" with nefazodone treatment. *Am J Psychiatry* 1996;153:1365–1366.
9. Schwartz K. Nefazodone and visual side effects. *Am J Psychiatry* 1997;154:1038. Letter.
10. Swash M. Visual perseveration in temporal lobe epilepsy. *J Neurol Neurosurg Psychiatry* 1979;42:569–571.
11. Muller T, Buttner T, Kuhn W, Heinz A, Przuntek K. Palinopsia as sensory epileptic phenomenon. *Acta Neurol Scand* 1995;91:433–436.
12. Ogunyemi A, Adams D. Migraine-like symptoms triggered by occipital lobe seizures: response to Sumatriptin. *Can J Neurol Sci* 1998;25:151–153.
13. Young WB, Heros DO, Ehrenberg BL, Hedges TR 3rd. Metamorphopsia and palinopsia. Association with periodic lateralized epileptiform discharges in a patient with malignant astrocytoma. *Arch Neurol* 1989;46:820–822.
14. Lessell S. Higher disorders of visual function: positive phenomena. In: Glaser JS, Smith JL, eds. *Neuro-ophthalmology*. St. Louis: CV Mosby, 1975:27–44.
15. Kinsbourne M, Warrington EK. A study of visual perseveration. *J Neurol Neurosurg Psychiatry* 1963;26:468–475.
16. Ardila A, Botero M, Gomez J. Palinopsia and visual alliesthesia. *Int J Neurosci* 1987;32:775–782.
17. Patterson MC, Bunce IH, Eadie MJ. Cerebral abscess in leukemia: an unusual presentation of a rare complication. *Clin Exp Neurol* 1985;21:257–262.
18. Lunardi P, Tacconi L, Missori P, Salvati M. Palinopsia: unusual presenting symptom of a cerebral abscess in a man with Kartagener's syndrome. *Clin Neurol Neurosurg* 1991;93:337–339.
19. Michel EM, Troost BT. Palinopsia: cerebral localization with CT. *Neurology* 1980;30:887–889.
20. Vaphiades MS, Celesia GG, Brigell MG. Positive spontaneous visual phenomenon limited to the hemianopic field in lesions of central visual pathways. *Neurology* 1996;47:408–417.
21. Bender MB, Feldman M, Sobin AJ. Palinopsia. *Brain* 1968;91:321–338.
22. Holmes G. A contribution to the cortical representation of vision. *Brain* 1931;54:470–479.
23. Kupersmith MJ, Berenstein A, Nelson PK, ApSimon HT, Setton A. Visual symptoms with dural arteriovenous malformations draining into occipital veins. *Neurology* 1999;52:156–162.
24. Purvin VA, Bonnin J, Goodman J. Palinopsia as a presenting manifestation of Creutzfeldt–Jakob disease. *J Clin Neuroophthalmol* 1989;9:242–246.
25. Jacome DE. Palinopsia and bitemporal visual extinction on fixation. *Ann Ophthalmol* 1985;17:251–252.
26. Adler A. Disintegration and restoration of optic recognition in visual agnosia. *Arch Neurol Psychiatry* 1944;51:243–259.
27. Johnson SF, Loge RV. Palinopsia due to nonketotic hyperglycemia. *West J Med* 1988;148:331–332.
28. Klee A, Willanger R. Disturbance of visual perception in migraine. *Acta Neurol Scand* 1966;42:400–414.
29. Marneros A, Korner J. Chronic palinopsia in schizophrenia. *Psychopathology* 1993;26:236–239.
30. Joseph AB. Cotard's syndrome in a patient with coexistent Capgras' syndrome, syndrome of subjective doubles, and palinopsia. *J Clin Psychiatry* 1986;47:605–606.
31. Gates TJ, Stagno SJ, Gullede AD. Palinopsia posing as psychotic depression. *Br J Psychiatry* 1988;153:391–393.
32. Ozsancak C, Auzou P. Palinopsie au cours d'un syndrome de Charles Bonnet. *Presse Med* 1998;27:359. Letter.

Neurology[®]

Palinopsia and polyopia in the absence of drugs or cerebral disease

Howard D. Pomeranz and Simmons Lessell

Neurology 2000;54;855-859

DOI 10.1212/WNL.54.4.855

This information is current as of February 22, 2000

Updated Information & Services	including high resolution figures, can be found at: http://www.neurology.org/content/54/4/855.full.html
References	This article cites 29 articles, 9 of which you can access for free at: http://www.neurology.org/content/54/4/855.full.html#ref-list-1
Citations	This article has been cited by 6 HighWire-hosted articles: http://www.neurology.org/content/54/4/855.full.html#otherarticles
Permissions & Licensing	Information about reproducing this article in parts (figures, tables) or in its entirety can be found online at: http://www.neurology.org/misc/about.xhtml#permissions
Reprints	Information about ordering reprints can be found online: http://www.neurology.org/misc/addir.xhtml#reprintsus

Neurology® is the official journal of the American Academy of Neurology. Published continuously since 1951, it is now a weekly with 48 issues per year. Copyright . All rights reserved. Print ISSN: 0028-3878. Online ISSN: 1526-632X.

