

Bilateral focal motor status epilepticus with retained consciousness after stroke

Article abstract—Bilateral motor seizures with retained consciousness are rare and often mistaken for pseudoseizures. In the few reported cases, the seizures were brief and the underlying lesion usually was a tumor. Here the authors describe a patient with bilateral focal motor status epilepticus with retained consciousness after a stroke. A seizure should be considered as the possible cause of continuous bilateral limb movements with retained consciousness. **Key words:** Bilateral seizures—Retained consciousness—Stroke.

NEUROLOGY 2000;54:976–978

Avi Ashkenazi, MD; Yakir Kaufman, MD; and Tamir Ben-Hur, MD, PhD

Genuine seizures involving both sides of the body without loss of consciousness are rare and often mistaken for pseudoseizures.^{1–3} They have been described with frontal lobe foci, particularly in the supplementary motor area (SMA), usually presenting as bilateral tonic limb movements.⁴ Patients with temporal lobe foci presented as orolimentary automatism with preserved consciousness.⁵ The duration of seizures in the previously reported patients was short, usually less than 2 minutes. A similar presentation with seizures lasting for several hours has not been previously described in adults. Pathologically, most cases were associated with tumors or with developmental abnormalities.

We describe a patient who presented with bilateral focal motor status epilepticus with retained consciousness 9 months after a left hemispheric stroke.

Case report. A 67-year-old woman was admitted to the emergency room because of continuous rhythmic clonic movements of the legs. The movements had started in the right leg several hours before admission and later spread to involve both legs synchronously and continually. Consciousness and sphincteric control were preserved throughout the event, and there were no abnormal vocalizations. The patient had experienced a left hemispheric stroke 9 months earlier and was left with severe right hemiparesis and a motor dysphasia. Her medical history also indicated hypertension, ischemic heart disease, paroxysmal atrial fibrillation, and symptomatic bradycardia, which was treated by a cardiac pacemaker transplantation. She was not on anticoagulant therapy.

On examination, her blood pressure was 170/90, her pulse was 79 and regular, and her temperature was normal. The patient was completely alert and oriented. There was a motor dysphasia, but comprehension was intact; she could obey commands during the event. There was a right central facial paresis. On the Medical Research Council Scale, muscle strength was 0/5 in the right hand, 2/5 in the right leg, and 5/5 on the left side. Pyramidal signs were elicited on the right. Continuous rhythmic clonic move-

ments were observed in the legs, more prominently on the right, and involved both proximal and distal muscles. Blood electrolyte levels were normal. EEG showed continuous rhythmic sharp-wave activity over the left frontal parasagittal area (figure 1A). This spread to the corresponding area on the right in accordance with seizure spread to the left leg (figure 1B). Brain CT showed an old left middle cerebral artery infarction (figure 2). After intravenous administration of diazepam, the seizures stopped promptly and the epileptiform activity on the EEG diminished significantly (figure 1C). Phenytoin was subsequently given with no recurrent seizures.

Discussion. Bilateral motor seizures without impairment of consciousness are rarely documented in the literature^{1,2} and suggest a diagnosis of pseudoseizures.³ Several cortical areas have been implicated in the generation of bilateral seizures, one of which is the SMA.⁴ SMA seizures present most often with brief tonic posturing of the limbs. Additional inconsistent features are versive movements to the contralateral side, speech arrest, or alternatively, abnormal vocalization and a sensory aura. Clonic movements were observed in some patients but not as the dominant manifestation of the seizure. SMA seizures tend to recur many times per day and are relatively resistant to medical treatment. The clinical features of this patient's seizure do not support a diagnosis of SMA seizures.

A different type of bilateral seizure with retained consciousness was described in two patients with brain tumors.¹ Their seizures lasted less than 2 minutes and manifested as bilateral clonic or tonic-clonic movements of the limbs, mimicking grand mal seizures. In one patient, the seizures occasionally involved only the lower limbs, similar to the presentation in our patient. The seizures seemed to involve cortical motor areas bilaterally without spreading more diffusely to areas associated with maintaining consciousness.

Rarely, temporal lobe epilepsy may manifest as bilateral motor seizures with preserved consciousness.⁵ The usual presentation in the reported patients was orolimentary automatism, sometimes accompanied by hand and body rocking movements. Interestingly, all of the documented patients in this group had a focus in the right hemisphere. Indeed,

From the Neurology Department, Hadassah University Hospital, Jerusalem, Israel.

Received June 8, 1999. Accepted in final form October 15, 1999.

Address correspondence and reprint requests to Dr. Avi Ashkenazi, Neurology Department, Hadassah University Hospital, P.O.B. 12000, Ein, Kerem, Jerusalem 91120, Israel.

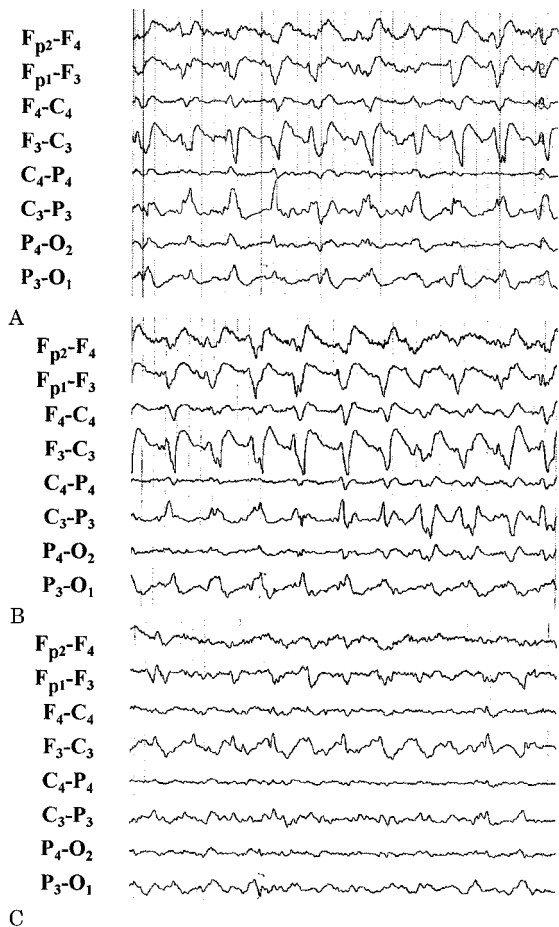


Figure 1. EEG showing focal epileptiform activity over the left frontal parasagittal area (A), which spreads to the contralateral side (B) and diminishes after diazepam administration (C).

preservation of consciousness in patients with automatism was suggested as a lateralizing sign.⁶ Bilateral bicycling movements also were described in temporal lobe epilepsy, but in these patients, consciousness was not preserved.⁷

Our patient presented with bilateral focal motor status epilepticus, which lasted for several hours. This presentation alternatively may be defined as bilateral *epilepsia partialis continua*. *Epilepsia partialis continua* is thought to be a manifestation of a focal epileptic discharge of cortical origin,⁸ and has been associated with various brain insults. Bilateral *epilepsia partialis continua* is rare and has been described anecdotally in children with chronic encephalitis.⁹

The clinical manifestation of bilateral lower limb movements and the EEG findings suggest a focus in the left frontal parasagittal cortex. It is probably in the primary motor area, with spread of activity to the corresponding contralateral area without diffuse involvement of the cortex. Epileptic foci, which develop after a stroke, usually are located close to the infarct margin. In this patient, the focus may have developed in the medial side of the motor strip and

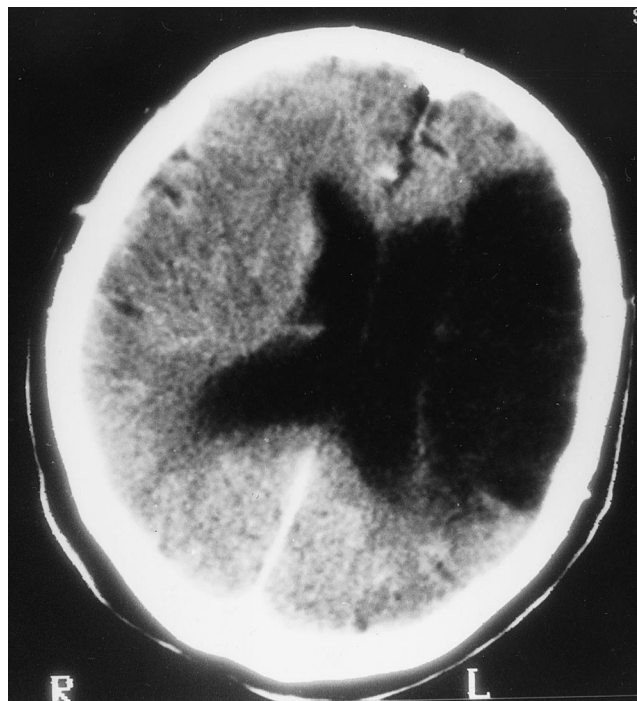


Figure 2. Brain CT scan showing a left middle cerebral artery infarction.

lead to lower limb convulsions. It may be speculated that the large middle cerebral artery infarction blocked seizure propagation to other parts of the left hemisphere while not preventing its spread to the contralateral side.

Although consciousness is a difficult term to define, especially in the setting of epileptic seizures,¹⁰ we assumed that complete alertness and the ability to obey commands during the event were indicators of preserved consciousness in our patient. Conceivably, the epileptic activity in this patient did not spread to areas associated with maintaining consciousness, such as the reticular activating system. It was also limited in its cortical spread so that consciousness was not impaired.

Since a seizure is the possible cause of continuous bilateral limb movements with retained consciousness, prompt treatment with antiepileptic drugs should be given once epileptiform activity is documented on the EEG.

References

- Bell WL, Walczak TS, Shin C, Radtke RA. Painful generalised clonic and tonic-clonic seizures with retained consciousness. *J Neurol Neurosurg Psychiatry* 1997;63:792-795.
- Weinberger J, Lusins J. Simultaneous bilateral focal seizures without loss of consciousness. *Mt Sinai J Med* 1973;40:693-696.
- Luther JS, McNamara JO, Carwile S, Miller P, Hope V. Pseudoepileptic seizures: methods and video analysis to aid diagnosis. *Ann Neurol* 1982;12:458-462.
- Morris HH, Dinner DS, Luders H, Wyllie E, Kramer R. Supplementary motor seizures: clinical and electroencephalographic findings. *Neurology* 1988;38:1075-1082.
- Alarcon G, Elwes RDC, Polkey CE, Binnie CD. Ictal orolimentary automatism with preserved consciousness: implications for the pathophysiology of automatism and relevance to

the international classification of seizures. *Epilepsia* 1998;39:1119–1127.

- Ebner A, Dinner DS, Noachtar S, Luders H. Automatism with preserved responsiveness: a lateralizing sign in psychomotor seizures. *Neurology* 1995;45:61–64.
- Sussman NM, Jackel RA, Kaplan LR, Harner RN. Bicycling movements as a manifestation of complex partial seizures of temporal lobe origin. *Epilepsia* 1989;30:527–531.

- Thomas JE, Reagan TJ, Klass DW. *Epilepsia partialis continua*. A review of 32 cases. *Arch Neurol* 1977;34:266–275.
- Silver K, Andermann F, Meagher-Villemure K. Familial alternating *epilepsia partialis continua* with chronic encephalitis. Another variant of Rasmussen syndrome? *Arch Neurol* 1998;55:733–736.
- Gloor P. Consciousness as a neurological concept in epileptology: a critical review. *Epilepsia* 1986;27(suppl 2):S14–S26.

Amnesic confabulatory syndrome after focal basal forebrain damage

Article abstract—A 73-year-old woman developed amnesic confabulatory syndrome after a right focal basal forebrain hemorrhage. The confabulation, despite persistent anterograde amnesia, gradually subsided with improvement of the frontal executive function. The lesion appeared to disrupt connections of the medial and lateral limbic circuits important for memory. Simultaneous dysfunctioning of the two circuits involving the medial temporal and frontal lobes may be necessary for the development of this syndrome. **Key words:** Basal forebrain—Amnesia—Confabulation—Hemorrhage.

NEUROLOGY 2000;54:978–980

Ritsuo Hashimoto, MD; Yasufumi Tanaka, MD; and Imaharu Nakano, MD

In basal forebrain amnesics, spontaneous confabulation is frequent, particularly in the acute period.¹ The patients reported thus far usually had large lesions involving multiple neuroanatomic areas beyond the basal forebrain,² leaving it unclear whether the basal forebrain lesion alone caused the specific amnesic confabulatory syndrome. We present a patient who exhibited this syndrome after hemorrhage restricted to the right basal forebrain.

Case report. A 73-year-old fully right-handed woman was admitted to our hospital in June 1996 because she had suddenly become forgetful 2 days earlier.

On admission, the patient was alert and had no focal neurologic deficit. During superficial conversation she appeared normal, but a clinical mental examination showed disorientation about the date along with disturbed recent memory. The patient said herself that she was forgetful but did not appear to worry about it.

During her 1-month stay at our hospital, the patient fabricated spontaneously. Much of her confabulation was closely associated with her previous occupation as a telephone operator. In one interview, the patient suddenly got embarrassed and told the examiner, “There’s a young woman waiting in another room whom I should teach how to work as a telephone operator.” On another occasion, she was found wandering around a neurosurgical ward, where she asserted that there should be a telephone office at which she had worked until the day before as an operator. A nurse had to explain many times that the place was a

neurosurgical ward and not a telephone office. Because the patient could correctly state her age, she recognized that she was too old to work and had retired 45 years before.

Neuropsychological assessment. On evaluation, the patient was attentive and cooperative. Her language function was intact. She could repeat five digits forward and four digits backward. Her verbal IQ on the Wechsler Adult Intelligence Scale-Revised (WAIS-R) was 98, and the performance IQ was 96. Her verbal memory quotient on the Wechsler Memory Scale-Revised (WMS-R) (Japanese version) was 72 and that of visual memory was 76. Although her general intelligence was preserved, the patient had anterograde memory disturbance in both verbal and visual materials as determined by the Auditory Verbal Learning Test (AVLT) (Japanese version)³ and the Rey-Osterreith Complex Figure Test (R-O CFT). In the AVLT, she could remember 7 out of 15 presented words in the first trial but did not show any learning effect in consecutive trials. The patient made errors in the first trial, and the same errors frequently appeared in consecutive trials. Immediately after an interference trial with another set of 15 words, she was asked to recall words in the first set. Her responses consisted of some words from the first and second sets of words mixed with some of the errors that she had made in the previous trials. The public event test⁴ and autobiographical memory questionnaire, including questions regarding marriage, deaths of relatives, and birth dates of her children, indicated no evidence of significant retrograde amnesia. As for the frontal lobe function, the patient showed deficits in the New Modified Wisconsin Card Sorting Test⁵ and the Trail making test part B (table).

Neuroimaging study. MRI at 10 days after the stroke showed cerebral hemorrhage confined to the right basal forebrain (figure). According to a standard atlas,⁶ the lesion involved the diagonal band of Broca, septal nuclei, nucleus basalis of Meynert, nucleus accumbens, and preoptic area, and the adjoining white matter. The white matter

From the Department of Neurology, Jichi Medical School, Tochigi, Japan. Received June 7, 1999. Accepted in final form October 15, 1999.

Address correspondence and reprint requests to Dr. Ritsuo Hashimoto, Department of Neurology, Jichi Medical School, 3311-1 Yakushiji, Minami-kawachi, Tochigi 329-0498, Japan.

Neurology[®]

Bilateral focal motor status epilepticus with retained consciousness after stroke

Avi Ashkenazi, Yakir Kaufman and Tamir Ben-Hur

Neurology 2000;54;976-978

DOI 10.1212/WNL.54.4.976

This information is current as of February 22, 2000

Updated Information & Services

including high resolution figures, can be found at:
<http://www.neurology.org/content/54/4/976.full.html>

References

This article cites 9 articles, 3 of which you can access for free at:
<http://www.neurology.org/content/54/4/976.full.html#ref-list-1>

Permissions & Licensing

Information about reproducing this article in parts (figures, tables) or in its entirety can be found online at:
<http://www.neurology.org/misc/about.xhtml#permissions>

Reprints

Information about ordering reprints can be found online:
<http://www.neurology.org/misc/addir.xhtml#reprintsus>

Neurology® is the official journal of the American Academy of Neurology. Published continuously since 1951, it is now a weekly with 48 issues per year. Copyright . All rights reserved. Print ISSN: 0028-3878. Online ISSN: 1526-632X.

