

Clinical Research

Planned Ictal FDG PET Imaging for Localization of Extratemporal Epileptic Foci

*†Carolyn Cidis Meltzer, †§P. David Adelson, †‡Richard P. Brenner, ¶Patricia K. Crumrine, ‡Anne Van Cott, §David P. Schiff, *David W. Townsend, and ‡Mark L. Scheuer

Departments of *Radiology, †Psychiatry, ‡Neurology, and §Neurological Surgery, University of Pittsburgh; and Departments of †Neurosurgery and ¶Neurology, Children's Hospital of Pittsburgh, Pittsburgh, Pennsylvania, U.S.A.

Summary: *Purpose:* This work demonstrates the feasibility of planned ictal positron emission tomography (PET) with [¹⁸F]fluoro-2-deoxy-glucose (FDG) for localization of epileptic activity in patients with frequent partial seizures of extratemporal origin.

Methods: Ictal PET imaging was performed in four patients (two men and two women, ages 28–61) with continuous or very frequent (every 3–15 min) partial seizures. All patients had abnormalities apparent on magnetic resonance (MR) or computed tomographic (CT) imaging, two with extensive brain lesions that precluded precise localization of the seizure focus with interictal PET or single-photon emission tomography (SPECT) imaging.

Results: Ictal PET imaging demonstrated a restricted area of focal hypermetabolism concordant with surface electroencephalographic (EEG) recording in all cases. The PET images were registered to MR imaging data for further anatomic localization of hypermetabolic regions in three cases. The ictal PET data were used to guide neurosurgical intervention in one case.

Conclusions: We conclude that planned ictal PET imaging may be a useful and potentially superior approach to ictal SPECT for identifying the epileptic focus in a selected group of patients with continuous or frequent simple partial seizures.
Key Words: Epilepsy—Emission tomography—Magnetic resonance imaging—Brain metabolism—Neurosurgery.

Positron emission tomography (PET) imaging with [¹⁸F]fluoro-2-deoxy-glucose (FDG) has been used extensively in the presurgical evaluation of patients with intractable partial complex epilepsy, with interictal hypometabolism a useful adjunct to electroencephalography (EEG) data and anatomic imaging for seizure lateralization (1–3). However, the extent of the hypometabolism may be substantially larger than the electrical focus (4). Further, the relation between the area of hypometabolism and the extent of surgical resection needed for seizure control—particularly in extratemporal foci—has not been clearly defined (5).

Additional localizing information has been obtained through ictal imaging by using single-photon emission tomography (SPECT) and ^{99m}Tc-hexamethylpropyleneamine oxime (HMPAO). This is feasible because of the longer tracer half-life of technetium-based agents.

However, some early reports of ictal SPECT suffered from a prolonged delay between seizure onset and tracer injection (6,7). Recent methodologic enhancement of ictal SPECT studies suggests improvements in seizure localization, with a potential complementary role between ictal and interictal imaging (8,9). A careful comparison of ictal SPECT and interictal PET in 35 patients with temporal lobe epilepsy supported a high sensitivity for both approaches and further suggested a role for performing ictal and interictal imaging studies in cases in which localization was particularly difficult (8). Of note, the sensitivity of multiple imaging and clinical modalities targeted at seizure localization may be lower for extratemporal than for temporal foci (10).

Disadvantages of SPECT include poorer spatial resolution relative to PET, and lower sensitivity of blood flow for seizure localization compared with metabolic data (6,11,12). Ictal imaging with PET has been primarily limited to a few reports of the serendipitous acquisition of ictal PET data in cases in which the patient experienced a seizure during the period of FDG uptake (1,13–15). Planned ictal FDG PET imaging of patients

Accepted August 5, 1999.

Address correspondence and reprint requests to Dr. C. C. Meltzer at PET Facility, B-938, University of Pittsburgh Medical Center, 200 Lothrop Street, Pittsburgh, PA 15213-2582, U.S.A. E-mail: meltzer@radserv.arad.upmc.edu

with frequent or continuous partial seizures may offer a unique opportunity to study the metabolic pattern of the brain during ictal events. This may be especially important in patients with extensive underlying structural brain abnormalities in whom both routine morphologic and interictal functional imaging may not sufficiently localize the epileptogenic tissue for surgical planning.

We report marked focal hypermetabolism in four planned ictal FDG PET studies performed in patients with frequent or continuous partial seizures. In one patient, ictal PET imaging was used to guide surgical resection.

SUBJECTS AND METHODS

PET data were acquired on an ECAT ART, 951R/31 or HR+ tomograph (CTI PET Systems, Knoxville, TN, U.S.A.). Seven to 10-mCi FDG was injected intravenously, and emission scanning was performed for 30 min beginning ~45 min after FDG injection. For ictal studies, FDG was administered while the patient was in the Epilepsy Monitoring Unit under continuous clinical and EEG surveillance within 31–40 s of the onset of a seizure as determined by EEG (cases 1–3). In one patient, EEG monitoring was not performed during the ictal study as the patient was having *epilepsia partialis continua* (EPC). In two patients, follow-up interictal PET imaging was performed several weeks after initiation of partially effective medical treatment (case 3) and surgery (case 4). A thermoplastic face mask and head-holder system was used to minimize head movement. The FDG PET data were reconstructed with a Hanning window, corrected for attenuation by a measured transmission scan, and summed. Arterial blood sampling was not performed because of unknown accuracy of absolute quantitation in seizures, including the uncertainty of the appropriate value for the lumped constant and lack of a steady state (16). Thus the summed FDG PET images were visually evaluated by an experienced nuclear medicine physician for the presence of focal or diffuse areas of asymmetrically increased or decreased tracer uptake. The reader was not blinded to other clinical information.

When available, MR images were co-registered to the PET data by using automated image registration (AIR) (17).

Case 1

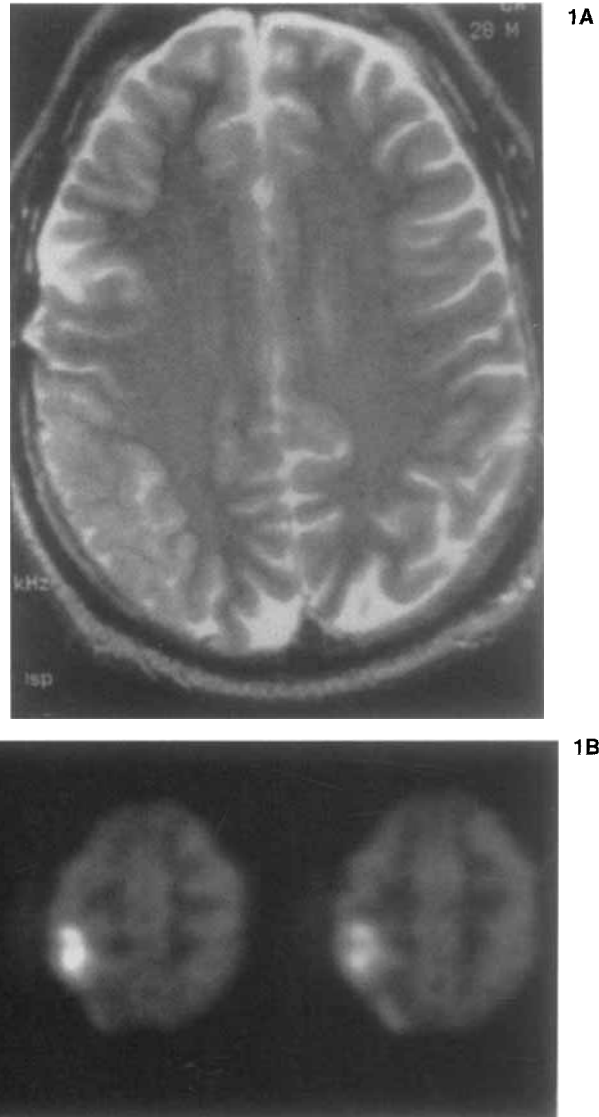
A 28-year-old left-handed man was in good health until 1986, when at age 18, he was involved in a motor vehicle accident resulting in a head injury complicated by a right parietal subdural hematoma. The hematoma was surgically evacuated. Frequent stereotyped seizures began shortly thereafter, characterized by an initial non-specific cephalic sensation, followed by tingling in the fingers of his left hand. Therapy included multiple trials of antiepileptic medications (AEDs), including phenyt-

oin (PHT), phenobarbital (PB), carbamazepine (CBZ), valproic acid (VPA), and gabapentin (GBP), with only limited seizure control. In early August 1996, the frequency of left-hand focal seizures increased to several per day, and subsequently after hospitalization, the patient was in simple partial status epilepticus with seizure frequency having increased to six to 12 per hour. With some seizures, in addition to parathesias of the left arm, the patient was also dysphasic and had a left visual field defect. An MR examination demonstrated postsurgical changes in the right temporal region and cortical thickening and mild T₂ hyperintensity in the right parietal lobe (Fig. 1A). Scalp EEG monitoring revealed frequent electrographic seizures with rhythmic beta activity in the right central or right central and central vertex regions, with subsequent spread of rhythmic ictal patterns to the right parietal, right posterior temporal, and variably to the right frontal regions, usually accompanied by clinical changes noted earlier. An ictal PET study was performed with injection of 10 mCi FDG 36 s after the onset of a seizure, as recorded by EEG. The seizure lasted an additional 6 min and 44 s and was followed by another seizure 13 min later, which lasted 4 min and 18 s. The PET study demonstrated a focal area of markedly increased FDG uptake in the right parietal convexity (Fig. 1B). MR-PET registration further localized this hypermetabolic focus to the area of the postcentral gyrus. Elevated contralateral cerebellar hemisphere FDG uptake also was noted. Attempts were made to control seizures with increasing doses of VPA and CBZ. Acetazolamide (AZM) and intravenous PB were later initiated with a rapid response. Repeated MR imaging was performed 2 months after the initial study and demonstrated resolution of the right parietal cortical thickening and signal abnormality (Fig. 1C).

Case 2

This 44-year-old right-handed woman had a long history of seizures and a large right temporal lobe arteriovenous malformation (AVM) treated with embolization 15 years earlier with resulting left hemiparesis. After a reduction of her AEDs, she developed partial seizures with secondary generalization that remained refractory to multiple medications. The patient was then admitted for inpatient evaluation of increased seizure activity. Physical and neurologic examination was remarkable for left arm and leg hemiatrophy and paresis and absent facial weakness. Increased tone with hyperreflexia in the left arm and leg were also present. Sensory deficits included decreased sensation to pin prick, extinction to double simultaneous stimulation, and astereognosis on the left. Prolonged EEG monitoring revealed frequent simple partial seizures occurring with a frequency of approximately one every 5 min, with ictal discharge typically confined to the C4 and F4 electrodes, occasionally

FIG. 1. Case 1. **A:** T2-weighted axial magnetic resonance (MR) image demonstrates mild cortical hyperintensity and gyral thickening in the right parietal lobe. **B:** Multiple axial ictal positron emission tomography (PET) images demonstrate a focal area of markedly increased fluorodeoxyglucose (FDG) uptake in the right parietal convexity, corresponding to the MR abnormality.



spreading to the left central head region. The clinical correlate of these discharges was left-hand paresthesias. An MR examination demonstrated a very large AVM centered in the right basal ganglia but involving much of the right hemisphere with feeding vessels arising from both anterior and posterior circulation and superficial and deep venous drainage (Fig. 2). Multiple foci of embolization material and areas of encephalomalacia were consistent with prior infarction. Because it was thought that a routine interictal PET study would likely show large areas of hypometabolism in the right hemisphere and thus be relatively unhelpful for localizing the seizure focus, an ictal PET study was performed.

The FDG injection was given 31 s after the onset of a seizure, which lasted an additional 18 s. Her next seizure occurred 2 min and 28 s later, and she continued to have repetitive (every 3–6 min) brief (30–60 s) seizures throughout the study. The ictal PET scan demonstrated

extensive hypometabolism throughout much of the right hemisphere, corresponding to the large AVM, embolization, and prior associated infarction; contralateral cerebellar hypometabolism also was noted (Fig. 2). A focal area of marked hypermetabolism was present in the right cerebral convexity. Registration of the ictal PET images to the patient's MR image data further localized the hypermetabolic focus to the motor cortex area and demonstrated its close proximity to a large draining vein. As a result of this finding, surgery was not recommended. The patient responded favorably to treatment with intravenous PHT and PB.

Case 3

This 61-year-old man had a history of a left middle cerebral artery stroke 5 years earlier with residual aphasia, and a heart transplant performed for congestive heart failure 3 years before presentation. The patient had been

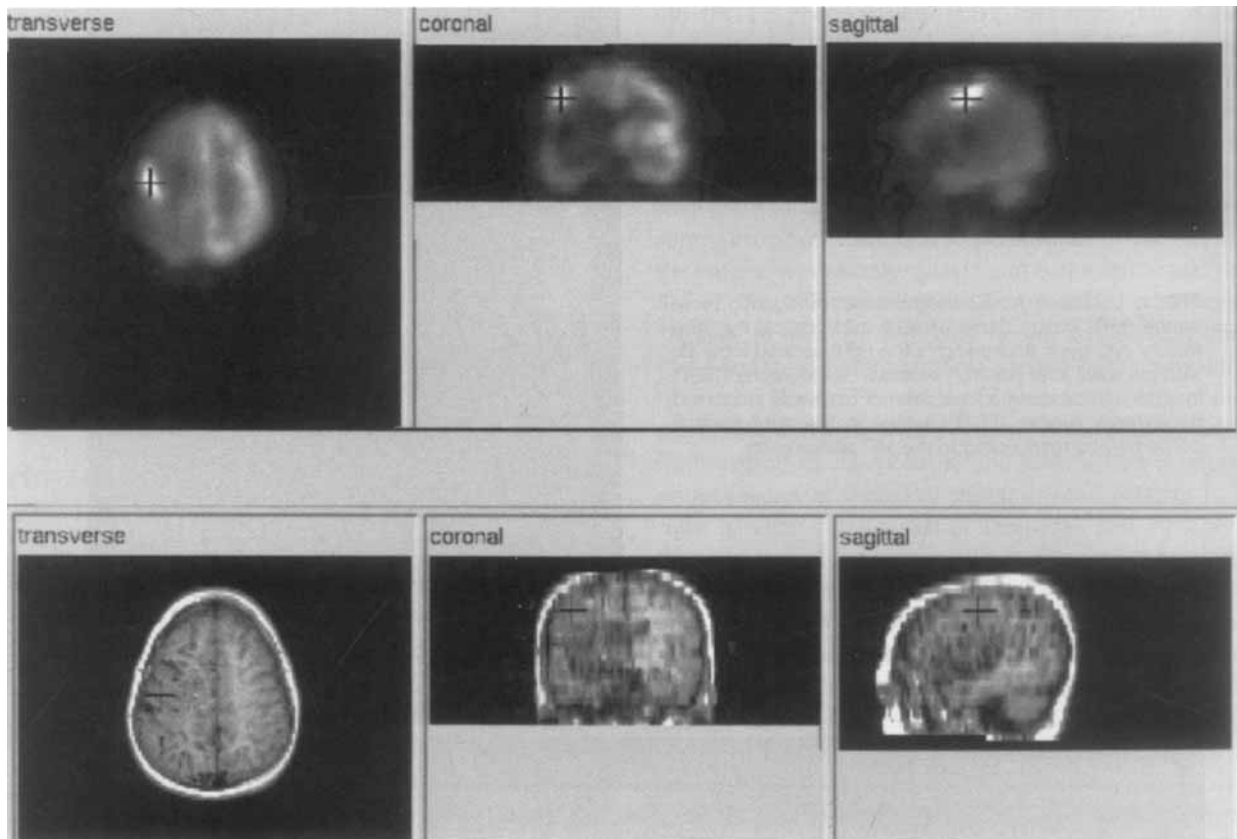


FIG. 2. Case 2. Co-registered ictal positron emission tomography (PET) (above) and T₁-weighted magnetic resonance (MR) (below) imaging studies. Diffuse right-hemisphere hypometabolism is present. The crosshair indicates the position of a focal area of marked hypermetabolism at the right cerebral convexity on the ictal PET image in the transverse, coronal, and sagittal planes. The corresponding location on the MR image relative to the extensive flow voids of a diffuse large right-hemisphere arteriovenous malformation (AVM) also is demonstrated.

maintained on multiple AEDs for partial-onset seizures that began after his transplant. Before admission, he developed recurrent paroxysmal episodes of right visual hemifield illusions and worsening of language function. These episodes progressively increased in frequency to one approximately every 5–10 min. Scalp EEG recordings demonstrated evolving rhythmic left temporooccipital ictal patterns during the visual illusions. An ictal PET scan was performed with injection of FDG 40 s after the start of a seizure as determined by EEG. The seizure lasted an additional 18 s. The next seizure occurred 3 min and 13 s later, and he continued to have repetitive seizures lasting 1 min every 4–5 min throughout the study. This study demonstrated a large area of markedly increased FDG uptake in the left inferior and posterior temporal lobe and occipital cortex, bordering the large hypometabolic area corresponding to the patient's prior left middle cerebral artery infarction (Fig. 3A and B). The patient's seizures gradually decreased in frequency after treatment with multiple AEDs, and his language function improved over the course of 3 weeks. A repeat PET scan demonstrated significant resolution of the hypermetabolic changes seen on the initial examination,

with only mildly elevated FDG uptake in the left temporooccipital region (Fig. 3B). The patient's epilepsy remains controlled with PHT and GBP.

Case 4

A previously healthy 48-year-old woman had a syncopal episode. Initial brain MR imaging was normal. She then developed focal motor seizures involving her left hemibody, some progressing to involve bilateral clonic activity. Repeated MR imaging 1 month later demonstrated a focal signal abnormality involving the bilateral medial frontal lobes including motor cortex, more prominently on the right than the left (Fig. 4A). The lesion was nonenhancing and spared the corpus callosum; there was no significant associated mass effect. The patient underwent a computed tomography (CT)-guided stereotactic biopsy leading to a diagnosis of low-grade astrocytoma. Fractionated external beam radiotherapy was initiated, and the patient's seizures transiently decreased in frequency, with corresponding resolution of the imaging abnormality over the course of 6 weeks.

Seizures were well controlled with medication until 5 months after presentation, when the patient developed

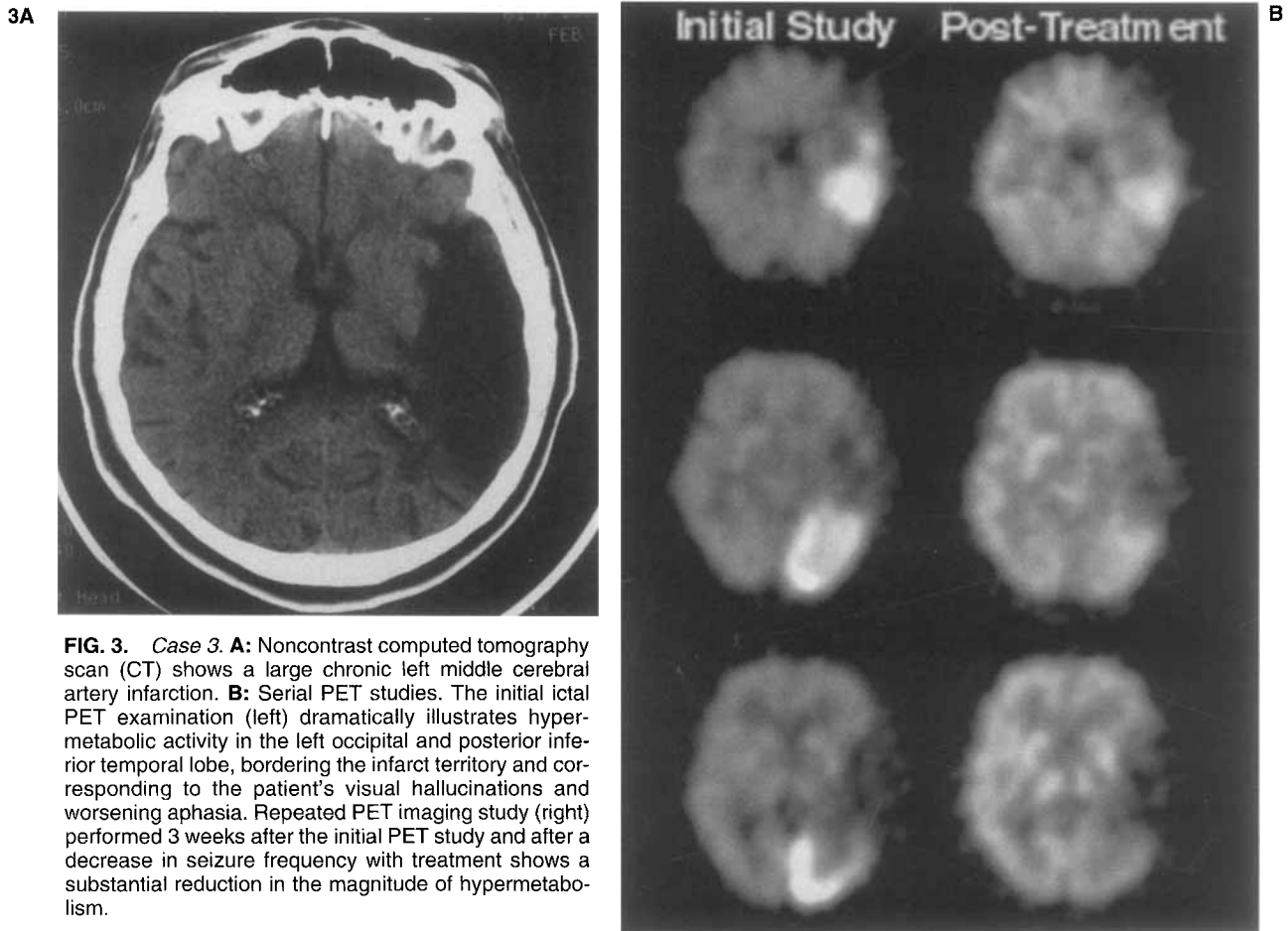


FIG. 3. Case 3. **A:** Noncontrast computed tomography scan (CT) shows a large chronic left middle cerebral artery infarction. **B:** Serial PET studies. The initial ictal PET examination (left) dramatically illustrates hypermetabolic activity in the left occipital and posterior inferior temporal lobe, bordering the infarct territory and corresponding to the patient's visual hallucinations and worsening aphasia. Repeated PET imaging study (right) performed 3 weeks after the initial PET study and after a decrease in seizure frequency with treatment shows a substantial reduction in the magnitude of hypermetabolism.

frequent partial-onset seizures. Attempts to control seizures with high doses of combination AEDs were unsuccessful. As a result, she was in an obtunded, bed-bound state due to both the dose-related toxicities of her medications and continuous seizure activity. MR imaging demonstrated partial reappearance of the bilateral medial frontal signal abnormalities that had resolved on the prior scan 10 weeks earlier; signal changes on this follow-up examination involved predominantly the right hemisphere (Fig. 4B). An ictal PET scan was performed with the patient's typical seizures occurring immediately after FDG injection and persisting during the FDG-uptake phase but without EEG monitoring, and registered to the MR images. This demonstrated focal hypermetabolism in the region of the right motor cortex with limited left hemisphere extension (Fig. 4B). The patient underwent cortical excision of the area delineated by the hypermetabolic PET, which encompassed the posterior medial frontal lobe, and specifically, the supplementary motor and precentral areas and anterior cingulate on the right. A postoperative interictal PET study demonstrated a hypometabolic surgical defect. Histopathologic examination of the cortical tissue specimen demonstrated hypercellularity but did not confirm the diagnosis of neoplasm.

Polymerase chain reaction (PCR) for herpes virus was negative. Postoperatively, the patient initially experienced several seizures, but these quickly resolved. A dense left hemiparesis, leg greater than arm, responded to rehabilitation therapy, and the patient regained ambulation and significant hand strength. The patient has been maintained with CBZ and has remained seizure free for the past 18 months.

DISCUSSION

This case series demonstrates the feasibility of performing ictal PET imaging in selected patients with frequent partial seizures. Interictal PET imaging with FDG is routinely used as an adjunct to EEG and MR imaging for seizure lateralization in the presurgical evaluation of intractable partial complex epilepsy (18–20). However, the relation between the extent of hypometabolism and the optimal resection area remains undefined. Further, interictal PET images are of limited utility for precisely localizing the seizure focus in patients with large areas of metabolically abnormal brain tissue or prior surgery. In this series, ictal PET imaging offered unique localizing information in the cases presented. In two patients (cases

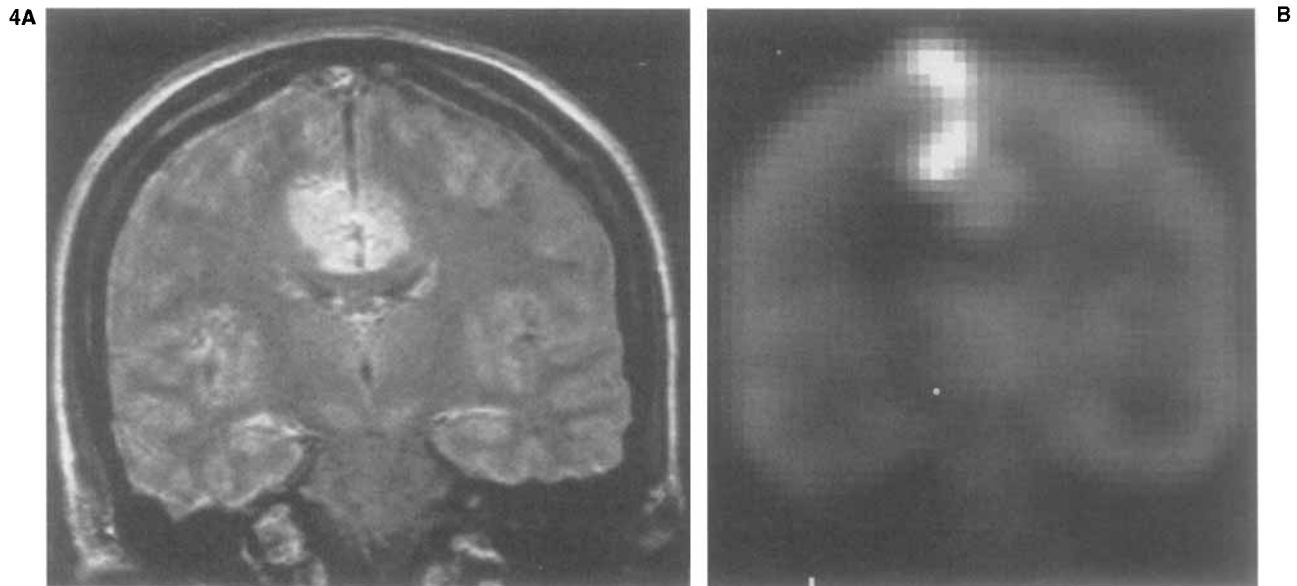


FIG. 4. Case 4. **A:** Proton density-weighted coronal magnetic resonance (MR) image illustrates the bilateral medial frontal lobe signal abnormality and associated mild mass effect. **B:** Coronal ictal positron emission tomography (PET) image shows corresponding focal hypermetabolism predominantly involving the region of the right motor cortex with mild hypermetabolism extending to the left hemisphere.

2 and 3) in whom large areas of abnormal brain tissue would have confounded the interpretation of interictal PET imaging, this information was especially valuable. In one case (case 4), the ictal PET study demonstrated the functional abnormality, which on excision rendered the patient seizure free.

Functional imaging with PET and SPECT has been widely used for presurgical planning of intractable epilepsy. Although SPECT is more widely available, comparison interictal studies have shown PET imaging to be more effective for seizure localization (6,12,21–23). The growing use of ictal SPECT imaging has demonstrated that functional imaging of the ictal state may offer additional localizing information relative to interictal PET or SPECT. PET studies of epilepsy have been routinely restricted to the interictal state, primarily because of the short half-lives of PET radiotracers, which makes it impractical to plan ictal examinations in patients with infrequent seizures or unpredictable seizure patterns. However, in patients with very frequent seizures, ictal PET imaging is possible. Its advantages over SPECT include superior spatial resolution, and the potential advantage of metabolic rather than blood-flow imaging (11). Based on animal seizure models, uncoupling of perfusion and glucose metabolism may occur in the ictal and early post-ictal states, resulting in increases in glucose utilization that are not accompanied by corresponding increases in blood flow (24,25). The availability of accurate approaches to MR-PET imaging registration (17,26) may be especially helpful in providing precise anatomic localization of functional abnormalities necessary to guide surgical planning.

Reports of PET studies performed in patients who

have experienced seizures during the FDG-uptake phase have demonstrated various patterns of predominant hypermetabolic activity. Theodore et al. (1) observed focal increases in FDG uptake that corresponded to hypometabolic areas on the interictal scans in three patients whose seizures began shortly after FDG injection. Engel et al. (13), however, found that the pattern of ictal hypermetabolism did not necessarily correspond to that of interictal hypometabolism and may represent an individualized signature of seizure initiation and spread. The magnitude of ictal hypermetabolism reported has varied from mild to marked (1,11,13,27), possibly reflecting differences among studies in the length of time between FDG injection and start of the seizure. Increases in brain tissue glucose utilization of $\leq 600\%$ have been reported in association with seizures (13), suggesting that the sensitivity of detecting focal metabolic changes in ictus may be higher than that with interictal PET imaging. Further, the sensitivity of detecting hypometabolic foci in interictal PET imaging may be adversely affected by factors that may diffusely depress brain glucose utilization, such as AEDs or sedation (1).

A pattern of cerebellar “diaschisis” was observed in two of the four cases. The finding of a crossed functional connection between the cerebral hemispheres and the cerebellum was originally described in patients with stroke in whom cerebellar hypometabolism was observed contralateral to an infarct. A pattern of crossed cerebellar hypermetabolism (sometimes also referred to as diaschisis) has been previously noted on FDG PET scans performed in patients who experienced a seizure during tracer uptake (14). In one case (case 1), we also noted elevated tracer uptake in the cerebellar hemisphere

contralateral to the seizure focus. However, in case 2, contralateral cerebellar hypometabolism was likely a reflection of the large extent of hypometabolism in the involved hemisphere in this patient with a diffuse, previously embolized AVM. Because of relatively greater functional connectivity between frontal brain regions and cerebellum, contralateral cerebellar metabolic effects may be more frequently encountered in ictal studies of frontal rather than temporal lobe epilepsy (28).

Ictal FDG PET imaging may produce variable results in some clinical settings. In one report, six of >200 epilepsy patients undergoing PET imaging for seizure localization experienced seizures during the FDG-uptake phase, none of whom demonstrated hypermetabolism (15). This is likely due to the long interval of 5–20 min between FDG injection and seizure onset. Because the initial uptake of FDG in brain tissue is rapid (with 24% gray matter FDG in the phosphorylated or “fixed” form by 5 min after injection) (16), it is not surprising that hypermetabolism was not observed in these cases. However, in a case of EPC, both PET and HMPAO SPECT showed similar patterns of reduced unilateral frontal tracer uptake (29). This was attributed to a small seizure focus (not visualized because of limitations of spatial resolution) with a large surround of depressed cortical metabolism. Because of the limited temporal resolution of FDG, the perhaps heightened potential for misleading localization due to late propagation of seizure activity should be considered in a planned ictal imaging study.

All of these cases experienced multiple seizures or EPC during the early FDG uptake phase, which may be optimal conditions for producing a pattern of localized hypermetabolism corresponding to the seizure focus. The sensitivity of ictal PET imaging is not known for single, brief seizures and may be limited. Indeed, “normalization” of scan findings due to averaging of interictal and ictal metabolic effects may be seen in this setting, or alternatively when a seizure occurs later than the first few minutes after FDG injection.

We have demonstrated the potential clinical utility, particularly for surgical planning, of ictal PET imaging for the evaluation of patients with frequent partial seizures. Localization of a restricted focus of hypermetabolism in this setting may guide therapy and potentially offer unique functional information, particularly in patients with extensive morphologic brain abnormalities that may limit interpretation of routine imaging studies. Because all four cases in our series had clear semiology and EEG localizing information, future evaluations should include patients with unknown seizure origin and long-term postoperative follow-up data to define further the role of ictal imaging in epilepsy. A direct comparison between ictal FDG PET and ictal SPECT imaging also is warranted to assess the relative practical value of ictal imaging techniques.

Acknowledgment: We thank Marsha Dachille, Donna Milko, James Rusckiewicz, Denise Ratica, and Cheryl Plummer for their assistance in performing the PET studies described in the manuscript.

REFERENCES

- Theodore W, Newmark M, Sato S, et al. [¹⁸F]Fluorodeoxyglucose positron emission tomography in refractory complex partial seizures. *Ann Neurol* 1983;14:429–37.
- Mazziotta J, Engel JJ. The use and impact of positron computed tomography scanning in epilepsy. *Epilepsia* 1984;25(suppl2):S86–104.
- Pawlik G, Holthoff V, Kessler J, et al. Positron emission tomography findings relevant to neurosurgery for epilepsy. *Acta Neurochir* 1990;suppl 50:84–7.
- Swartz B, Tomiyasu U, Delgado-Escueta A, Mendelkern M, Khonsari A. Neuroimaging in temporal lobe epilepsy: test sensitivity and relationships to pathology. *Epilepsia* 1992;33:624–34.
- Henry T. Functional neuroimaging with positron emission tomography. *Epilepsia* 1996;37:1141–54.
- Mastin S, Drane W, Gilmore R, et al. Prospective localization of epileptogenic foci: comparison of PET and SPECT with site of surgery and clinical outcome. *Radiology* 1996;199:375–80.
- Zubal I, Spencer S, Imam K, et al. Difference images calculated from ictal and interictal technetium-99m-HMPAO SPECT scans of epilepsy. *J Nucl Med* 1995;36:684–9.
- Ho S, Berkovic S, Berlangieri S, et al. Comparison of ictal SPECT and interictal PET in the presurgical evaluation of temporal lobe epilepsy. *Ann Neurol* 1995;37:738–45.
- Otsubo H, Hwang PA, Gilday DL, Hoffman HJ. Location of epileptic foci on interictal and immediate postictal single photon emission tomography in children with localization-related epilepsy. *J Child Neurol* 1995;10:375–81.
- Zentner J, Hufnagel A, Ostertun B, et al. Surgical treatment of extratemporal epilepsy: clinical, radiologic, and histopathologic findings in 60 patients. *Epilepsia* 1996;37:1072–80.
- Kuhl D, Engel J, Phelps M, Selin C. Epileptic patterns of local cerebral metabolism and perfusion in humans determined by emission computed tomography of ¹⁸F-FDG and ¹³NH₃. *Ann Neurol* 1980;8:348–60.
- Meltzer C, Jadali F, Mintun M, et al. Comparison of FDG PET, SPECT, and MRI in pediatric epilepsy. *J Nucl Med* 1996;37:269P–70P.
- Engel J, Kuhl D, Phelps M. Patterns of human local cerebral glucose metabolism during epileptic seizures. *Science* 1982;218:64–6.
- Chugani H, Rintahaka P, Shewmon D. Ictal patterns of cerebral glucose utilization in children with epilepsy. *Epilepsia* 1994;35:813–22.
- Barrington S, Koutroumanidis M, Agathonikou A, et al. Clinical value of “ictal” FDG-positron emission tomography and the routine use of simultaneous scalp EEG studies in patients with intractable partial epilepsies. *Epilepsia* 1998;39:753–66.
- Phelps M, Huang S, Hoffman E, Selin C, Sokoloff L, Kuhl D. Tomographic measurement of local cerebral glucose metabolic rate in humans with (F-18)2-fluoro-2-deoxy-D-glucose: validation of method. *Ann Neurol* 1979;6:371–88.
- Woods RP, Mazziotta JC, Cherry SR. MRI-PET registration with automated algorithm. *J Comput Assist Tomogr* 1993;17:536–46.
- Chugani H. PET in preoperative evaluation of intractable epilepsy. *Pediatr Neurol* 1993;9:411–3.
- Engel J. PET scanning in partial epilepsy. *Can J Neurol Sci* 1991;18:588–92.
- Henry T, Engel J, Mazziotta J. Clinical evaluation of interictal fluorine-18-fluorodeoxyglucose PET in partial epilepsy. *J Nucl Med* 1993;34:1892–8.
- Stefan H, Pawlik G, Bocher-Schwarz H, et al. Functional and morphological abnormalities in temporal lobe epilepsy: a comparison of interictal and ictal EEG, CT, MRI, SPECT, and PET. *J Neurol* 1987;234:377–84.
- Lamusuo S, Ruottinen HM, Knuuti J, et al. Comparison of [¹⁸F]FDG-PET, [^{99m}Tc]-HMPAO-SPECT, and [¹²³I]-iomazenil-

- SPECT in localising the epileptogenic cortex. *J Neurol Neurosurg Psychiatry* 1997;63:743–8.
23. Nagata T, Tanaka F, Yonekura Y, et al. Limited value of interictal brain perfusion SPECT for detection of epileptic foci: high resolution SPECT studies in comparison with FDG-PET. *Ann Nucl Med* 1995;9:59–63.
 24. Hosokawa C, Ochi H, Yamagami S, Yamada R. Regional cerebral blood flow and glucose utilization in spontaneously epileptic EL mice. *J Nucl Med* 1997;38:613–6.
 25. Gaillard WD, Fazilat S, White S, et al. Interictal metabolism and blood flow are uncoupled in temporal lobe cortex of patients with complex partial epilepsy. *Neurology* 1995;45:1841–7.
 26. Strother S, Anderson J, Xu X-L, Liow J, Bonar D, Rottenberg D. Quantitative comparisons of image registration techniques based on high-resolution of MRI of the brain. *J Comput Assist Tomogr* 1994;18:954–62.
 27. Collins R, Kennedy C, Sokoloff L, Plum F. Metabolic anatomy of focal seizures. *Arch Neurol* 1976;33:536–42.
 28. Savic I, Altshuler L, Passaro E, Baxter L, Engel J Jr. Localized cerebellar hypometabolism in patients with complex partial seizures. *Epilepsia* 1996;37:781–7.
 29. Noachter S, Ebner A, Witte O, Seitz R. Palatal tremor of cortical origin presenting as epilepsy partialis continua. *Epilepsia* 1995;36:207–9.