

This is a repository copy of *Knowing no fear*.

White Rose Research Online URL for this paper:

<https://eprints.whiterose.ac.uk/1321/>

Article:

Sprenghelmeyer, R, Young, AW orcid.org/0000-0002-1202-6297, Schroeder, U et al. (4 more authors) (1999) *Knowing no fear*. *Proceedings of the Royal Society B: Biological Sciences*. pp. 2451-2456. ISSN 1471-2954

<https://doi.org/10.1098/rspb.1999.0945>

Reuse

Items deposited in White Rose Research Online are protected by copyright, with all rights reserved unless indicated otherwise. They may be downloaded and/or printed for private study, or other acts as permitted by national copyright laws. The publisher or other rights holders may allow further reproduction and re-use of the full text version. This is indicated by the licence information on the White Rose Research Online record for the item.

Takedown

If you consider content in White Rose Research Online to be in breach of UK law, please notify us by emailing eprints@whiterose.ac.uk including the URL of the record and the reason for the withdrawal request.

Knowing no fear

Reiner Sprengelmeyer^{1*}, Andrew W. Young², Ulrike Schroeder¹,
Peter G. Grossenbacher³, Jens Federlein¹, Thomas Büttner¹ and Horst Przuntek¹

¹Neurologische Klinik, Ruhr-Universität Bochum, Gudrunstrasse 56, D-44791 Bochum, Germany

²Department of Psychology, University of York, Heslington, York YO10 5DD, UK

³National Institute of Mental Health, Bethesda, MD 20892-2668, USA

People with brain injuries involving the amygdala are often poor at recognizing facial expressions of fear, but the extent to which this impairment compromises other signals of the emotion of fear has not been clearly established. We investigated N.M., a person with bilateral amygdala damage and a left thalamic lesion, who was impaired at recognizing fear from facial expressions. N.M. showed an equivalent deficit affecting fear recognition from body postures and emotional sounds. His deficit of fear recognition was not linked to evidence of any problem in recognizing anger (a common feature in other reports), but for his everyday experience of emotion N.M. reported reduced anger and fear compared with neurologically normal controls. These findings show a specific deficit compromising the recognition of the emotion of fear from a wide range of social signals, and suggest a possible relationship of this type of impairment with alterations of emotional experience.

Keywords: amygdala; facial expression; emotion recognition; basic emotions; fear

1. INTRODUCTION

Neuropsychological studies have shown that people with brain injuries involving the amygdala are often poor at recognizing facial expressions of fear (Adolphs *et al.* 1994, 1995, 1999a; Broks *et al.* 1998; Calder *et al.* 1996; Weniger *et al.* 1997). The importance of the amygdala for recognizing fear has also been demonstrated by functional imaging studies showing an amygdala response to fearful facial expressions (Breiter *et al.* 1996; Morris *et al.* 1996, 1998; Phillips *et al.* 1997; Whalen *et al.* 1998).

The neuropsychological findings often show differentially severe impairment of fear recognition after amygdala damage, but it is seldom only fear that is affected. Most studies report some degree of impaired recognition of other negative emotions, of which deficits in recognizing anger are the most consistently noted (Adolphs *et al.* 1994, 1995, 1999a,b; Calder *et al.* 1996).

These findings indicate that the amygdala is involved in recognizing fear, but the extent to which this involvement is restricted to facial expressions of fear or applies to other social signals of the emotion of fear has not been clearly established, since most studies have only involved facial expressions. In functional imaging research, the single published study which has investigated vocal as well as facial expressions found that the amygdala also responded to fearful sounds (screams, etc.) (Phillips *et al.* 1998). In neuropsychological research, only two individuals with impaired recognition of facial expressions of fear following amygdala damage have also been tested for their recognition of vocal expressions; one of these had

parallel impairments of facial and vocal recognition (Scott *et al.* 1997), but the other was able to recognize vocal expressions (Anderson & Phelps 1998).

We report here the results of detailed investigation of the recognition of emotion by a person (N.M.) with a differentially severe impairment of recognition of fear from facial expressions. The question addressed was whether someone who is poor at recognizing facial expressions of fear would show an equivalent deficit affecting other visual and auditory signals of the same emotion. In addition to studying N.M.'s recognition of facial expressions, we investigated the recognition of emotion from non-facial visual signals by using body postures, and from the auditory modality by using emotional sounds (screams, laughter, etc.). N.M.'s experience of negative emotions was also assessed using standard questionnaires.

2. CASE DESCRIPTION

N.M. is a 50-year-old right-handed male with no previous history of treatment for neurological or psychiatric disorders. He has been employed with a large German company as a salesman, working for the last few years mainly in China. On a long-distance flight in April 1999, he suddenly experienced difficulties in coordinating movements of his right leg, leading to gait abnormalities. He also had mild motor disturbances and paraesthesia of the right hand and forearm. In addition, he reported a mild form of dysarthria (slurred speech). However, from his reports there was no indication of deficits in cognitive functioning. Three days later, he returned to Germany without recovery of symptoms and was referred on the same day to the university neurological clinic in Bochum.

*Author for correspondence (reiner.sprengelmeyer@ruhr-uni-bochum.de).

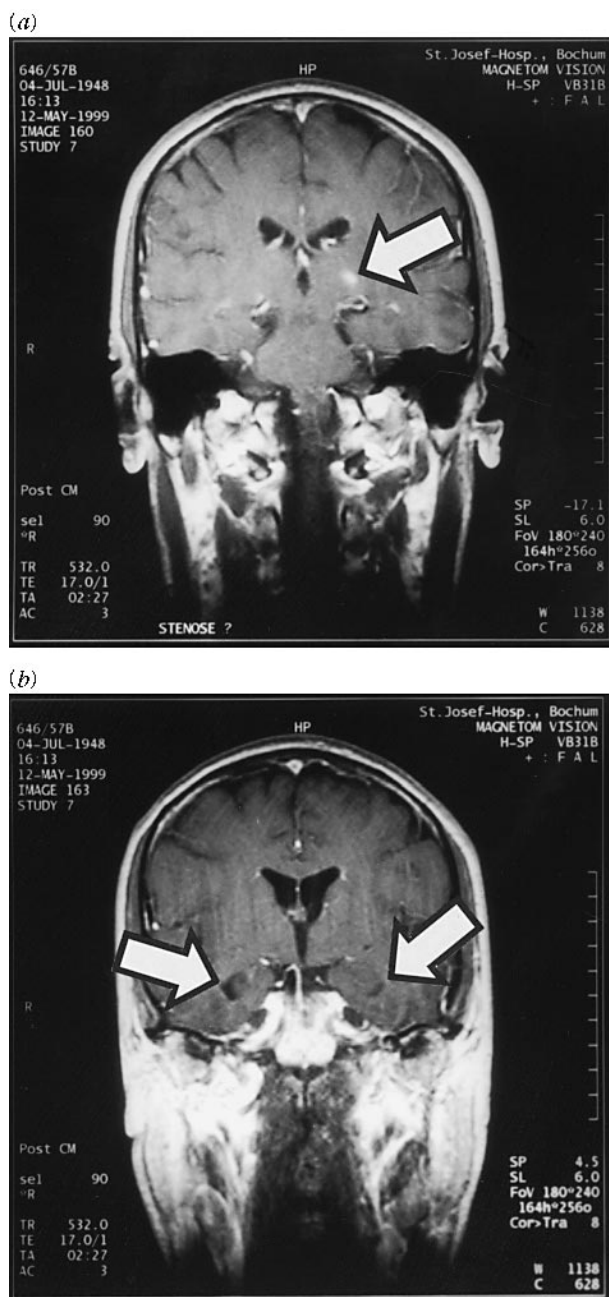


Figure 1. T1-weighted contrast-enhanced MRI scans showing (a) a left thalamic infarction (arrowed) and (b) a bilateral gliosis of unknown genesis in the left and especially the right amygdalar region (arrowed).

At the time of admittance, neurological examination showed a mild right-sided hemiparesis and a severe disturbance of right-sided sensory functions, particularly for position sense, which caused a severe sensory hemiataxia. Further, N.M. presented with a slight dysarthria.

Vascular risk factors were arterial hypertension, hypercholesterolaemia, diabetes and smoking. Doppler ultrasound and magnetic resonance angiography demonstrated no stenosis or occlusion of the extra- and intracranial brain-supplying vessels and electroencephalography showed a normal alpha-rhythm. Ophthalmological investigations revealed mild signs of a diabetic retinopathy. However, as can be seen from the results of neuropsychological tests presented later, N.M.'s performance on a number of visual tests was unimpaired, indicating that

Table 1. N.M.'s performance on neuropsychological background tests

neuropsychological tests	score
intelligence	
WIP IQ	109
attention	
digit span forward (WMS-R)	4 ^a
frontal functions	
word fluency (total)	30
verbal memory	
WMS-R logical memory	
immediate	31
delayed	27
visual memory	
Rey-Osterrieth figure	27
Recognition Memory Test (RMT) faces	46
visual perception and construction	
Vision Contrast Test System (VISTECH)	unimpaired
Visual Object and Space Perception Test (VOSP)	
shape detection (maximum, 20)	20
incomplete letters (maximum, 20)	19
dot counting (maximum, 10)	10
position discrimination (maximum, 20)	20
number location (maximum, 10)	10
cube analysis (maximum, 10)	8
Rey-Osterrieth figure (copy)	46
Benton facial recognition test	50

^a Performance below published norms.

there was no visual dysfunction *per se* which could interfere with visually presented emotion recognition tests.

Inspection of the magnetic resonance image (MRI) showed an oval infarction zone covering the left lateral thalamus (*ca.* 1.0 cm × 0.5 cm) and the medial third of the posterior part of the internal capsule (figure 1) and a lacunar infarction of the right peduncle of the cerebellum. These were both considered recent infarctions. Furthermore, the MRI demonstrated bilateral gliosis in the region of the amygdala, more pronounced on the right than the left. These regions appeared hypointense in the T1-weighted imaging and hyperintense in the T2-weighted and flair imaging. From the clinical observations, it was thought likely that the left thalamic lesion was the immediate cause of N.M.'s speech and right side movement problems, and that the amygdala lesions represented pre-existing injuries that had not caused him to seek medical attention.

In May 1999, N.M. was referred to a rehabilitation clinic. The neurological examination at that time showed improved sensory function, and full recovery from dysarthria and hemiataxia.

(a) Neuropsychological background tests

The MRI findings of amygdala and thalamus lesions suggested that investigation of N.M.'s ability to recognize emotion would be useful, and a single-case study was carried out. Table 1 summarizes the performance of N.M. on a battery of neuropsychological tests, which included measures of intelligence, attention, frontal lobe

Table 2. Performance of N.M. and controls for visual and auditory emotion recognition tasks

(Asterisked scores are significantly below the control mean: * $z > 1.65$, $p < 0.05$; ** $z > 2.33$, $p < 0.01$.)

	N.M.		controls	
	score	z	mean	s.d.
Ekman and Friesen series (maximum, 10)				
happiness	10	0.32	9.91	0.28
surprise	9	0.15	8.82	1.20
fear	2**	-2.71	7.17	1.91
sadness	5*	-1.88	8.22	1.71
disgust	10	0.85	9.02	1.15
anger	7	-1.11	8.77	1.59
emotion hexagon (maximum, 20)				
happiness	19	-0.78	19.62	0.80
surprise	19	0.48	17.97	2.16
fear	8**	-2.44	17.08	3.72
sadness	19	-0.29	19.37	1.26
disgust	20	0.60	18.74	2.09
anger	20	0.67	18.22	2.67
emotional postures (maximum, 10)				
happiness	10	2.09	6.30	1.77
surprise	8	2.10	4.70	1.57
fear	2**	-2.37	6.50	1.90
sadness	9	0.00	9.00	1.41
disgust	2	-0.70	3.40	2.01
anger	6	0.11	5.70	2.63
vocal expression recognition (maximum, 20)				
happiness	15	-0.85	16.33	1.56
surprise	19	0.76	17.58	1.88
fear	12**	-2.89	16.33	1.50
sadness	16	0.00	16.00	2.00
disgust	19	0.34	18.25	2.22
anger	20	2.27	14.33	2.50

functioning and memory, as well as visuoperceptual abilities.

Intelligence was measured using a short version of the WAIS (WIP) (Dahl 1986), involving the information, similarities, picture completion and block design subtests. On this test, N.M. showed an above average IQ of 109. Attention was tested with the WMS-R 'digit span forward' subtest. As shown in table 1, performance on this task was impaired in comparison with the published norms. To measure frontal lobe functioning a verbal fluency task (letters B, F, L for 1 min each) was given. On this task, N.M. reached a total score of 30, which was well within the normal range. Verbal memory was tested with a German version of the WMS-R 'logical memory', and visual memory functioning was assessed with the delayed reproduction of the Rey-Osterrieth figure. Memory for faces was tested with the faces subtest of the Recognition Memory Test (RMT) (Warrington 1984). On all three memory tests, the performance of N.M. was unimpaired according to the tests' norms.

The Visual Object and Space Perception Battery (VOSP) (Warrington & James 1991), the Vision Contrast Test System (VISTECH VCTS 6000), the Rey-Osterrieth figure-copying task, and the Benton facial recognition test (Benton *et al.* 1983) were administered to assess basic as well as higher visuoperceptual

abilities. Results from these tests were in a range considered as normal, indicating unimpaired visuoperceptual functions.

In summary, at the time of testing there was only a deficit on forward digit span—all other scores of the neuropsychological background tests were within the normal range. Importantly, there were no detectable deficits on tests of visuoperceptual abilities.

(b) Recognition of emotion

Because of the particular focus of our study on the recognition of emotion in the visual and auditory modalities, we sought to establish that N.M. would not fail such tasks because he was unable to understand the meanings of verbal emotion terms. He was therefore tested for his comprehension of emotion terms, and proved able to understand the labels used. He could state what it means to say someone is happy, surprised, afraid, sad, disgusted or angry, and give plausible examples of circumstances under which people might experience such emotions.

To test N.M.'s ability to recognize facial expressions, we used two tasks that have been routinely employed in our previous studies. To establish whether N.M.'s problems extended to other visual stimuli conveying emotion we developed a new test of recognition of emotional body postures. To test whether N.M. would also have problems

with vocally expressed emotion we employed a test of vocal expression recognition used previously in a single-case study (Scott *et al.* 1997).

Finally, we sought to explore N.M.'s experience of emotion with standard questionnaires and an interview concerning his experiences of fear in everyday life.

(c) *Facial expressions*

The two facial expression recognition tests we used involved faces from the Ekman & Friesen (1976) series and an emotion hexagon of computer-manipulated expressions.

N.M.'s performance on tasks of facial expression recognition was compared with the performance of a group of 35 healthy adults serving as controls. These control subjects had no history of neurological or psychiatric disorders and a mean age of 48.9 years (s.d. = 14.1). We converted N.M.'s raw scores for recognition of each emotion into z -scores expressing by how many standard deviations it lay above or below the appropriate control mean. Since our main focus of interest was in impairments of emotion recognition, we then used one-tailed probabilities to explore whether N.M.'s performance fell below the control mean.

(i) *Ekman and Friesen faces*

Photographs of the faces of ten people (six female, four male) were taken from the Ekman & Friesen (1976) series. For each face, there were poses corresponding to each of six emotions (happiness, surprise, fear, sadness, disgust and anger), giving a total of 60 images. These were shown on a computer screen one at a time in pseudorandom order, for unlimited presentation time, and N.M. was asked to decide which of the emotion names (happiness, surprise, fear, sadness, disgust or anger) best described the facial expression shown. The names of the six emotions were printed on a card, and this was available throughout the test. There were 60 trials, leading to an accuracy score out of a possible maximum of ten for each of the six emotions. The performance of N.M. was compared with the performance of the control group described above.

Table 2 shows that N.M. performed less well than controls in recognition of fear ($z = -2.71$, $p < 0.01$) and sadness ($z = -1.88$, $p < 0.05$).

(ii) *Emotion hexagon*

As a further test of facial expression recognition, we used an emotion hexagon taken from previous work (Calder *et al.* 1996; Sprengelmeyer *et al.* 1996, 1997). This used photographic-quality continua of morphed images of a face from the Ekman & Friesen (1976) series, prepared by blending between prototype expressions. These morphed faces were presented one at a time on a computer screen, for 5 s each, in pseudorandom order. The subject's task was to decide whether the image presented was most like happiness, surprise, fear, sadness, disgust or anger. Responses were made verbally, with the names of the six possible emotions being printed on a card which could be consulted throughout the test. No feedback was given as to the appropriateness of any responses.

Full details of the procedure and photographs of the stimuli are given elsewhere (Calder *et al.* 1996;

Sprengelmeyer *et al.* 1996, 1997). The test can be used to derive scores out of a possible maximum of 20 correct for recognition of each emotion. The performance of N.M. was compared with the performance of 35 age-matched controls, as shown in table 2.

N.M. showed a significant deficit in fear recognition ($z = -2.44$, $p < 0.01$). In both facial expression tasks, fear was mainly misinterpreted as disgust.

(d) *Emotional postures*

In addition to facial expression recognition, we were particularly interested in whether N.M. was able to recognize emotional postures. For this purpose we used a set of photographs of a female and a male actor who were each asked to produce several different postures expressing happiness, surprise, fear, sadness, disgust and anger. To prevent the use of facial expressions, the actors' faces were masked.

From a larger set of photographs, we selected ten postures for each emotion, giving a total of 60 photographs. The photographs were shown one at a time in pseudorandom order, for unlimited presentation time. Subjects were asked to decide which of the emotion names (happiness, surprise, fear, sadness, disgust or anger) best described the postural expression shown. For each emotion one example was shown for practice.

The performance of N.M. was compared with the performance of ten control subjects (mean age 53.1 years, s.d. = 7.0), as shown in table 2. N.M. was significantly impaired at recognizing fear ($z = -2.36$, $p < 0.01$).

(e) *Vocal expressions*

To assess recognition of emotional vocal expressions a set of emotional sounds was used. The test (taken from Scott *et al.* 1997) consisted of 120 tape-recorded stimuli (20 for each emotion), which were generated by two speakers (one male and one female) who were asked to produce a range of non-verbal sounds corresponding to happiness, sadness, anger, fear, disgust and surprise. The sounds included growls for anger, screams for fear, laughter for happiness, sobbing for sadness, gasping for surprise and retching for disgust.

The sounds were presented one at a time in pseudorandom order. The subject's task was to decide whether the sound presented was most like happiness, surprise, fear, sadness, disgust or anger. Responses were made verbally, with the names of the six possible emotions being printed on a card which could be consulted throughout the test. No feedback was given as to the appropriateness of any responses.

The performance of N.M. was then compared with the performance of 12 healthy controls (mean age 57.2 years, s.d. = 3.9). As can be seen from table 2, N.M. was impaired in recognizing vocal expressions of fear ($z = -2.88$, $p < 0.01$).

(f) *Emotional experience*

Standard questionnaires were used to examine self-assessed emotion for anger, fear and disgust. The anger scale (Novaco 1975) asks you to rate situations on a five-point scale for the extent to which they would make you angry. We used the first 40 items from this 80-item questionnaire. The fear schedule (Wolpe & Lang 1964) also uses a five-point scale for rating things and experiences

Table 3. *Self-assessed emotion on questionnaires involving anger (Novaco 1975), fear (Wolpe & Lang 1964) and disgust (Haidt et al. 1994)*(Asterisked scores are significantly below the control mean: * $z > 1.65$, $p < 0.05$.)

	N.M.		controls	
	score	z	mean	s.d.
fear questionnaire (maximum = 375)	69.00*	-1.72	133.9	37.6
disgust questionnaire (maximum = 100)	42.19	-0.90	58.9	18.5
anger questionnaire (maximum = 200)	111.00*	-1.96	140.8	15.2

that may cause fear or other unpleasant feelings; we used all 75 items and sub-items. The disgust scale (Haidt *et al.* 1994) has 32 items, all of which were used.

Results from the three emotion questionnaires are summarized in table 3, which gives N.M.'s raw scores, and z -scores expressing how many standard deviations these lie below or above the control mean. Scoring procedures and control data come from Sprengelmeyer *et al.* (1996). As is shown in table 3, N.M. did not differ significantly from controls on the disgust questionnaire, but there were significant differences for anger ($z = -1.96$, $p < 0.05$) and fear ($z = -1.72$, $p < 0.05$) indicating that situations which evoke anger and fear in controls do not do so in N.M.

When asked about the occurrence of fear and anger in everyday situations, N.M. reported that he rarely experienced these emotions, although his life, he considered, has been more exciting than the life of an average person.

For most of his adult life, N.M. has lived in several foreign countries in North and South America and Asia, working for different companies as a salesman. While working in the United States he voluntarily underwent a training as a policemen to 'pep up' his otherwise boring stay in that country. He was also passionately fond of hunting in extreme situations, e.g. hunting Jaguars at the upper course of the Orinoco river, or hunting deer in Siberia while hanging on a rope under a helicopter. In these kind of situations, he said that he always experienced excitement but never fear. The only occasion on which he remembered experiencing fear was 20 years ago during a revolution in a South American country when his doorbell rang at five o'clock in the morning, after he had been reading left-wing pamphlets in public and closely observed by the security police the day before. He stated that he adopted an 'Eastern philosophy' approach to life, and was able to cope with difficult and frustrating situations without becoming angry.

3. DISCUSSION

N.M. showed a consistent deficit of fear recognition across tests of recognition of emotion from facial expressions, body postures, and non-verbal sounds. In every test we administered he was impaired at recognizing fear, and for three of the four tests used it was only fear recognition that was impaired. The exception was with facial expressions from the Ekman & Friesen (1976) series, for which N.M. was most impaired for fear but also showed significant difficulty in recognizing sadness. However, problems in recognizing sadness were not noted in any

other test, and N.M.'s recognition of emotions other than fear was usually good—often lying close to or well above the control mean.

N.M.'s deficit of fear recognition was more selective than has usually been reported after amygdala damage, with little evidence of any problem in recognizing anger (a common feature in other reports). However, when given questionnaires concerning his everyday experience of emotion, N.M. reported reduced anger and fear compared with neurologically normal controls. These findings were backed up by N.M.'s reduced levels of fear and anger in everyday situations. He indulged in highly dangerous activities without fear, and he was able to work as a salesman under the difficult conditions created by severe and arbitrary bureaucracies without becoming angry. Such observations concerning N.M.'s emotional experience indicate a link between anger, fear and processes involving the human amygdala.

There were some noteworthy neurological features of N.M.'s case. His presenting symptoms of speech and movement difficulties were due to a left thalamic lesion, but MRI revealed what were considered most likely to be pre-existing amygdala lesions of unknown origin, larger on the right than the left.

This unusual neurology is of interest because, from his interview, it seems likely that reduced experience of fear had been a longstanding feature of N.M.'s life, but we do not know whether his impaired recognition of fear was equally long standing (and therefore likely due to the amygdala pathology) or more recently acquired—perhaps as a result of the combination of amygdala and thalamus lesions.

The most widely adopted interpretation of findings of impaired recognition of fear and anger after amygdala damage has been that they reflect involvement of the amygdala in the evaluation of stimuli related to danger and physical threat (Adolphs *et al.* 1999b; Scott *et al.* 1997). An attractive aspect of this hypothesis is that it links to extensive neurophysiological evidence of the amygdala's involvement in the evaluation of danger and the emotion of fear (LeDoux 1995). An important aspect of LeDoux's conception is that it involves slow (cortical) and fast (thalamoamygdalar) routes for the transmission of emotional information, with the thalamoamygdalar route being involved in the rapid mobilization of responses in potentially dangerous situations. From this standpoint, N.M.'s combination of a small left-sided amygdala lesion with a larger thalamic lesion may have created a critical disruption of the fast pathway. Further studies of individuals with

restricted thalamic pathologies could be used to investigate this possibility.

The main sources of evidence concerning the contributions of the human amygdala to emotion recognition are functional imaging and single-case studies of people with selective brain injuries. As we noted, the functional MRI evidence points to involvement of the amygdala in the recognition of vocally as well as facially expressed emotion (Phillips *et al.* 1998). Although the two previous neuropsychological case studies gave discrepant results (Anderson & Phelps 1998; Scott *et al.* 1997), the data presented here for case N.M. confirm the existence of specific deficits compromising the recognition of the emotion of fear from a wide range of social signals, and suggest that the relationship of this type of impairment with alterations of emotional experience needs to be further explored.

REFERENCES

- Adolphs, R., Tranel, D., Damasio, H. & Damasio, A. 1994 Impaired recognition of emotion in facial expressions following bilateral damage to the human amygdala. *Nature* **372**, 669–672.
- Adolphs, R., Tranel, D., Damasio, H. & Damasio, A. R. 1995 Fear and the human amygdala. *J. Neurosci.* **15**, 5879–5891.
- Adolphs, R., Tranel, D., Hamann, S., Young, A. W., Calder, A. J., Phelps, E., Anderson, A., Lee, G. P. & Damasio, A. R. 1999a Recognition of facial emotion in nine individuals with bilateral amygdala damage. *Neuropsychologia* (In the press.)
- Adolphs, R., Russell, J. A. & Tranel, D. 1999b A role for the human amygdala in recognizing emotional arousal from unpleasant stimuli. *Psychol. Sci.* **10**, 167–171.
- Anderson, A. K. & Phelps, E. A. 1998 Intact recognition of vocal expressions of fear following bilateral lesions of the human amygdala. *NeuroReport* **9**, 3607–3613.
- Benton, A. L., Hamsher, K. S., Varney, N. & Spreen, O. 1983 *Contributions to neuropsychological assessment: a clinical manual*. Oxford University Press.
- Breiter, H. C., Etcoff, N. L., Whalen, P. J., Kennedy, W. A., Rauch, S. L., Buckner, R. L., Strauss, M. M., Hyman, S. E. & Rosen, B. R. 1996 Response and habituation of the human amygdala during visual processing of facial expression. *Neuron* **17**, 875–887.
- Broks, P. (and 11 others) 1998 Face processing impairments after encephalitis: amygdala damage and recognition of fear. *Neuropsychologia* **36**, 59–70.
- Calder, A. J., Young, A. W., Rowland, D., Perrett, D. I., Hodges, J. R. & Etcoff, N. L. 1996 Facial emotion recognition after bilateral amygdala damage: differentially severe impairment of fear. *Cogn. Neuropsychol.* **13**, 699–745.
- Dahl, G. 1986 *WIP. Handbuch zum reduzierten Wechsler-Intelligenztest*. Königsstein, Germany: Hain.
- Ekman, P. & Friesen, W. V. 1976 *Pictures of facial affect*. Palo Alto, CA: Consulting Psychologists Press.
- Haidt, J., McCauley, C. & Rozin, P. 1994 Individual differences in sensitivity to disgust: a scale sampling seven domains of disgust elicitors. *Personal. Individ. Diff.* **16**, 701–713.
- LeDoux, J. E. 1995 Emotion: clues from the brain. *A. Rev. Psychol.* **46**, 209–235.
- Morris, J. S., Frith, C. D., Perrett, D. I., Rowland, D., Young, A. W., Calder, A. J. & Dolan, R. J. 1996 A differential neural response in the human amygdala to fearful and happy facial expressions. *Nature* **383**, 812–815.
- Morris, J. S., Friston, K. J., Büchel, C., Frith, C. D., Young, A. W., Calder, A. J. & Dolan, R. J. 1998 A neuromodulatory role for the human amygdala in processing emotional facial expressions. *Brain* **121**, 47–57.
- Novaco, R. W. 1975 *Anger control*. Lexington, MA: Heath.
- Phillips, M. L. (and 11 others) 1997 A specific neural substrate for perceiving facial expressions of disgust. *Nature* **389**, 495–498.
- Phillips, M. L., Young, A. W., Scott, S. K., Calder, A. J., Andrew, C., Giampetro, V., Williams, S. C. R., Bullmore, E. T., Brammer, M. & Gray, J. A. 1998 Neural responses to facial and vocal expressions of fear and disgust. *Proc. R. Soc. Lond. B* **265**, 1809–1817.
- Scott, S. K., Young, A. W., Calder, A. J., Hellawell, D. J., Aggleton, J. P. & Johnson, M. 1997 Impaired auditory recognition of fear and anger following bilateral amygdala lesions. *Nature* **385**, 254–257.
- Sprengelmeyer, R., Young, A. W., Calder, A. J., Karnat, A., Lange, H. W., Hömberg, V., Perrett, D. I. & Rowland, D. 1996 Loss of disgust: perception of faces and emotions in Huntington's disease. *Brain* **119**, 1647–1665.
- Sprengelmeyer, R. (and 10 others) 1997 Disgust implicated in obsessive-compulsive disorder. *Proc. R. Soc. Lond. B* **264**, 1767–1773.
- Warrington, E. K. 1984 *Recognition memory test*. Windsor, UK: NFER-Nelson.
- Warrington, E. K. & James, M. 1991 *VOSP: the visual object and space perception battery*. Bury St Edmunds, UK: Thames Valley Test Company.
- Weniger, G., Irle, E., Exner, C. & Rütger, E. 1997 Defective conceptualization of emotional facial expressions during T2 signal enhancement of the right amygdala. *NeuroCase* **3**, 259–266.
- Whalen, P. J., Rauch, S. L., Etcoff, N. L., McInerney, S. C., Lee, M. B. & Jenike, M. A. 1998 Masked presentations of emotional facial expressions modulate amygdala activity without explicit knowledge. *J. Neurosci.* **18**, 411–418.
- Wolpe, J. & Lang, P. J. 1964 A fear survey schedule for use in behavior therapy. *Behav. Res. Ther.* **2**, 27–30.