

An Unusual Case of Cortical Blindness Associated with Aortography

A Case Report

Mišo Šabovič, MD, PhD
and Barbara Bonač, MD

LJUBLJANA, SLOVENIA

ABSTRACT

Transient cortical blindness is a rare but well-recognized benign complication of angiography that is due to neurotoxicity of the contrast agent. The blindness completely resolves in a few days. This report describes a patient suffering an unusual course of cortical blindness following aortography resulting in permanent, partial blindness. It was found that blindness was the consequence of bilateral occipital embolisms. This case emphasizes that cortical blindness associated with angiography does not always have a favorable outcome, since it might be, in rare cases, due to isolated occipital embolisms, which initially produce a clinical picture identical to that of the neurotoxic effect of contrast agents.

From the University Medical Centre, Department of Angiology, Internal Clinic, Ljubljana, Slovenia.

©2000 Westminister Publications, Inc., 708 Glen Cove Avenue, Glen Head, NY 11545, U.S.A.

Introduction

Transient cortical blindness is a rare complication of angiography. It is believed that it complicates at least 1% of cerebral and vertebral angiographies,¹ and it has also been reported in association with coronary angiography, aortography, and myelography.²⁻⁴

Since the use of angiography is still growing, physicians will be faced with the syndrome of cortical blindness more frequently, and therefore more information on it is desired. It is well known that transient cortical blindness associated with angiography is due to a neurotoxic effect of the contrast agent on the occipital cortex.⁵ This case report describes cortical blindness as an embolic complication of angiography.

Case Report

The patient was a 74-year-old man with known peripheral arterial occlusive disease and a history of arterial hypertension, diabetes mellitus, hyperlipidemia, and uric arthritis. He was admitted for elective lower limb arterial angiography because of bilateral intermittent claudication that had been present for 4 years. On examination the blood pressure was 170/80 mmHg. Only the right femoral pulse was palpable on his lower extremities, and bilateral iliofemoral bruits were audible. No carotid bruit was present. The angiography was performed by the Seldinger technique. First the right femoral approach was unsuccessfully tried because of a subtotal common iliac artery stenosis. Therefore, the left transaxillary approach was used. A proximal stenosis of the subclavian artery was revealed and passed with the catheter. The tip of the catheter was placed above the aortic bifurcation and the angiography was performed. The patient received a total of 150 mL of contrast agent (Omnipaque, Nycomed, Oslo, Norway).

Two hours after completion of the procedure the patient started to shiver, vomit, and in a few hours gradually became confused. He was disoriented with respect to time and place, had defective memory, and was not aware of blindness. Ophthalmologic examination revealed bilateral amaurosis, but with normal pupillary light responses, normal extraocular movements, and normal fundoscopic findings. Neurologic findings were within normal limits except for bilateral absence of the Achilles tendon reflex.

The gradual return of vision began 3 days after the aortography, whereas mental changes were completely reversed in 2 days. First, light and motion perception in the right half-field returned in both eyes, and complete vision in the mentioned area was restored in 10 days. However, in contrast to the right half-fields, only slight improvement, consisting of light detection, occurred in the left half-field of both eyes. Since the expected complete restoration of vision was not obtained, a computed tomography (CT) scanning of the head was performed on day 5. A hypodense lesion 2 cm in diameter was revealed in the right occipital lobe, whereas no abnormality was found in the left occipital lobe (Figure 1). Evoked visual potentials were abnormal with increased latency and potential amplitude reduction on stimulation of both eyes. An electroretinogram was within normal limits. Ultrasound examination of the carotid arteries and aorta disclosed only slight atherosclerotic lesions (thickened intima and media of carotid arteries) but no plaques. With transesophageal ECHO no thrombi were found in the heart cavities. Control ophthalmologic examination 3 months after angiography did not show any further improvement.

Discussion

Transient cortical blindness associated with angiography is a consequence of selective impairment of the occipital visual cortex due to neurotoxicity of the contrast agent.⁵ It is known that the blood-brain barrier of the occipital cortex is one of the most permeable regions in the central nervous system, which predisposes the occipital cortex to the neurotoxic effect of contrast agents. Contrast-induced cortical blindness appears within minutes to 12 hours after angiography, it is partial or complete, and it may be complicated by mental status changes, hallucinations, and blindness denial. Return of vision is gradual, from light and motion perception to form and color vision. Patients recover completely within 2 to 10 days.^{5,6} Transient cortical blindness is probably not so rare as is believed. It has not yet been systematically investigated in a prospective clinical study, and therefore, reliable data on its frequency are still missing. Transient cortical blindness has been reported in association with cerebral and vertebral angiographies, coronarography, aortography, and myelography.¹⁻⁴ It is important to consider that the cause of (perma-

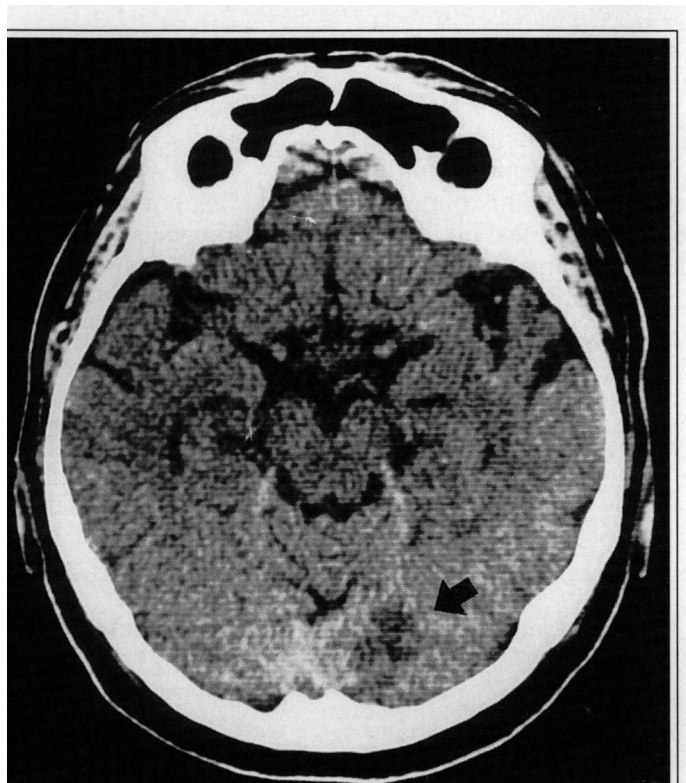


Figure 1. CT scan showing hypodensity in the right occipital lobe (black arrow).

nent or temporary) cortical blindness could also be cerebrovascular disease, embolism, or vasospasm; in addition, cortical blindness has been observed in patients with transient hypotension, head trauma, uremia, meningitis, migraine, coagulopathy, and hysteria.⁷

Our patient suffered the fully developed picture of complete cortical blindness (including mental changes) following aortography. No additional neurologic signs were observed. Thus, the initial course suggested neurotoxicity as the cause of blindness and prompted the attending physician to give a favorable prognosis to the family. However, complete vision was restored only in right half-fields of both eyes. Therefore, CT scanning of the head was performed and revealed a right occipital infarct. It was becoming clear that the patient had suffered isolated bilateral occip-

ital embolisms resulting in right occipital infarct and transient left occipital ischemia. The emboli probably originated from the stenosis in the left subclavian artery and were dislodged during the passage of the intraarterial catheter. It is known that embolization as a consequence of angiography is relatively rare. Thus, the prevalence of cerebral embolisms during angiography is estimated to be up to 0.1%,⁸ whereas isolated bilateral occipital embolisms, as described in our case, are even much rarer. The true nature of cortical blindness in our patient could have been apparent earlier if the following facts that suggest embolism had been considered. First, crossing of a subclavian stenosis by an intraarterial catheter might provoke embolisms; second, related cortical blindness is extremely rare when contrast material is injected in the abdominal aorta.

Conclusion

Our report adds to the variety of clinical presentations of cortical blindness associated with angiography. Since cerebral embolisms might be provoked by angiography, the possibility of occipital embolisms with consequent cortical blindness should always be considered. Taking into account that the initial clinical course does not differ between contrast neurotoxicity and (isolated)

occipital embolisms, we suggest caution in predicting a favorable outcome until imaging tests have been done.

M. Šabovič, MD, PhD
University Medical Centre
Department of Angiology, Internal Clinic
Riharjeva 24
1000 Ljubljana, Slovenia

References

1. Horwitz NH, Wener L: Temporary cortical blindness following angiography. *J Neurosurg* 40:583-586, 1974.
2. Kinn RM, Breisblatt WM: Cortical blindness after coronary angiography: A rare but reversible complication. *Cathet Cardiovasc Diagn* 22:177-179, 1991.
3. Johnson RC, Moss PJ: Temporary blindness following anaesthesia after translumbar aortography. *Anaesthesia* 36:954-955, 1981.
4. Smirniotopoulos JG, Murphy FM, Schellinger D, et al: Cortical blindness after metrazamide myelography: Report of a case and proposed pathophysiologic mechanism. *Arch Neurol* 41:224-226, 1984.
5. Junck L, Marshall WH: Neurotoxicity of radiological contrast agents. *Ann Neurol* 13:469-484, 1983.
6. Silverman SM, Bergman PS, Bender MB: The dynamics of transient cerebral blindness. *Arch Neurol* 4:333-348, 1961.
7. Aldrich MS, Alessi AG, Beck RW, et al: Cortical blindness: Etiology, diagnosis and prognosis. *Ann Neurol* 21:149-158, 1987.
8. Hessel SJ, Adams DF, Abrams HL: Complications of angiography. *Radiology* 138:273-281, 1981.