

Correspondence to: Dr Marek Czosnyka, Academic Neurosurgical Unit, Box 167, Addenbrooke's Hospital, Cambridge CB2 2QQ, UK email MC141@MEDSCHL.CAM.AC.UK

- 1 Marmarou A, Foda MA, Bandoh K, *et al.* Post-traumatic ventriculomegaly: hydrocephalus or atrophy? A new approach for diagnosis using CSF dynamics. *J Neurosurg* 1996;85:1026-35.
- 2 Shapiro K, Fried A, Takei F, *et al.* Effect of the skull and dura on neural axis pressure-volume relationships and CSF hydrodynamics. *J Neurosurg* 1985;63:76-81.
- 3 Czosnyka M, Whitehouse H, Smielewski P, *et al.* Testing of cerebrospinal compensatory reserve in shunted and non-shunted patients: a guide to interpretation based on observational study. *J Neurol Neurosurg Psychiatry* 1996;60:549-58.
- 4 Hochwald GM, Epstein F, Malhan Crashoff J. The role of skull and dura in experimental feline hydrocephalus. *Dev Med Child Neurol* 1972;14(suppl 27):65-9.

Diencephalic amnesia and apraxia after left thalamic infarction

Amnesia and apraxia are unusual manifestations of unilateral thalamic lesions. A patient in whom severe amnesia and apraxia were the presenting features of a left thalamic infarct is presented. The findings support the concept that memory and praxis both utilise circuits which include the dominant thalamus.

A 78 year old right handed Hungarian woman presented with memory loss and disorientation. She had been well and conversed normally with her daughter on the evening before presentation. The next morning, her daughter was alarmed to find her mother's house in a state of disarray. Dishes were unwashed, lights left on, and doors open. The patient seemed baffled by eating utensils, attempting to scoop food with her knife. Later that morning, she failed to recognise longstanding Hungarian friends. She was unable to recall her address, the name of the city in which she lived, or the names of her grandchildren. She subsequently failed to recognise her family doctor of 7 years. History included non-insulin dependent diabetes, hypertension, hyperlipidaemia, and atrial fibrillation. Medications were digoxin,

glibenclamide, and metoprolol. Captopril had been prescribed 4 weeks previously but was ceased 2 days before presentation due to presyncopal symptoms. The patient consumed no alcohol. There was no history of cerebrovascular events.

Cognitive functions were examined at the bedside with the assistance of an interpreter, as the patient spoke no English, although she conversed freely in her native Hungarian. She had no recollection of events since emigrating to Australia 50 years previously, gave her correct maiden name, and could not recognise or name her grandchildren, although she recognised her daughter. She acknowledged she was in a hospital, but maintained it was in Budapest and the year was 1947. Although her recollections regarding her early life and wartime Hungary seemed accurate, she confabulated when asked for details of recent events. Short term recall of verbal material and people was poor. The patient was able to name objects such as a pencil and a watch, and obey two and three stage commands. She wrote her name and copied simple designs correctly, and could imitate gestures such as waving goodbye or blowing a kiss. However, she was unable to use eating utensils or a toothbrush, either in pantomime or when provided with the object itself. Movements of the face and limbs were normal, and there were no sensory abnormalities. Knee and ankle jerks were absent bilaterally and both plantar responses were extensor. General examination revealed atrial fibrillation and mild cardiomegaly.

The patient continued to display severe impairment of anterograde memory. She was reluctant to leave her bed, and quickly became lost unless supervised. She did not recognise familiar staff members and was unable to use ward landmarks to reorientate herself. She required assistance to feed herself, brush her teeth, and shower. When reviewed 3 months later, her memory disturbance and apraxia for simple activities of daily life (such as brushing her teeth) persisted, necessitating care in a supervised environment.

Brain MRI (figure) showed a left anterior thalamic lesion consistent with lacunar infarction and periventricular white matter disease.

Deficits of anterograde and retrograde memory after thalamic lesions are well recognised.¹ The syndrome of diencephalic amnesia after bilateral medial thalamic lesions typically involves striking disorientation for time, loss of autobiographical information (often extending back for many years), confabulation, and severe anterograde amnesia for verbal and visual material, including recognition of familiar faces.¹ These features were well illustrated by our patient, who became "marooned" in an earlier place and time. Amnesia after unilateral thalamic lesions is rare.² There is increasing evidence that thalamic lesions interrupt the multiple brain networks which form the anatomical substrate of memory,¹⁻⁴ encompassing the hippocampus, medial thalamus, frontal and cingulate cortices, and overlapping with the language areas of the left hemisphere.³ The thalamus is activated in retrieval of episodic (autobiographical) and semantic (encyclopaedic) information from long term storage⁴ and execution of learned motor tasks,⁵ which may reflect its widespread connections with other subcortical and cortical structures.

The patient's ability to name or identify objects was not tested systematically. However, on the evidence available, it seems likely that her difficulty in utilising common objects was a manifestation of apraxia for daily tasks rather than, for example, agnosia for the objects involved. Apraxia is a rare manifestation of isolated thalamic lesions.⁵ The ability to access stored motor representations is thought to be crucial for normal execution of learned actions.⁵ These motor representations or "engrams" are analogous to motor memories. Although praxis is generally regarded as a function of distributed cortical regions in the left hemisphere, apraxia in association with thalamic amnesia has not been emphasised in previous reviews of this syndrome.¹⁻³ Involvement of deep hemispheric white matter in association with basal ganglia pathology is thought to be critical for the development of apraxia after lesions of subcortical structures.⁵ The conjunction of diencephalic amnesia and apraxia after thalamic infarction in the present case may be interpreted as further evidence that retrieval of episodic, semantic, and motor memories is mediated by overlapping functional networks in the dominant hemisphere.^{1-3,4}

JD WARREN

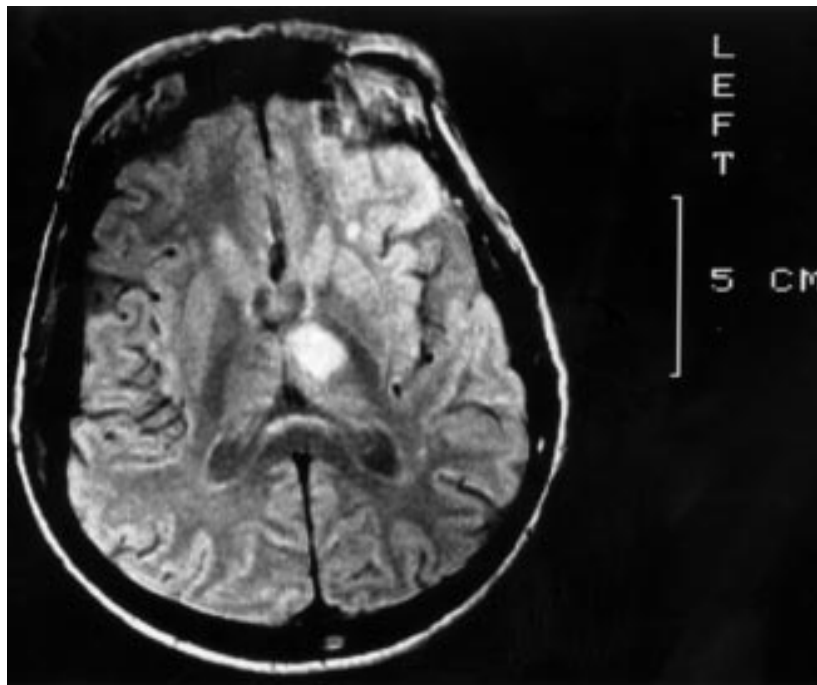
PD THOMPSON

Department of Neurology, Royal Adelaide Hospital, Adelaide, South Australia

PD THOMPSON

University Department of Medicine

Correspondence to: Professor PD Thompson, University Department of Medicine, Royal Adelaide Hospital, Adelaide, South Australia 5000, Australia



T2 weighted axial MRI brain slice showing ischaemic infarction of the left anterior thalamus and periventricular white matter ischaemic changes.

- 1 Hodges JR, McCarthy RA. Autobiographical amnesia resulting from bilateral paramedian thalamic infarction: a case study in cognitive neurobiology. *Brain* 1993;116:921-40.
- 2 Clarke S, Assal E, Bogousslavsky J, *et al.* Pure amnesia after unilateral left polar thalamic infarct: topographic and sequential neuropsychological metabolic (PET) correlations. *J Neurol Neurosurg Psychiatry* 1994;57:27-34.
- 3 Perani D, Bressi S, Cappa SF, *et al.* Evidence of multiple memory systems in the human brain: a [¹⁸F]FDG PET metabolic study. *Brain* 1990;116:903-19.
- 4 Fletcher PC, Frith CD, Grasby PM, *et al.* Brain systems for encoding and retrieval of auditory-verbal memory: an in vivo study in humans. *Brain* 1995;118:401-16.
- 5 Pramstaller PP, Marsden CD. The basal ganglia and apraxia. *Brain* 1996;119:319-40.

Transverse myelopathy in the antiphospholipid antibody syndrome: pinworm infestation as a trigger?

The antiphospholipid antibody syndrome is a disorder characterised by the production of autoantibodies directed against negatively charged cell membrane phospholipids. Antiphospholipid antibodies have been described in various neurological disorders.

It has been generally accepted that viral, bacterial, and parasitic infections can serve as a trigger factor for autoimmune reactions. Despite the growing knowledge that has accumulated, the relation between parasites and autoimmunity has not been clarified.

Enterobius vermicularis (pinworm) is a nematode rarely found outside the gastrointestinal tract, but allergic reaction due to enterobiasis has been reported.¹ We describe the case of transverse myelopathy preceded by intestinal pinworm infestation in the primary antiphospholipid antibody syndrome. To our knowledge, such an association has not been reported previously. Pinworm therapy was complicated by the Jarisch-Herxheimer reaction manifested by temporary exacerbation of pre-existing neurological symptoms.

In March 1998, a 40 year old woman who complained of perianal itching noticed the presence of worms migrating from the anus. Three days later itching and numbness involved both legs, and the patient had weakness in the legs. These symptoms progressed over the next 3 days to severe paraparesis and urinary urgency. Her medical history was relevant for three unexplained miscarriages which all occurred in midpregnancies. In the local hospital, she underwent brain and lumbar-sacral spine MRI and findings were normal. Cerebrospinal fluid examination disclosed slightly raised proteins of 670 mg/l, 2 lymphocytes/mm³; oligoclonal immunoglobulin (Ig) G bands were absent. She was treated with methylprednisolone (1 g/day) intravenously for 5 days with subsequent gradual tapering off, which was associated with substantial improvement of motor, sensory, and sphincter disturbances. At the end of April 1998, the patient was transferred to our hospital for further investigation.

Neurological examination showed mild spastic paraparesis, bilateral Babinski's sign, and a Th-12 sensory level.

Erythrocyte sedimentation rate was 34. Complete blood count, tests for hepatic and renal function, angiotensin converting enzyme, concentrations of IgG, IgM, IgA, IgE, and immune complexes, screening for anti-nuclear (HEp-2 cells), anti-ds DNA, antineutrophil cytoplasmic, antimitochondrial, and antiparietal cell antibodies, rheumatoid factor, and the search for antineurotropic virus and antiBorrelia antibodies were normal or negative. A venereal disease research laboratory flocculation test was negative. A medium positive concentration of IgM anticardiolipin antibody was detected, and lupus anticoagulant was negative. Raised titres of serum IgG and IgM anti-GM1 (1:1600 and 1:3200, respectively) and antisuльфatide antibodies (1:6400, for both classes) were also demonstrated. Class II human leucocyte antigen (HLA) typing showed the presence of HLA-DR3, DR4, DR52, DR53, DQ2, and DQ3. Cervical and thoracic spine MRI was normal. Electromyoneurography was normal.

Because the patient complained of reappearance of worms and perianal itching, a cellulose adhesive tape test was performed and diagnosis of enterobiasis was established.

Mebendazole was given in a single dose of 100 mg and the next day the Jarisch-Herxheimer reaction occurred, with deterioration of leg spasticity, inability to walk, and development of urinary retention. At that time, low positive IgG ACA was detected. The dose of prednisone was raised to 60 mg/day and slowly tapered off within the next 2 months. Sphincter disturbances resolved in 1 day and motor dysfunction gradually improved with only mild spasticity left.

Diagnosis of antiphospholipid antibody syndrome in our patient was based on the presence of recurrent fetal loss, transverse myelopathy, and raised ACA. The ACA titre was probably lowered by previously administered corticosteroid therapy. There are several reports of transverse myelopathy as a manifestation of antiphospholipid antibody syndrome in the past decade.^{2,3} A potential pathogenic role of antiphospholipid antibodies in transverse myelopathy might be based either on vasculopathy or on interaction with spinal cord phospholipids.

Infection by helminths is universally associated with activation of T helper 2 (Th2)-type cells. Regardless of the mechanisms and protective value of antihelminthic Th2 responses, such responses may also be detrimental to the host. The presence of ACA, anti-GM1, and antisuльфatide antibodies in our patient suggests a systemic response to *E. vermicularis*, as it has been shown that nematodes contain cardiolipin, ganglioside GM1, and sulfatides within their complex lipid composition.⁴ When parasites share epitopes with host tissue, such molecular mimicry may exploit host immune tolerance against a self determinant. Autoimmunity may occur if immune tolerance is overridden in genetically susceptible hosts. It has been proposed that the presence of pathogenic cross reactive autoantibodies could be the basis for the relation between nematodes and autoimmunity. It may be also postulated that *E. vermicularis* stimulated Th2 response which enhanced polyclonal autoantibody production resulting in the presence of ACA, anti-GM1, and antisuльфatide antibodies. The association of transverse myelopathy, ACA, and enterobiasis might be purely coincidental, which we assume to be highly unlikely. The finding of different autoantibodies, as well as the isotype switch of ACA, strongly suggests that pinworm infestation in our patient was the "triggering event" that increased the production of autoantibodies against cardiolipin and led to the development of transverse myelopathy.

The appearance of the spinal cord damage caused by ACA in our patient might have been facilitated by the simultaneous effect of anti-GM1 and antisuльфatide antibodies. A significant subset of the human anti-GM1 antibodies that reacted with the Gal(b1-3)GalNAc determinant also bound to oligodendrocyte-myelin glycoprotein which is a constituent of the myelin of the CNS. As for antisuльфatide antibodies, their presence has been already shown in some diseases affecting the CNS.

It is clear that parasitic infections can serve as a trigger factor of autoimmune reactivity, but the presence of autoantibodies or self reactive T cells is rarely associated with clinical manifestations. They develop only in patients with adequate immunogenetic and hormonal background for autoimmune diseases. In several studies, increased frequencies of HLA-DR4, DR7, DR53, and DQ7 were found in patients with antiphospholipid antibody syndrome,⁵ and in our patient

HLA-DR4 and DR53 were present. Additional studies are necessary to further elucidate the complex mechanisms of involvement of intestinal helminths in the processes of autoimmune activity.

JELENA DRULOVIĆ
IRENA DUJMOVIĆ
NEBOJSA STOJSAVLJEVIĆ
IVANA TRIPKOVIĆ
SLOBODAN APOSTOLSKI
ZVONIMIR LEVIĆ

Institute of Neurology, CCS, School of Medicine, University of Belgrade, Dr Subotića 6, 11000 Belgrade, Yugoslavia

MARIJA MOSTARICA STOJKOVIĆ
Institute of Microbiology and Immunology

BRANKA BONACI
SLADJANA ANDREJEVIĆ
Institute of Allergy

Correspondence to: Dr J Drulović, Institute of Neurology, CCS, School of Medicine, University of Belgrade, Dr Subotića 6, 11000 Belgrade, Yugoslavia

- 1 Montag A, Ulrich R. Chronic urticaria in enterobiasis vermicularis (oxyuriasis). *Hautarzt* 1992;43:652-3.
- 2 Schantz V, Oestergaard LL, Junker P. Shrinking spinal cord following transverse myelopathy in a patient with systemic lupus erythematosus and the phospholipid antibody syndrome. *J Rheumatol* 1998;25:1425-8.
- 3 Ruiz-Arguelles GJ, Guzman-Ramos J, Flores-Flores J, et al. Refractory hiccup heralding transverse myelitis in the primary antiphospholipid syndrome. *Lupus* 1998;7:49-50.
- 4 Maloney MD, Semprevivo LH. Thin-layer and liquid column chromatographic analyses of the lipids of adult *Onchocerca gibsoni*. *Parasitol Res* 1991;77:294-300.
- 5 Wilson WA. Histocompatibility genes in antiphospholipid antibody syndrome. *Lupus* 1996;5:259-262.

Radiologically selective visual pathway involvement in adult onset cerebral adrenoleukodystrophy

A case of adult onset cerebral adrenoleukodystrophy is presented with serial MRI showing selective involvement of the visual system with spread of disease along the fibre tracts of this system.

Adult onset cerebral adrenoleukodystrophy is the rarest presentation of adrenoleukodystrophy.^{1,2} It may present with various symptoms often including visual impairment.³ Brain MRI may show multiple areas of symmetric high signal intensity within cerebral white matter, usually affecting the occipital lobes.⁴⁻⁶ We present a case of adrenoleukodystrophy, in whom serial MRI demonstrated selective progression of demyelination through the visual pathways.

A thirty year old man presented in May 1996 with a 7 month history of deteriorating vision, slurred speech, incoordination, poor balance, generalised weakness, sleep disturbance, and headaches. His symptoms were worse on the right. He had no symptoms of postural hypotension.

His mother had been shown to be a carrier of X linked adrenoleukodystrophy (XL-ALD). His two elder brothers had died of XL-ALD at the ages of 6 and 7 years. In 1993 our patient had been shown to have abnormal serum concentrations of very long chain fatty acids (VLCFAs) and to be a carrier of the XL-ALD gene. At that time he was asymptomatic and had no abnormal neurological signs. Crohn's disease had been diagnosed in 1987 after an ileal resection although this had remained in remission.

On examination, visual acuities were 6/12 (right), 6/9 (left). Fields were full to confront-