

## Using fMRI to Study Recovery from Acquired Dysphasia

Gemma A. Calvert,\* Michael J. Brammer,† Robin G. Morris,‡  
Steve C. R. Williams,† Nigel King,‡ and Paul M. Matthews\*

\**Centre for Functional Magnetic Resonance Imaging of the Brain (FMRIB), University of Oxford, John Radcliffe Hospital, Headington, Oxford OX3 9DU; †Institute of Psychiatry, De Crespigny Park, Denmark Hill, London SE5 8AF; and ‡Rivermead Rehabilitation Centre, Abingdon Road, Oxford OX1 4XD United Kingdom*

We have used functional magnetic resonance imaging (fMRI) to characterize brain activations associated with two distinct language tasks performed by a 28-year-old woman after partial recovery from dysphasia due to a left frontal hemispheric ischemic stroke. MRI showed that her ischemic lesion extended posteriorly from the left inferior frontal to the perisylvian cortex. fMRI scans of both language tasks revealed substantial differences in activation pattern relative to controls. The nature of this difference was task-specific. During performance of a verbal semantic decision task, the patient, in contrast to controls, activated a network of brain areas that excluded the inferior frontal gyrus (in either hemisphere). A second task involving rhyme judgment was designed to place a heavier cognitive load on language production processes and activated the left inferior frontal gyrus (Broca's area) strongly in normal controls. During this task, the most prominent frontal activation in the patient occurred in the right homologue of Broca's area. Subsequent analysis of this data by methods able to deal with responses of changing amplitude revealed additional, less sustained recruitment by the patient of cortex adjacent to the infarct in the region inferior to Broca's area during rhyming. These results suggest that in addition to changes in cognitive strategy, recovery from dysphasia could be mediated by both the preservation of neuronal networks in and around the infarct and the use of homologous regions in the contralateral hemisphere. © 2000 Academic Press

*Key Words:* fMRI; stroke; dysphasia; language; rehabilitation.

---

We gratefully acknowledge MRC programme grant support for the FMRIB Centre and for stroke studies (PMM). G.A.C. is supported by a Research Fellowship from the Medical Research Council. The authors thank Chris Andrew for technical support and Dr. Judith Allinson at the Rivermead Rehabilitation Centre for her enthusiastic clinical assistance.

Address correspondence and reprint request to Gemma A. Calvert, FMRIB Centre, University of Oxford, John Radcliffe Hospital, Headington, Oxford, OX3 9DU United Kingdom. Fax: 01865 222717. E-mail: [gemma@fmrib.ox.ac.uk](mailto:gemma@fmrib.ox.ac.uk).



## INTRODUCTION

The mechanisms of recovery from dysphasia following infarction of left hemispheric language zones remain elusive. Modern functional neuroimaging techniques offer great potential for elucidating these mechanisms but have had only limited success to date in resolving many of the outstanding issues raised in the clinical and anatomical literature. While some imaging studies have linked recovery to the recruitment of homologous sites in the nondominant hemisphere (Weiller et al., 1995; Ohyama et al., 1996), others suggest instead that improvement is achieved by activation of residual left hemispheric language areas (Heiss et al., 1993, 1997). Functional neuroimaging data in healthy subjects have shown that linguistic tasks differ in the extent to which they activate the network of language centers distributed through the frontal lobe and along the perisylvian region in temporal and parietal cortex (Frackowiak, 1994). In view of these findings, an incomplete picture of function in these regions in patients with dysphasia might result from reliance on a single experimental paradigm.

Functional magnetic resonance imaging (fMRI) is emerging as a powerful tool for mapping patterns of brain activation associated with language processing. Potential advantages of fMRI over positron emission tomography (PET) or single photon emission computed tomography (SPECT) for functional imaging of patients include the ability to map activations sensitively in single individuals, lack of restrictions on the number or frequency of studies that can be performed, and a relatively higher spatial and temporal resolution. Here we report a case study illustrating both the potential advantages and problems associated with the clinical application of fMRI for defining possible mechanisms of recovery from dysphasia.

## CASE REPORT

A 28-year-old right-handed woman suffered a left hemispheric ischemic stroke due to a spontaneous left carotid dissection. On admission 1 h after the onset of symptoms she was mute, with a severely depressed level of consciousness (GCS 8). An MRI scan performed at day 3 showed an abnormal hyperintense signal on the T2-weighted images extending posteriorly from the inferior frontal gyrus through superior frontal regions to the angular gyrus.

Over the course of the subsequent 2 weeks the patient recovered normal awareness and was able to follow simple commands despite severe expressive dysphasia. During the next 5 months she received intensive rehabilitation therapy. Despite substantial recovery of language function, the patient continued to display marked word finding and sentence construction difficulties and speech was effortful for all but commonplace phrases. Although comprehension was considerably less impaired than production, as indicated by her continued enjoyment of reading in addition to neuropsychological

assessment, the patient maintained a persistent moderate semantic impairment at the single word level (Psycholinguistic Assessments of Language Processing in Dysphasia (PALPA) 48: 36/40) and demonstrated difficulty understanding plausibly reversible sentences. Neuropsychological testing demonstrated a full-scale IQ of 88 (Verbal = 82; Performance = 101) with an estimated premorbid IQ in the "above average" range. Educational attainment included 3 A levels and Registered General Nursing status.

## METHODS

To investigate brain activation associated with the patient's recovery of language comprehension and production 5 months after the stroke, the patient and three female controls matched for age, handedness, and educational background underwent fMRI scanning during the performance of two distinct linguistic tasks. The tasks were selected on the basis that they had previously been shown to activate large areas of the language network (Bullmore et al., 1996; Calvert, unpublished findings) and were also presumed to differ in the extent to which they taxed language comprehension and production processes, respectively (Shaywitz et al., 1995). Both paradigms employed a standard boxcar design with 30 s of an experimental stimulus alternating with 30 s of a control stimulus for a total scanning time of 5 min per experiment. Responses were recorded via a pushbutton box held in the left hand and accuracy scores noted after scanning. The visible stimuli were presented via a back-projection screen located at the end of the scanner bed and were visible by means of a mirror strategically angled above the subject's head in the scanner. Verbal stimuli were presented in blue against a white background. Prior to scanning, each subject was shown examples of the stimuli and completed practice trials outside the scanner. Task difficulty was matched between controls and the patient by calibrating trial rate to performance scores outside the scanner. For Task 1, the patient and controls were both able to complete the task with the same trial intervals; for Task 2, the patient required fewer trials to perform to the same level as controls.

Task 1 was a verbal semantic decision task which involved judging whether a presented word belonged to the category of living or nonliving things compared with a resting control condition. English nouns were visually presented on a screen every 3 s and subjects were asked to indicate by pressing a button when the item they saw belonged to the category of living things.

Task 2 was a rhyme judgment task in which pairs of pseudohomophones (nonwords that obey lexical rules, e.g., "flait" and "klate") were presented on a screen during the experimental condition and subjects were asked to indicate by pressing a button if the two words on each trial rhymed. In the control condition, subjects were presented with either "XO" or "XX" and were asked to press the button for "XX" only. This contrast was designed to control for the motor component of the task and low level visual analysis.

Gradient echo echoplanar imaging (EPI) MRI data were acquired using a 1.5T GE Signa scanner with Advanced NMR operation console with a quadrature birdcage head coil. One hundred T2-weighted images depicting bold oxygen level-dependent (BOLD) contrast (Ogawa et al., 1990) were acquired with an in-plane resolution of 3 mm (TE 40 ms, TR 3000 ms) at each of 14 near-axial noncontiguous 7-mm-thick slices (with 0.7-mm interslice gap) positioned parallel to the anterior-posterior commissural line. For each subject a multislice inversion recovery echoplanar image was also acquired in the same plane for spatial normalization. Correction for slight subject movement during image acquisition was performed using standard algorithms (Friston et al., 1996). Activations were determined using time series regression with a significance threshold determined at  $p < .004$  from randomization tests (Bullmore et al., 1996). Activation maps for both the patient and controls were then transformed into standard stereotactic space of Talairach and Tournoux (Brammer et al., 1997) and overlaid onto a

structural template or, in the case of the patient, on her own structural scan following suitable spatial transformation. This allowed identification of the activations with respect to her infarct as well as determination of Brodmann areas (BA) and thus comparison with other imaging studies. In the case of the rhyme judgment task, data from the individual activation maps are shown for clearer representation of the extent of individual variability. However, in this study as well, Brodmann areas corresponding to activations were determined by group averaging and mapping both control and patient data into standard stereotactic space.

Most commonly used fMRI analysis methods assume that the level of response (seen as a change in image intensity) remains constant throughout the experiment. Failing to identify when this is not the case will lead to a loss of sensitivity in detecting activations. Although this phenomenon may occur in healthy subjects, for example during habituation, it is potentially a much more serious problem among patients where pathological changes may affect the capacity to sustain cognitive performance. To address this problem, the data were subsequently examined by wavelet analysis. This is a technique commonly employed when there is a requirement to look at different frequency components of a signal while preserving information about where those frequency components might be concentrated in time (information which is lost in traditional Fourier-based analysis methods). We have developed methods of fMRI time-series analysis which identify clusters of significant wavelet coefficients by Kolmogorov-Smirnov tests, with correction for multiple comparisons (Brammer, 1998). These methods were applied in the current study to identify brain regions in which there were responses at the frequency of alternation of the experimental and control conditions which may not be maintained for the duration of the experiment.

## RESULTS

Analysis of the response data collected during both fMRI scans revealed no significant difference in accuracy scores between the patient and the control group (close to 100% accuracy in both cases).

### *Task 1: Discrimination between Visually Presented Names of Living and Nonliving Objects*

For the controls as a group, the most prominent areas of activation included left occipital and fusiform gyri (extrastriate visual cortex; BA 18/19), the left inferior frontal gyrus (BA 44/45), and left middle frontal gyrus (BA 44/9) (Fig. 1A). Smaller clusters of activated pixels were also detected in the left superior temporal gyrus (BA 22), the right inferior frontal gyrus (ventral to those observed in the left hemisphere), the anterior cingulate gyrus (BA9/32), and the left angular gyrus (BA 39). By comparison, the patient showed far more extensive bilateral activation of occipital and fusiform gyri (BA 17; 18/19), a small cluster of activated pixels in the left middle frontal gyrus (BA 9), and no activation of the left inferior frontal gyrus (either around or adjacent to the infarct) (Fig. 1B). Small clusters of activation were also detected in the left superior temporal gyrus, bordering on the occipito-temporal junction (BA 22/37) and, more extensively, in the precuneus (BA 31/7). Activation in the right inferior frontal gyrus (BA 44/45) was confined to 2 pixels, comparable to that observed in the controls.

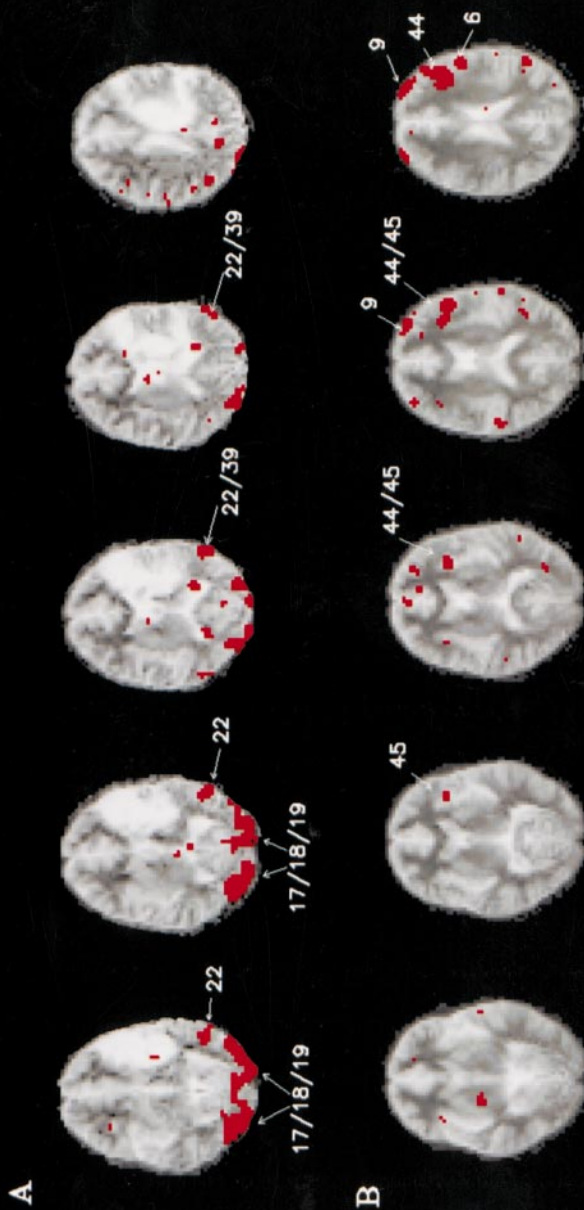
*Task 2: Discrimination between Rhyming and Nonrhyming Pseudohomophones*

Regions consistently activated by controls included left occipital and fusiform gyri (BA 17/18/19), the superior temporal gyri (left greater than right) (BA 22), and both middle frontal (BA 44/9) and inferior frontal (Broca's area) gyri (BA 44/45) in the left hemisphere. A smaller cluster of activated pixels was found in the right inferior frontal cortex, although activation in this region of the brain was lateralized strongly to the left, as can be observed by inspection of the individual scans (Fig. 2A). The patient showed much less activation overall but one of the two largest clusters of activation was in the right inferior frontal cortex. Activation was also observed in the left middle frontal gyrus (BA 6/9) and anterior cingulate (9/32). More intriguingly, there was a small cluster of pixels along the posterior border of the infarct in the region of the left inferior frontal gyrus. Subsequent wavelet analysis of the data revealed that for the patient, extensive activation was detectable in the left inferior frontal gyrus, ventral to the infarct (Fig. 2B). As this was not detectable by standard time-series regression (Bullmore et al. 1996) it is likely that the responses showed considerable changes in amplitude during the experiment.

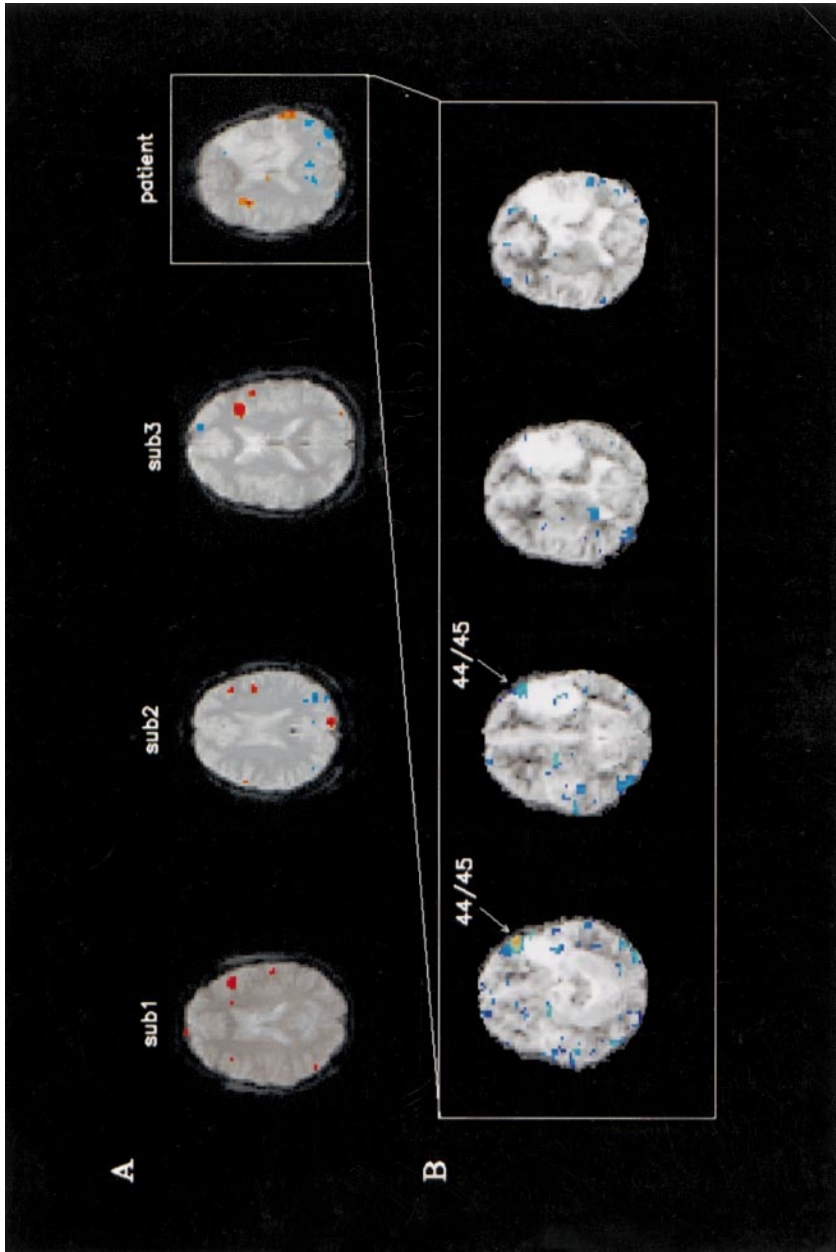
## DISCUSSION

There are at least two important questions that can be addressed by functional neuroimaging studies of patients with acquired dysphasia. The first is what are the neurophysiological changes that lead to the behavioral deficits? The second is what mechanisms are responsible for recovery of language? Our patient demonstrated a pattern of brain activation that was broadly consistent with her neuropsychological deficits according to current neural models of language processing (Frackowiak, 1994; Mazoyer et al., 1993). Marked reduction in activation of Broca's area and activation of undamaged areas of posterior temporal cortex during both tasks is consistent with the patient's better performance on tasks involving language comprehension compared with those involving language production. This basic pattern of activation is in keeping with the location of her infarct, which extends more prominently into the inferior frontal gyrus than posterior temporal and parietal sites. However, there were several less predictable observations that may shed further light on the mechanisms underlying this patient's recovery of function, particularly with respect to articulation.

The most striking difference between the patient and the control group in response to the semantic classification task was observed in extrastriate visual cortex. Activation of this area was much more extensive in the patient. This is unlikely to reflect the transfer of certain linguistic processes to these regions. It seems much more plausible to suppose that the patient may be making more extensive use of visual processing during task performance,



**FIG. 1.** The figure shows generic brain activation maps for the patient (A) and the controls (B) for the visual semantic classification task. Activations are superimposed on the morphology of the patient (A) and the control subjects (B) transformed into the standard stereotaxic space of Talairach and Tournoux. In the case of the control group, the morphology shown is the voxelwise average of the three subjects. Images are shown in radiological convention, right side of the brain on the left side of the image and vice versa.



**FIG. 2.** Row A depicts the brain slices which in each individual showed the largest extent of activation in Broca's area (extending through BA 44/45) during performance of the rhyme judgment task. Activation in the right homologue of Broca's area for controls was confined to one or two voxels. The inset shows activations in the area surrounding the patient's infarct detected by wavelet analysis (see text).

suggesting a change in cognitive strategy rather than cortical plasticity. As this case illustrates, therefore, mechanisms underlying functional recovery from dysphasia need not be confined to the unmasking of functions in homologous right hemisphere sites or performance of residual tissue but might also include the adoption of different processing strategies.

Had our investigation of this patient been confined to this one task, we may have concluded that she lacked function both in the left inferior frontal gyrus and its right hemisphere homologue. However, to probe function in these areas further we included an additional language task (rhyme judgment) designed to place greater cognitive demand on these regions and by doing so were able to elicit activation of the right inferior frontal gyrus in the patient. Indeed, further examination of this data using wavelet analysis revealed additional activations even in the peri-infarct region inferior to Broca's area. The observation that wavelet analysis was necessary to define these activations suggests that the responses showed an abnormally large variation in response amplitude across the set of trials.

The findings of these two experiments indicate that in this patient, although there may be some preservation of tissue in left frontal language areas, recruitment of nondominant hemispheric regions and novel processing strategies also appear to play a significant role in recovery of function. As this single case study shows, fMRI has the capacity to yield useful data on the mechanisms underlying both functional impairment and recovery, but the success of such studies may depend critically on matching task performance, understanding the potential range of alternative processing strategies for various tasks, and application of sensitive tools for data analysis. Although functional activation studies can provide insight into the cerebral metabolic correlates of language processing both in normal subjects and dysphasic patients, they cannot reveal the computations being performed in metabolically activated areas. Future studies might address this difficulty by combining transient functional interference using transcranial magnetic stimulation with fMRI. In view of many fundamental problems in understanding dysphasia, there is clearly room for well-designed case studies to contribute to the compilation of a database of information in this area.

## REFERENCES

- Brammer, M. J. 1998. Multidimensional wavelet analysis of functional magnetic resonance images. In *Human Brain Mapping*. Vol. 6, 378-382.
- Brammer, M. J., Bullmore, E. T., Simmons, A., Williams, S. C., Grasby, P. M., Howard, R. J., Woodruff, P. W., & Rabe, H. S. 1997. Generic brain activation mapping in functional magnetic resonance imaging: A nonparametric approach. *Magnetic Resonance Imaging*, 15, 763-770.
- Bullmore, E., Brammer, M., Williams, S. C., Rabe, H. S., Janot, N., David, A., Mellers, J., Howard, R., & Sham, P. 1996. Statistical methods of estimation and inference for functional MR image analysis. *Magnetic Resonance Medicine*, 35, 261-277.



- Bullmore, E. T., Rabe, H. S., Morris, R. G., Williams, S. C., Gregory, L., Gray, J. A., & Brammer, M. J. 1996. Functional magnetic resonance image analysis of a large-scale neurocognitive network. *Neuroimage*, **4**, 16–33.
- Frackowiak, R. S. 1994. Functional mapping of verbal memory and language. *Trends in Neuroscience*, **17**, 109–115.
- Friston, K. J., Williams, S., Howard, R., Frackowiak, R. S., & Turner, R. 1996. Movement-related effects in fMRI time-series. *Magnetic Resonance Medicine*, **35**, 346–355.
- Heiss, W. D., Emunds, H. G., & Herholz, K. 1993. Cerebral glucose metabolism as a predictor of rehabilitation after ischaemic stroke. *Stroke*, **24**, 1784–1788.
- Heiss, W. D., Karbe, H., Weber, L. G., Herholz, K., Kessler, J., Pietrzyk, U., & Pawlik, G. 1997. Speech-induced cerebral metabolic activation reflects recovery from aphasia. *Journal of the Neurological Sciences*, **145**, 213–217.
- Mazoyer, B. M., Tzourio, N., Frak, V., Syrota, A., Murayam, N., & Leveir, O. 1993. The cortical representation of speech. *Journal of Cognitive Neuroscience*, **5**, 467–479.
- Ogawa, S., Lee, T. M., Kay, A. R. & Tank, D. W. 1990. Brain magnetic resonance imaging with contrast dependent on blood oxygenation. *Proceedings of the National Academy of Science USA*, **87**, 9868–9872.
- Ohyama, M., Senda, M., Kitamura, S., Ishii, K., Mishina, M., & Terashi, A. 1996. Role of the nondominant hemisphere and undamaged area during word repetition in poststroke aphasics. A PET activation study. *Stroke*, **27**, 897–903.
- Shaywitz, B. A., Shaywitz, S. E., Pugh, K. R., Constable, R. T., Skudlarski, P., Fulbright, R. K., Bronen, R. A., Fletcher, J. M., Shankweiler, D. P., & Katz, L. 1995. Sex differences in the functional organization of the brain for language. *Nature*, **373**, 607–609.
- Weiller, C., Isensee, C., Rijntjes, M., Huber, W., Muller, S., Bier, D., Dutschka, K., Woods, R. P., North, J., & Diener, H. C. 1995. Recovery from Wernicke's aphasia: A positron emission tomographic study. *Annals of Neurology*, **37**, 723–732.