

## Case report

# Sagittal sinus thrombosis associated with transient free protein S deficiency after L-asparaginase treatment: case report and review of the literature

Jae-Hong Lee <sup>a,\*</sup>, Sang-We Kim <sup>b</sup>, Jong Sung Kim <sup>a</sup>

<sup>a</sup> Department of Neurology, University of Ulsan College of Medicine, Asan Medical Center, 388-1 Poongnap-dong songpa-gu, Seoul 138-736, South Korea

<sup>b</sup> Department of Internal Medicine, University of Ulsan, Asan Medical Center, Seoul, South Korea

Received 11 May 1999; received in revised form 15 November 1999; accepted 15 November 1999

## Abstract

Cerebral sinus thrombosis associated with acquired free protein S deficiency is very rare. We report the case of an adult patient with acute lymphoblastic leukemia who presented with repeated transient ischemic attacks followed by a seizure during consolidation treatment with L-asparaginase. Magnetic resonance of the brain showed a small cortical hemorrhagic infarct. Superior sagittal sinus thrombosis was demonstrated by cerebral angiogram. A marked decrease of the free form of protein S was documented. One month later, when the patient was free of symptoms, the follow-up free protein S antigen level was restored to the normal range. We suggest that the sagittal sinus thrombosis in this patient was caused by acquired, transient free protein S deficiency. This case also extends the clinical spectrum of cerebral sinus thrombosis to include recurrent transient ischemic attacks alternating with seizures. © 2000 Elsevier Science B.V. All rights reserved.

**Keywords:** L-Asparaginase; Acute lymphoblastic leukemia; Blood proteins; Free protein S; Cerebral venous thrombosis; Sagittal sinus

## 1. Introduction

Acquired or inherited deficiency of natural anticoagulants is a well-known cause of venous thrombosis. Free protein S serves as a cofactor for activated protein C, and protein C–S complex exerts its antithrombotic effect by inactivating activated factor V and VIII, and by inhibiting plasminogen activator inhibitor [1]. Free protein S deficiency produces a coagulopathy and may cause cerebral vessel thrombosis. Cerebral sinus thrombosis (CST) associated with free protein S deficiency, however, is very rare [2]. Previous cases were mostly related to hereditary protein S deficiency [3,4]. An acquired deficiency of the free protein S after L-asparaginase therapy has not yet been reported to be associated with CST.

We report the case of a patient with acute lymphoblastic leukemia (ALL) who showed an unusual combination of clinical manifestations of superior sagittal sinus thrombosis during the treatment with L-asparaginase, which was probably due to a hypercoagulable state caused by free protein S deficiency.

## 2. Case report

A 22-year-old man presented in November 1996 with recurrent episodes of transient left hemiparesis. He had been well until 19 years of age, when easy fatigability developed. Complete blood count (CBC) showed a hemoglobin level of 93 g/l; white blood cell count, 11 100/mm<sup>3</sup>; and platelet count, 26 000/mm<sup>3</sup>. Bone marrow was replaced by non-T, non-B cell, L2 morphology lymphoblasts. Induction therapy consisted of vincristine

\* Tel.: + 82-2-2224-3446; fax: + 82-2-474-4691.

E-mail address: jhlee@www.amc.seoul.kr (J.-H. Lee)

sulfate, prednisone, daunorubicin, and L-asparaginase. He received 1800 rad cranial irradiation with six doses of intrathecal methotrexate. Maintenance therapy was begun with oral methotrexate and 6-mercaptopurine.

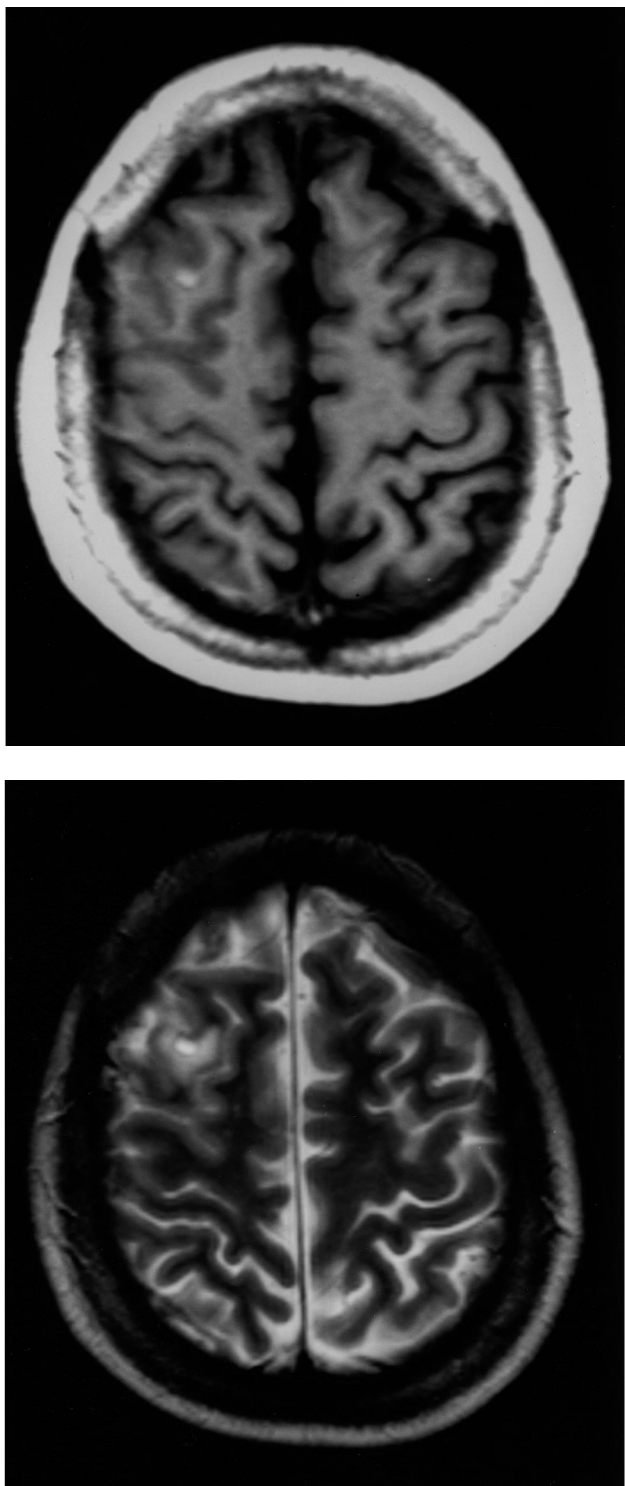


Fig. 1. Axial T1- (a) and T2-weighted (b) magnetic resonance images show an area of high signal intensity in the right frontal lobe, indicating a hemorrhagic venous infarct.

He had a relapse in November 1995 and his bone marrow was replaced by L1 lymphoblasts. The second re-induction was done with uneventful remission, followed by alternating courses of consolidation therapy. Courses one, three, five, and seven of consolidation chemotherapy consisted of daunorubicin, vincristine, prednisone, and L-asparaginase. Courses two, four, six, and eight consisted of VP-16 and Ara-C. He received the seventh consolidation therapy in October 1996 with a 2-week course of vincristine, prednisone, daunorubicin, and L-asparaginase. Three days after the last sixth dose of L-asparaginase (18 000 U), he was admitted to the Medical Oncology Service due to abrupt onset of headache, nausea, and paresthesia in the left extremities, followed by paralysis in the same extremities. It resolved in 5–10 min. During the attack, the consciousness was not impaired at all. The same episode recurred twice during hospitalization. Neurologic consultation was obtained. General physical examination including fundoscopic examination was normal. Neurologic examination at the time of paralysis revealed the patient to be alert and coherent. A mild left central facial palsy was noted. He showed a left hemiparesis with the arm Gr I and the leg Gr IV. There was a plantar extensor response on the left. The remainder of neurologic examination was normal. The focal neurologic deficits resolved in 20 min. A computed tomography of the head was unrevealing. He was started on intravenous heparin under the impression of recurrent transient ischemic attacks (TIAs). Admission laboratory studies included CBC, electrolytes, electrocardiogram, and chest roentgenogram; all were normal. On hospital day 2, he developed a simple partial motor seizure in the left extremities, followed by a loss of consciousness for several minutes. Postictal paralysis in the left extremities was noted. Shortly afterward, an electroencephalogram was performed and was unremarkable. Phenytoin was placed and he had no recurrent seizures after that. A brain magnetic resonance imaging showed a focal high signal intensity lesion in the right frontal area on a T1- and T2-weighted image, suggesting an infarct with some hemorrhage (Fig. 1). The cerebral angiogram revealed superior sagittal sinus thrombosis with a marked impairment of venous return on the right side (Fig. 2). Intravenous heparin was maintained for 1 week, and then he was switched to warfarin. Follow-up magnetic resonance venogram showed recanalization of the superior sagittal sinus (Fig. 3).

The antithrombin III activity, the protein C level, and the total protein S antigen concentration were within normal limits. Other coagulation studies including fibrinogen, D-dimer, and antiphospholipid antibody were all normal. The free protein S antigen level on day 3, however, was 30% (normal, 70–140%). He was discharged symptom-free on hospital day 22. L-Asparagi-

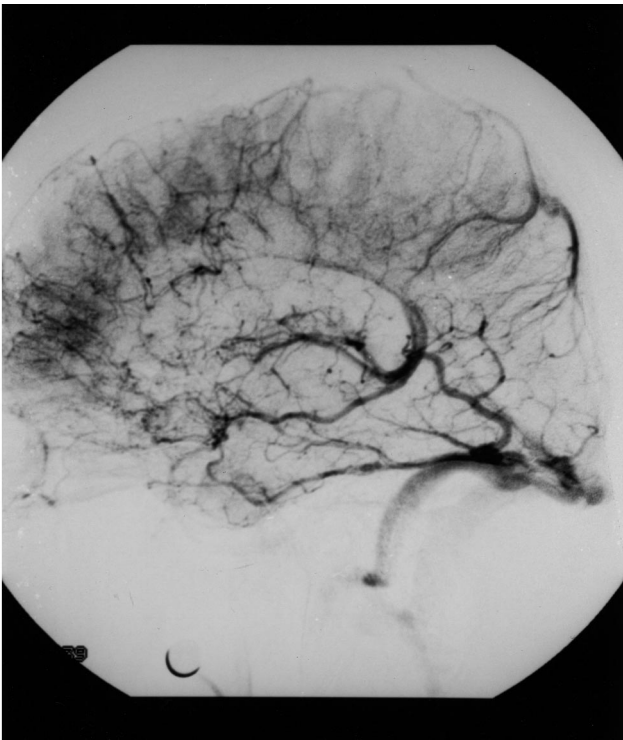


Fig. 2. Venous phase angiography demonstrates nonopacification of the entire superior sagittal sinus. There are prominent cortical veins draining to patent basal sinuses.

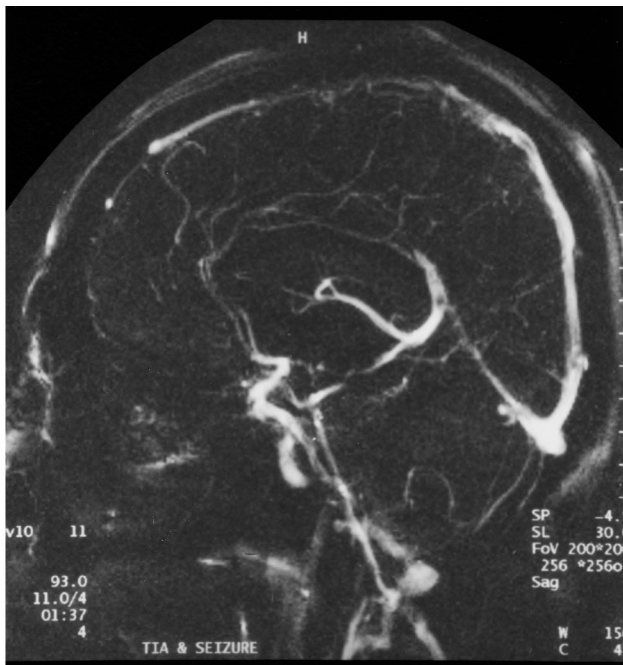

Fig. 3. Follow-up magnetic resonance venogram shows recanalization of the superior sagittal sinus.

nase was withdrawn from the consolidation regimen. Follow-up free protein S level 1 month after the stroke onset was 70%. At 2 years, he continued to be well.

### 3. Discussion

In ALL, induction therapy with L-asparaginase sometimes causes venous thrombosis [5]. L-Asparaginase hydrolyzes asparagine to aspartic acid, depleting asparagine and inhibiting protein synthesis. This inhibition is thought to be the basis of its antineoplastic effect, but it also leads to the depletion of other plasma proteins involved in coagulation and fibrinolysis [6]. Plasminogen and antithrombin III production can be interfered, tipping the equilibrium in favor of coagulation and producing deep vein thrombosis or CST. Protein S deficiency, particularly a free, active form, is also reported to be associated with CST [4]. Free protein S enhances the inactivation of factors Va and VIIIa by serving as a cofactor for activated protein C, and protein C–S complex inhibits the clotting cascade. A decrease in free protein S concentration may lead to overactivity of the coagulation system and promote thrombosis. Since free protein S, not the bound form, functions in the activation of protein C, it is necessary to estimate the free as well as the total immunoreactive protein S levels to evaluate a suspected hypercoagulable state [7].

A few instances of venous infarction due to CST have been identified in patients with protein C deficiency and antithrombin III deficiency [8,9]. Inherited protein S deficiency has also rarely been described [3,4]. Acquired free protein S deficiency has been previously reported in association with nephrotic syndrome [10], ulcerative colitis [11], multiple myeloma [12], and some infection [13]. Occasional occurrences of CST related to the treatment of ALL were known to be mostly due to high incidence of disseminated intravascular coagulation during remission induction of ALL [14]. To our knowledge, this is the first reported case of CST associated with acquired free protein S deficiency and L-asparaginase treatment. The evolution of free protein S level in our patient, initially low and then, after withdrawal of L-asparaginase, back to normal at follow up measurement, defines the association. Why there was a selective free protein S deficiency after L-asparaginase treatment, however, is unknown.

The possibility of sagittal sinus occlusion due to leukemic cell infiltration cannot be completely excluded, since a lumbar puncture was not performed in the course of intravenous heparin therapy. Even with intrathecal methotrexate and total brain irradiation, there may be some remaining nests of lymphoblasts around cerebral venous sinuses. Given that the patient may be immunosuppressed, some opportunistic infection could also be among other possibilities of cerebral sinus thrombosis. However, the dramatic disappearance of recurring symptoms after the use of heparin, recanalization of the sagittal sinus after a short period of time, and his good clinical course make those possibilities less likely.

CST is frequently asymptomatic in patients with ALL. When symptomatic, it usually presents abruptly with seizures. Focal neurologic signs may result when cerebral infarction occurs. Focal signs are heterogeneous depending on the mode of onset, their nature, and their possible association with altered consciousness. Acute cases may simulate an arterial stroke. They can be even more misleading when presenting like a TIA, as in our patient. Bousser et al. [15] reported in their review of 38 cases of CST that only one or two patients had a TIA with episodes of paresthesia and/or dysphasia lasting from 15 min to 1 h. It is unique that our patient exhibited both TIAs and a seizure at the same time as manifestations of CST. One can argue that a TIA, in fact, was a manifestation of a seizure, which developed later on. However, given the fact that during attacks, his consciousness was not impaired at all and there was no tonic or clonic movement of the involved extremities other than pure paralysis, it was most likely to be a TIA, not a seizure. The pathomechanism of these deficit (TIA) and excitation (seizure) phenomena in the same patient remains speculative. One possibility would be hemodynamic instability of the cerebral venous system in the setting of sagittal sinus thrombosis. As the thrombus obstructs the cerebral venous flow and the resultant venous hypertension develops, collateral vessels proliferate around the occluded sagittal sinus, serving as the alternative channel, as demonstrated in our patient. If the thrombus in the sinus cavity is unstable, and occlusion and recanalization of the sinus alternate, the venous hypertension would fluctuate, and the resultant edema and venous infarct could change in size and severity accordingly. In that situation, one minute it may serve as a destructive lesion causing a neurologic deficit and the next, it may act as an irritative lesion giving rise to a seizure. The transient, capricious nature of the focal cerebral signs shown in our patient might be explained on this hemodynamic basis.

This case extends the clinical spectrum of CST and the implication of free protein S deficiency. The presence of alternate TIA and seizure during a short period of time should alert the clinician to the possibility of CST. Patients with stroke complication caused by L-as-

paraginase should be tested for both the free and total protein S and other anticoagulant deficiencies.

## References

- [1] Esmon CT. The regulation of natural anticoagulant pathways. *Science* 1987;235:1348–52.
- [2] Sacco RL, Owen J, Mohr JP, Tatemichi TK, Grossman BA. Free protein S deficiency: a possible association with cerebrovascular occlusion. *Stroke* 1989;20:1657–61.
- [3] Rich C, Gill JC, Wernick S, Konkol RJ. An unusual cause of cerebral venous thrombosis in a four-year-old child. *Stroke* 1993;24:603–5.
- [4] Engesser L, Broekmans AW, Briet E, Brommer EJ, Bertina RM. Hereditary protein S deficiency: clinical manifestations. *Ann Intern Med* 1987;106:677–82.
- [5] Gugliotta I, Mazzucconi MG, Leone G, et al. Incidence of thrombotic complications in adult patients with acute lymphoblastic leukemia receiving L-asparaginase during induction therapy: a retrospective study. *Eur J Haematol* 1992;49:63–6.
- [6] Feinberg WM, Swenson MR. Cerebrovascular complications of L-asparaginase therapy. *Neurology* 1988;38:127–33.
- [7] Comp PC, Doray D, Patton D, Esmon CT. An abnormal plasma distribution of protein S occurs in functional protein S deficiency. *Blood* 1986;67:504–8.
- [8] Wintzen AR, Broekmans AW, Bertina RM, Briet E, Briet PE, Zecha A. Cerebral hemorrhagic infarction in young patients with hereditary protein C deficiency: evidence for spontaneous cerebral venous thrombosis. *Br Med J* 1985;290:350–2.
- [9] Peter GS, Linda PM, Fereshteh G, Jeffrey CA, Denis RM. Dural sinus thrombosis in children with acute lymphoblastic leukemia. *J Am Med Assoc* 1981;246:2837–9.
- [10] Song KS, Won DI, Lee AN, Kim CH, Kim JS. A case of nephrotic syndrome associated with protein S deficiency and cerebral thrombosis. *J Korean Med Sci* 1994;9:347–50.
- [11] Vaezi MF, Rustagi PK, Elson CO. Transient protein S deficiency associated with cerebral venous thrombosis in active ulcerative colitis. *Am J Gastroenterol* 1995;90:313–5.
- [12] Deitcher SR, Erban JK, Limentani SA. Acquired protein S deficiency associated with multiple myeloma: a case report. *Am J Hematol* 1996;51:319–23.
- [13] Bosson JL, Francois P, Pernod G, Carpentier P. Venous thromboembolic disease in children related to transient protein S deficiency following varicella. *Presse Med* 1995;24:415 (letter).
- [14] Sarris AH, Kempin S, Berman E, et al. High incidence of disseminated intravascular coagulation during remission induction of adult patients with acute lymphoblastic leukemia. *Blood* 1992;79:1305–10.
- [15] Bousser MG, Chiras J, Bories J, Castaigne P. Cerebral venous thrombosis: a review of 38 cases. *Stroke* 1985;16:199–213.