

Transcranial Bypass for Spontaneous Intracranial Carotid Artery Dissection

A Case Report

Y. C. Park-Matsumoto, MD, PhD*
and Toshiaki Tazawa, MD†

SAITAMA-KEN, JAPAN

ABSTRACT

A case of spontaneous intracranial artery dissection (IAD) of the anterior circulation is reported. A 32-year-old man developed left hemiparesis with headache. Angiographies (AGs) showed progressive occlusion of the distal end of the right internal carotid artery. He underwent a superficial temporal artery-middle cerebral artery anastomosis 20 days after his initial symptoms. He improved gradually after operation. The prognosis and treatment of IAD are discussed. The authors conclude that cases with IADs of the anterior circulation should be followed up by cerebral AG or magnetic resonance angiography and that early bypass surgery should be considered to prevent massive cerebral infarction in some cases.

From the *Cerebrovascular Branch, and the †Department of Neurosurgery, Akiba Memorial Hospital, Saitama-ken, Japan.

©2000 Westminister Publications, Inc., 708 Glen Cove Avenue, Glen Head, NY 11545, U.S.A.

Introduction

Spontaneous intracranial artery dissections (IADs) of the anterior circulation are relatively rare, but recently increasingly large numbers of reports have found a higher incidence than had initially been thought. Their prognosis has been believed to be catastrophic,^{1,2} but more benign cases have been reported.^{3,4} Their management remains controversial. We report here a case of spontaneous IADs of the anterior circulation and discuss their prognosis and management.

Case Report

A 32-year-old man suddenly developed right retroorbital pain during the night and noticed weakness of the left extremities in the morning. He was admitted to our hospital 6 hours after the initial symptom. At admission he had a moderate left hemiparesis. His eyes deviated conjugately to the right. He complained of right retroorbital pain and nausea. Computerized tomography (CT) on admission failed to identify any cerebral lesions. On the second day magnetic resonance

imaging (MRI) disclosed a small infarction in the region of the right internal capsule (Figure 1B) and intramural hematoma of the right internal carotid artery (ICA) (Figure 1A). Cerebral angiography (AG) showed severe stenosis of the distal end of the right ICA (string sign) (Figure 2A). From these findings the diagnosis of IAD was made. The patient's clinical deficits remained stable. On day 9, Xenon (Xe)-CT showed diffuse hypoperfusion of the right cerebral hemisphere (Figure 4A). On day 17 AG disclosed occlusion of the distal end of the right ICA (Figure 2B) and severe stenosis of proximal portions of the right middle cerebral artery (MCA) and anterior cerebral artery (ACA) (M1 and A1) (Figure 2C). Collateral circulation from the contralateral ACA was poor because of severe stenosis of right M1 and A1. Therefore, on day 20 a superficial temporal artery (STA)-MCA anastomosis was performed. Four days after operation a third AG showed good flow of the right MCA from STA (Figure 3). A month after operation a second Xe-CT showed increased perfusion of the right cerebral hemisphere (Figure 4B). His hemiparesis improved and disappeared completely.

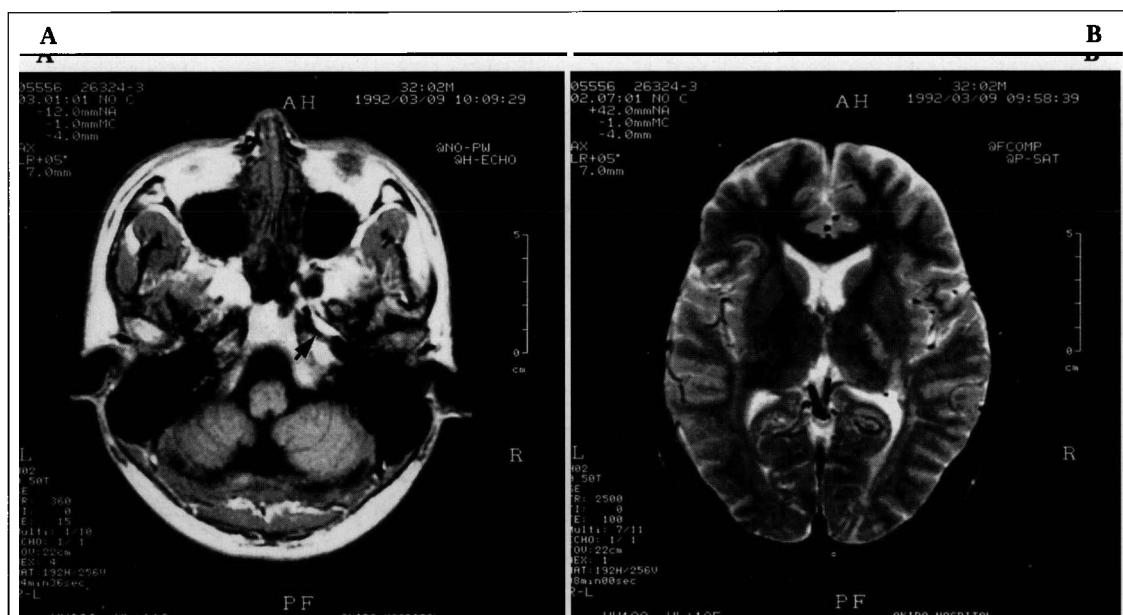


Figure 1. MRI on admission. **A.** On the second hospital day, T1-weighted MRI (TR 360/TE 15 ms) shows intramural hyperintensity in the right carotid artery (arrow). **B.** On the second hospital day, T2-weighted MRI (TR 2,500/TE 100 ms) shows hyperintensity in the right internal capsule.

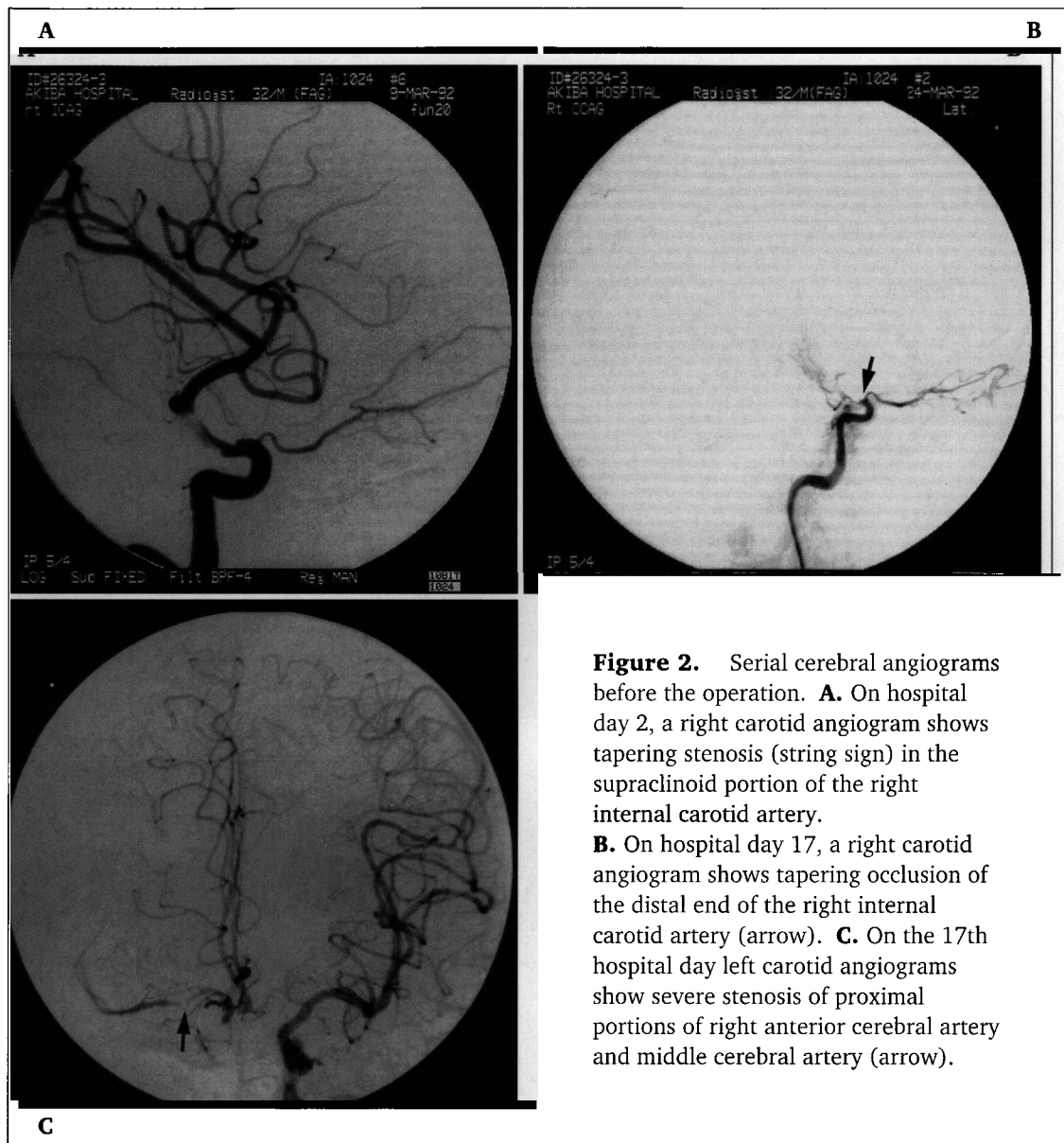


Figure 2. Serial cerebral angiograms before the operation. **A.** On hospital day 2, a right carotid angiogram shows tapering stenosis (string sign) in the supraclinoid portion of the right internal carotid artery. **B.** On hospital day 17, a right carotid angiogram shows tapered occlusion of the distal end of the right internal carotid artery (arrow). **C.** On the 17th hospital day left carotid angiograms show severe stenosis of proximal portions of right anterior cerebral artery and middle cerebral artery (arrow).

Discussion

An increasing number of cases of cerebral artery dissections (CADs) have been reported, particularly those in the posterior circulation. Most CADs present with ischemic stroke, and a minority present with subarachnoid hemorrhage (SAH) occurring preferentially in the vertebrobasilar system. Their different clinical behavior depends partly on the location of the dissection (subintimal or subadventitial). IADs of the anterior circulation

are relatively uncommon compared with those of the posterior circulation. IADs of the anterior circulation most often involve the ICA and/or MCA, and they usually cause cerebral ischemic attacks, and onset with SAH is rare.^{5,6} Usually the diagnosis of CADs is made by angiographic findings. Of these findings the reliable ones are considered to be the presence of a false lumen (double lumen or intimal flap) and a resolution of stenosis, and indirect findings are considered to be string sign, pearl and string sign, and tapered

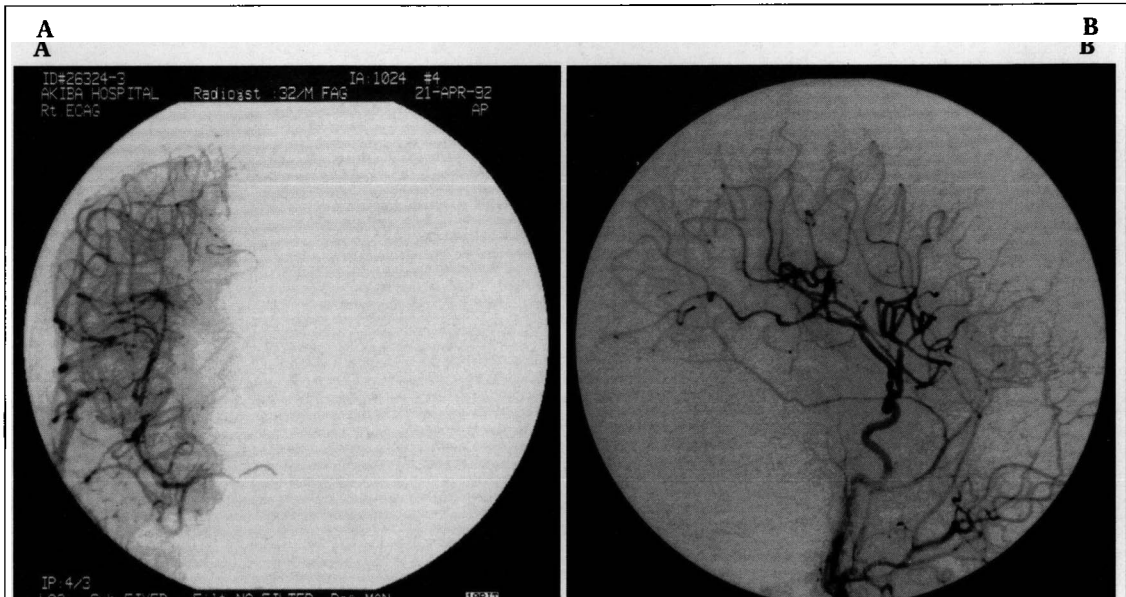


Figure 3. After the operation, a right external carotid angiogram shows good flow of the right MCA from STA (**A.** A-P view. **B.** Lateral view).

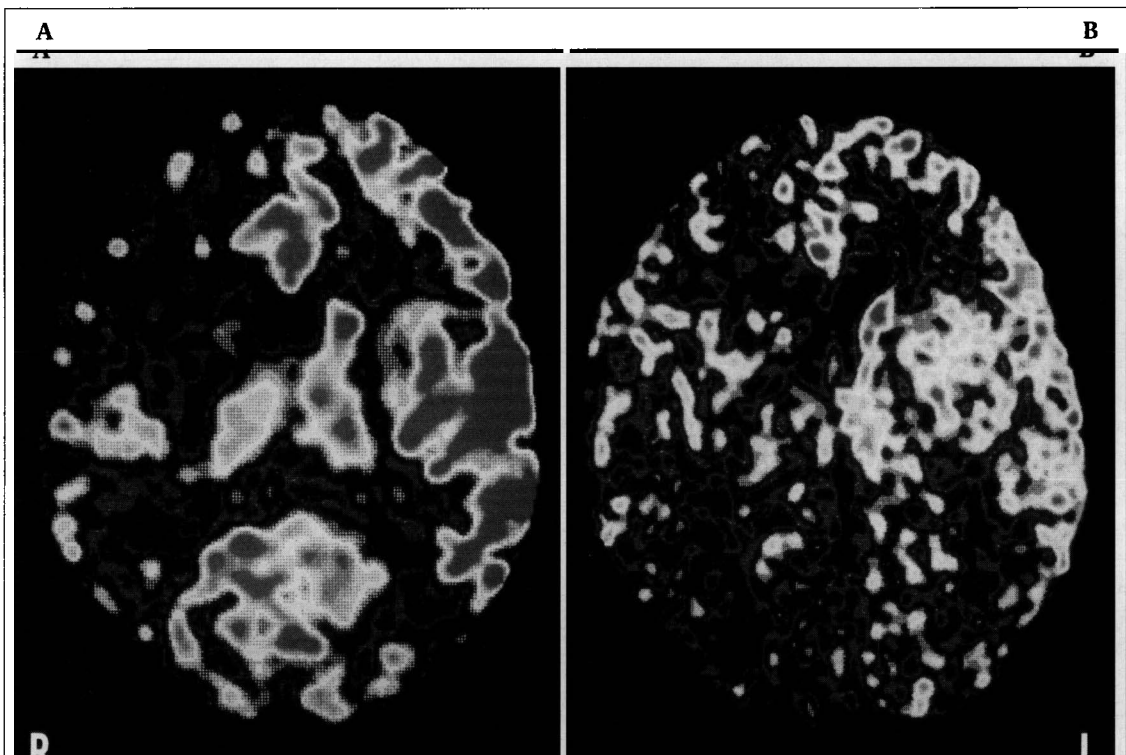


Figure 4. Mapping image of the regional cerebral blood flow with 4 minute inhalation of 30% Xenon. **A.** Before the operation, on hospital day 9, a flow map shows hypoperfusion of the right cerebral hemisphere. **B.** After the operation, on hospital day 46, a flow map shows increased perfusion of the right cerebral hemisphere. (R: right side; L: left side.)

narrowing.^{7,8} On the other hand, MRI can reveal an intramural hematoma directly as a semilunar hyperintensity and an intimal flap as a linear structure in the artery.^{9,10} These are considered reliable findings of CADs. Our case showed indirect angiographic findings, a dynamic angiographic change, and characteristic MRI findings.

Predisposing factors for spontaneous CADs include cystic or mucoid medial degeneration, fibromuscular dysplasia, Marfan's syndrome, Ehlers-Danlos syndrome, migraine, hypertension, oral contraception, arteriosclerosis, and luetic arteritis.^{11,12}

From the literature regarding IADs of the anterior circulation, they can be classified into four types according to the clinical course: in type 1 the initial attack was severe with rapid deterioration and death in several days¹³; in type 2 the initial attack was of mild or moderate severity, and the patient showed some improvement or a stable course for several days or weeks before rapid deterioration; in type 3 the patient improved gradually after the initial attack but some neurologic deficits remained or no neurologic deficits remained, in which transient ischemic attack (TIA) and reversible ischemic neurologic deficits (RIND) are included⁴; and in type 4 the patient showed only headache or no symptoms without neurologic deficits.¹⁴

Treatment of CADs remains controversial. CADs of the posterior circulation usually involve the vertebral artery and most often cause SAH. Surgical treatment, such as trapping or proximal ligation with or without extracranial-to-intracranial bypass,¹⁵ may be preferred to conservative measures. In contrast, the natural course of arterial dissections of the extracranial carotid system most often causes cerebral ischemia due to thrombosis; they are usually managed conservatively, and anticoagulant therapy may be indicated for such cases. However anticoagulant therapy seems to be contraindicated in IADs.⁸ In type 1 cases immediate bypass surgery may be indicated and in type 2 cases early bypass surgery may be indicated before deterioration. Kitani et al⁵ reported an STA-MCA bypass for spontaneous dissection in an 18-year-old man. In their patient, the first AG demonstrated diffuse stenosis extending from the supraclinoid ICA to the MCA and the patient developed progressive ischemia of the right hemisphere. They performed bypass surgery 50 hours after the initial symptoms. Neurologic deficits improved after

surgery. They suggested that early bypass surgery should be considered for a patient with poor peripheral perfusion beyond the dissecting aneurysm of the MCA and ICA. Lawner and Simeone¹⁶ reported a case in which such a bypass procedure was successfully carried out in a patient with acute intraoperative MCA occlusion who went on to recover completely with no post-operative neurologic deficits. They performed immediate bypass surgery.

Our case initially showed intracranial ICA stenosis. We watched the clinical course for about 2 weeks because in CADs spontaneous recovery has been reported.^{4,15} On hospital day 17 the second AG showed progressive occlusion of the distal ICA and poor collateral flow from the contralateral ACA. Xe-CT showed low perfusion of the right cerebral hemisphere. At this time, we feared that this patient might become a type 2 case. Therefore, on hospital day 21 we decided to carry out an STA-MCA bypass surgery before the second collapse. After bypass surgery, cerebral perfusion of the right hemisphere increased and the patient went on to recover with no neurologic deficits. In type 3 and 4 cases conservative therapy is indicated. The problem is the difficulty in differentiating type 2 from type 3 cases. We suggest that follow-up AG or magnetic resonance angiography (MRA) and cerebral blood flow study are necessary to differentiate them and that early bypass surgery should be considered for patients presenting progressive occlusion of the ICA and poor collateral flow from the contralateral ACA.

Conclusion

From our case report, we have reached the following conclusions: (1) early bypass surgery should be considered for patients of type 2, and (2) follow-up AG or MRA and cerebral blood flow study are important in deciding the prognosis and the method of treatment.

Y. C. Park-Matsumoto, MD, PhD
Cerebrovascular Branch
Akiba Memorial Hospital
5-13-10 Negishi Urawa, Saitama-ken
Japan 336

E-mail: FZX03174@niftyserve.or.jp

References

1. Farrell MA, Gilbert JJ, Kaufman JCE: Fatal intracranial dissection: Clinical pathological correlation. *J Neurol Neurosurg Psychiatry* 48:111-121, 1985.
2. Manz HJ, Vester J, Lavenstein B: Dissecting aneurysm of cerebral arteries in childhood and adolescence. Case report and literature review of 20 cases. *Virchows Arch [A]* 384:325-335, 1979.
3. Kidooka M, Okada T, Sonobe M, et al: Dissecting aneurysm of the anterior cerebral artery: Report of two cases. *Surg Neurol* 39:53-57, 1993.
4. Norman RM, Vrich H: Dissecting aneurysm of the middle cerebral artery as a case of acute infantile hemiplegia. *J Pathol Bacteriol* 73:580-582, 1957.
5. Kitani R, Itouji T, Noda Y, et al: Dissecting aneurysms of the anterior circle of Willis arteries. Report of two cases. *J Neurosurg* 67:296-300, 1987.
6. Sasaki O, Koike T, Tanaka K, et al: Subarachnoid hemorrhage from a dissecting aneurysms of the middle cerebral artery. Case report. *J Neurosurg* 74:504-507, 1991.
7. Ojemann RG, Fisher CM, Rich JC: Spontaneous dissecting aneurysm of internal carotid artery. *Stroke* 3:434-440, 1972.
8. Yonas H, Agamanlis D, Takaoka Y, et al: Dissecting intracranial aneurysms. *Surg Neurol* 8:407-415, 1977.
9. Iwama T, Andoh T, Sakai N: Dissecting and fusiform aneurysms of MR imaging. *Neuroradiology* 32:272-279, 1990.
10. Quint DJ, Spickles EM: Magnetic resonance demonstrates vertebral artery dissection: Report of two cases. *J Neurosurg* 72:964-967, 1990.
11. Gherardi GJ, Lee HY: Localized dissecting hemorrhage and arteritis. Renal and cerebral manifestations. *JAMA* 199:187-188, 1967.
12. Manz HJ, Luessenhop AJ: Dissecting aneurysm of intracranial vertebral artery: Case report and review of literature. *J Neurol* 230:15-35, 1983.
13. Duman S, Stephens JW: Post-traumatic middle cerebral artery occlusion. *Neurology* 13:613-616, 1963.
14. Piepgras DG, McGrail KM, Tazelaar HD: Intracranial dissection of the distal middle cerebral artery as an uncommon cause of distal cerebral artery aneurysm. Case report. *J Neurosurg* 80:909-913, 1994.
15. Yoshimoto T, Kamiyama H, Abe H, et al: Proximal clipping and bypass between bilateral vertebral arteries using a radial artery graft for the treatment of a dissecting aneurysm of the vertebral artery. *Surg Neurol* 36:476-481, 1991.
16. Lawner DM, Simeone FH: Treatment of intraoperative middle cerebral artery occlusion with pentobarbital and extracranial-intracranial bypass. Case report. *J Neurosurg* 51:710-712, 1979.

DISCUSSION

Ronald J. Stoney, MD
San Francisco, California

Spontaneous intracranial dissection of the arteries of the carotid circulation are uncommon, but imaging technology, particularly MRI and MRA, is identifying these lesions more frequently. Patients with this disorder have associated risk factors that are common to arterial dissection in general. These disorders of the arterial media include cystic degeneration, fibromuscular dysplasia, Marfan's syndrome and Ehlers-Danlos disorder, as well as systemic hypertension

and arterial diseases (arteriosclerosis obliterans, arteritis, and vasospasm).

The natural history is predicted by the clinical presentation of intracranial dissection of the carotid vasculature:

1. Rapid, progressive severe neurologic deterioration leading to death
2. Slower onset, mild neurologic dysfunction, a stable course then rapid deterioration and death
3. Mild onset and partial dysfunction and recovery
4. Headache without neurologic deficit

Therapy in this condition is a challenge. Conservative treatment with blood pressure lowering and anticoagulation may benefit only very mild clinical categories. Patients who survive with a stable or improving neurologic deficit appear suitable for transcranial bypass as suggested and performed by the authors in the report. Their surgical objective clearly restored distal perfusion when collateral flow was threatened and appeared inadequate. This may also eliminate the tendency to further dissection since progressive recovery without evidence of redissection has been observed in all reported bypass experience.

Spontaneous intracranial arterial dissection of the internal carotid artery or its branches in spite of its varied clinical presentations can selectively be treated by an external carotid-internal carotid (transcranial) bypass just as rare lesions of the distal cervical internal carotid artery have been successfully treated. The requirements for the application of this rare surgical procedure include state-of-the-art neurointensive care and radiologic imaging facilities as well as competent, highly trained neurologic surgeons experienced in these treatment strategies. Their goal in treatment is salvage of threatened or ischemic brain in affected patients.