

Correspondence

Hypothalamic haemorrhage and thalamus degeneration in a case of Nasu-Hakola disease with hallucinatory symptoms and central hypothermia

Sir: Nasu-Hakola disease (NHD) [2,3,8,9] is a sudanophilic leukodystrophy that affects cerebral and bone tissue. Most patients with NHD have been found in the Scandinavian Peninsula and Japan. Nasu-Hakola disease is inherited recessively and clinical features include prefrontal lobe syndrome and osteodystrophy [3,4]. Most NHD cases show axonal dystrophy and a severe fibrillary gliosis compared with the degree of demyelination, termed 'dissociation glio-myélinique', in the affected white matter [4]. Bone tissues show a unique membranocystic alteration. The pathogenesis of NHD is uncertain but a derangement of lipid metabolism [8] or cerebral angiopathy [10] have been suggested. Unusual cases of NHD, such as combination with thalamic degeneration [7], absence of osteoclastic lesions [5] and absence of fibrillary gliosis [4], have been reported. The present case was characterized by the unusual feature of hallucinatory symptoms and featured hypothermia at the end stage.

A 42-year-old Japanese man was admitted to the psychiatric service because of his inappropriate behaviour. He had been in good health until he sustained a fracture of his left tibia at age 36. It took 1 year for this fracture to recover. There were no neurological disorders reported in his family. His parents were cousins. At age 37, he experienced forgetfulness and was frequently found sprawled in the street. On admission, he appeared euphoric and exchanged banter. He complained of auditory hallucinations and was disorientated. Neurological examination disclosed gait disturbance, urinary incontinence, nominal dysplasia, dyscalculia and bilateral pyramidal signs. He scored 7/30 on Mini-Mental State Examination. His gait was 'magnetic' and he had spastic weakness in the lower limbs with extensor plantar responses. He was also incontinent. MRI showed basal ganglia calcification, enlargement of the lateral ventricles and white matter atrophy. Radiographs of his hand and foot showed a decrease in bone cortex. Bone

biopsy was performed and membranocystic lesions were found (Figure 1). He was bedridden at age 46 and was sustained with intravenous hyperalimentation. He contracted severe pneumonia from which disseminated intravascular coagulation (DIC) developed. He developed hypothermia with a reduced temperature of 34°C 2 weeks prior to his death and died at age 47.

At autopsy, fresh brain weighed 1180 g. Gross inspection revealed widening of sulci in the frontal and temporal lobes. Coronal sections revealed enlargement of the lateral ventricles. The head of the right caudate nucleus had a necrotic lesion. The cerebellum and brain stem were unremarkable. The blood vessels appeared unremarkable. The brain was perfused and fixed with 4% paraformaldehyde. Paraffin-embedded sections were cut from representative brain areas and stained with haematoxylin and

Figure 1. Membranocystic lesion of the bone marrow. Haematoxylin and eosin $\times 400$.

Figure 2. Coronal section through the globus pallidus (left side, Klüver-Barrera stain; right side, Holzer stain). Fibrillary gliosis was very prominent in the temporal white matter.

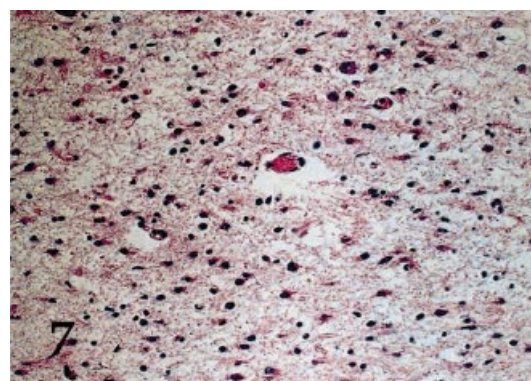
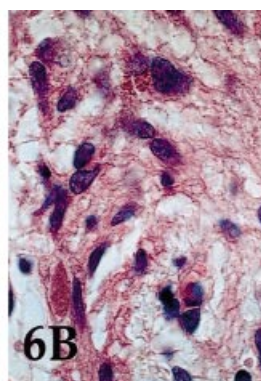
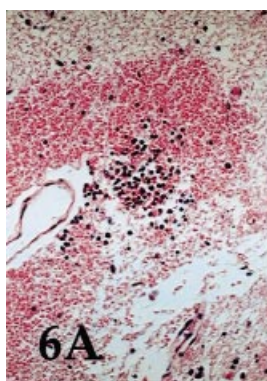
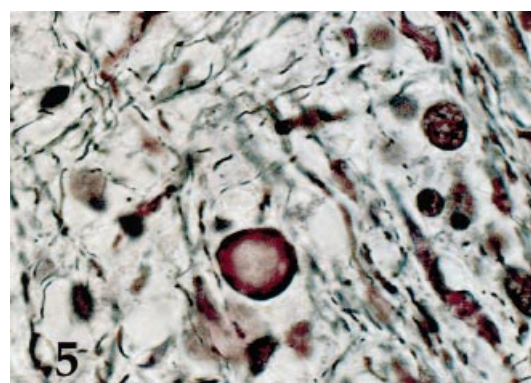
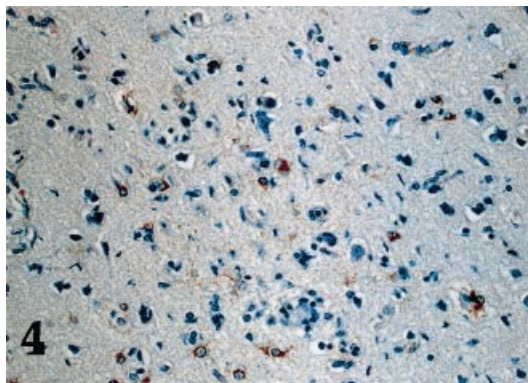
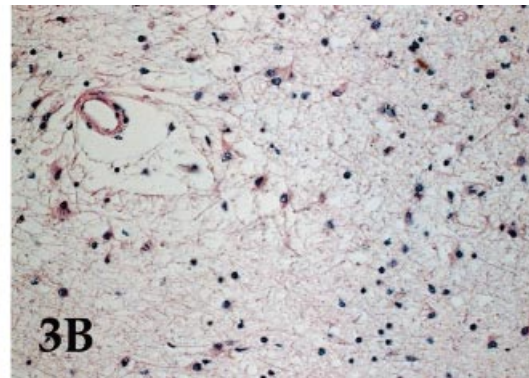
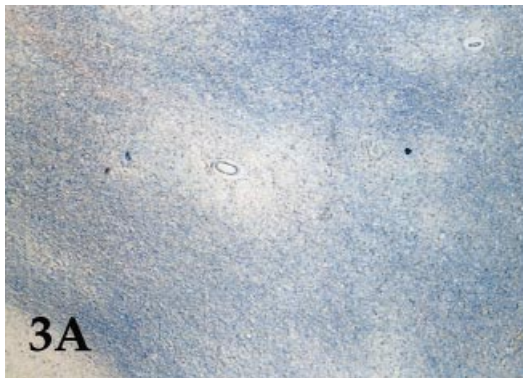
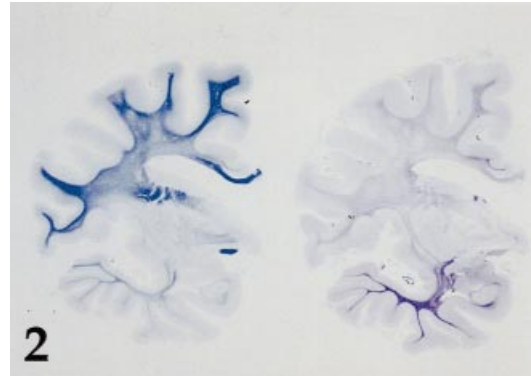
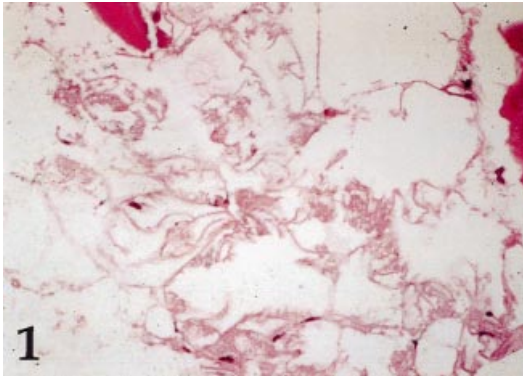
Figure 3. (a) Multiple rarefactions around the blood vessels of the frontal gliotic white matter. The U-fibres were spared from rarefaction. (b) High power of perivascular rarefaction of the frontal white matter showing many hypertrophied astrocytes and microglial cells. (a) Holzer stain $\times 40$; (b) haematoxylin and eosin stain $\times 200$.

Figure 4. Glial fibrillary acidic protein (GFAP)-positive astrocytosis around an incompletely necrotic lesion in the cerebral cortex. GFAP immunostaining counterstained with haematoxylin $\times 200$.

Figure 5. Axonal spheroids and fragmented axons. Bodian stain $\times 1000$.

Figure 6. (a) Fresh haemorrhagic lesion with leucocyte infiltration in the ventromedial nuclei of the hypothalamus. (b) High power of a macrophage aggregate in the ventrolateral nuclei of the hypothalamus. (a) Haematoxylin and eosin $\times 40$; (b) haematoxylin and eosin $\times 1000$.

Figure 7. Neuronal loss, gliosis and neuropil rarefaction in the medial nucleus of the thalamus. Haematoxylin and eosin $\times 200$.



eosin, Holzer, Bodian and Klüver-Barrera methods. Immunostaining was employed using standard techniques with monoclonal anti-neurofilament (diluted 1:300) and polyclonal antigial fibrillary acidic protein (GFAP; diluted 1:500), both from Dakopatts (Denmark).

The cerebral white matter showed intense fibrillary gliosis and demyelination. The fibrillary gliosis and atrophy were prominent in the temporal lobe white matter (Figure 2). The frontal white matter showed many densely gliotic lesions (Figure 3a) interpreted as infarcts. These areas appeared as patchy areas of rarefaction in white matter around the small vessels where many hypertrophied astrocytes and microglial cells were present (Figure 3b). The U-fibres were densely gliotic. The neuronal population of the cerebral isocortex was largely preserved but several small areas with GFAP-positive astrocytosis were found (Figure 4). The affected white matter contained many spheroids and fragmented axons (Figure 5). The spheroids were immunoreactive with neurofilament and displayed peripheral and core type staining. The globus pallidus had oval-shaped calcified material in its inner segment. An infarct was confirmed in the head of the right caudate nucleus involving the anterior limb of the internal capsule. The posterior and lateral hypothalamic nuclei showed several patchy haemorrhagic lesions. These areas showed severe tissue rarefaction in relatively new haemorrhagic lesions with associated leucocyte infiltration (Figure 6a). Older lesions with aggregation of haemosiderin-laden macrophages were present (Figure 6b). Neurones with eosinophilic change of cell bodies were seen and GFAP-positive astroglial cells were aggregated around the haemorrhagic lesions. Blood vessels with endothelial hyperplasia were absent. The mamillary body was normal. The thalamus was bilaterally affected with neuronal loss and gliosis in the medial nucleus, anterior nucleus and pulvinar (Figure 7). The hippocampus was bilaterally affected with hypoxic change showing ischaemic necrosis in the prosubiculum and cornu ammonis. The pyramidal tract of the cerebral peduncle was bilaterally demyelinated. The spinal cord showed myelin loss and astrocytic gliosis in the anterior and lateral corticospinal tracts, most prominent in the sacral and lumbar cord.

The presence of auditory hallucinations was an unusual and dominant clinical characteristic of our case. Euphoria or apathy with dementia, regarded as part

of a frontal lobe syndrome, is a psychiatric symptom common in NHD. In contrast, hallucinatory symptoms are rare and our case had a prominent temporal lobe lesion, which we speculate to be a cause of this unusual psychotic feature. Filley & Gross [1] proposed a concept of 'white matter psychosis' that generally features mood disorders but, in rare instances, paranoid and hallucinatory states were reported when the temporal lobe and limbic cortex were involved.

The hypothalamic haemorrhages can be related to the development of hypothermia [11] and are frequently found in the Wernicke–Korsakoff syndrome. However, endothelial change was slight around the haemorrhagic lesions and the mamillary body was normal; moreover our case had no thiamin deficiency. The affected hypothalamic nuclei had old and recent haemorrhagic lesions that included macrophage aggregates with haemosiderin deposition and fresh haemorrhage with leucocyte infiltration. It is likely that DIC caused the hypothalamic haemorrhages. The NHD case previously reported with thalamic degeneration [7] showed thalamic nuclei in the medial nucleus, anterior nucleus and the pulvinar affected and had no unusual clinical features. This suggests that thalamic degeneration does not produce unusual clinical features. Thalamic degeneration has been found in some leukodystrophies regardless of the combination of multisystem degeneration [6]. While the clinicopathological correlation of the initial psychotic state with the prominent temporal lobe lesion is speculative, both features are unusual in NHD.

K. Kobayashi*

E. Kobayashi*†

K. Miyazu*

F. Muramori‡

S. Hiramatsu§

T. Aoki*

I. Nakamura‡

Y. Koshino*

*Department of Neuropsychiatry,

Kanazawa University School of Medicine,

†Department of Laboratory Medicine, Tokyo Metropolitan

Neurological Hospital, Fuchu, Tokyo,

‡Ishikawa Prefectural Takamatsu Hospital, Takamatsu, Ishikawa

and

§Department of Neuropsychiatry, Noto General Hospital, Nanao,

Ishikawa, Japan

References

- 1 Filley CM, Gross KF. Psychosis with cerebral white matter disease. *Neuropsychiat Neuropsychol Behav Neurol* 1998; **5**: 119–25
- 2 Hakola HPA, Järvi OH, Sourander P. Osteodysplasia polycystica hereditaria combined with sclerosing leucoencephalopathy. A new entity of dementia presenilis group. *Acta Neurol Scand* 1970; **46**: 79–80
- 3 Hakola HPA. Polycystic lipomembranous leukoencephalopathy (membranous lipodystrophy), a neuropsychiatric follow-up study. *Psychiatr Fenn* 1990; **17**: 1–114
- 4 Harada K. Neuropathology of membranous lipodystrophy – Nasu. *Neuropathology (Suppl)* 1981; **1**: 79–86
- 5 Koizumi T, Matsubara R, Kurachi M, Isaki K, Yamaguchi N. Sclerosing leucoencephalopathy with membranocystic lesions of adipose tissue. *Neuropathology (Suppl)* 1981; **1**: 113–7 1997
- 6 Martin JJ. Degenerative diseases of the human thalamus. In *Thalamus*, Volume II, Eds M Steriade, E G Jones, D A McCormick. Amsterdam: Elsevier, 1997; 653–687
- 7 Miyazu K, Kobayashi K, Fukutani Y *et al*. Membranous lipodystrophy (Nasu-Hakola disease) with thalamic degeneration. report of an autopsied case. *Acta Neuropathol (Berl)* 1991; **82**: 414–9
- 8 Nasu T, Tsukahara Y, Terayama K. A lipid metabolic disease – ‘membranous lipodystrophy’ – An autopsy case demonstrating numerous peculiar membrane structures composed of compound lipid in bone and bone marrow and various tissues. *Acta Pathol Jpn* 1973; **23**: 539–58
- 9 Nasu T. General pathology of membranous lipodystrophy. *Neuropathology (Suppl)* 1981; **1**: 61–78
- 10 Sourander P, Järvi O, Hakola HPA, Kalimo H, Nevalainen T. Neuropathological aspects of polycystic lipomembranous osteodysplasia with sclerosing leucoencephalopathy (membranous lipodystrophy). *Neuropathology* 1981; **1** (Suppl): 87–101
- 11 Victor M, Adams RD, Collins GH. *The Wernicke–Korsakoff Syndrome*. Philadelphia: FA Davis, 1971; 20–21