

Friedrich A. M. Baumeister · Karin Auberger · Karl Schneider

## Thrombosis of the deep cerebral veins with excessive bilateral infarction in a premature infant with the thrombogenic 4G/4G genotype of the plasminogen activator inhibitor-1

Received: 25 March 1999 and in revised form: 22 June 1999 / Accepted: 15 September 1999

**Abstract** We report on a preterm infant with deep cerebral venous thrombosis, a rare condition in this age group. This premature infant had a gestational age of 33 weeks and normal development until day 18, when he presented with tonic seizures and a tense fontanelle. Ultrasound and computed tomography revealed bilateral haemorrhagic infarction of the whole region drained by the deep cerebral veins, including the periventricular white matter, thalamus and choroid plexus. The child was homozygous for the 4G allele of the plasminogen activator inhibitor-1 (PAI-1) 4G/5G promoter polymorphism.

**Conclusion** In patients with bilateral cerebral infarction, thrombosis of the deep cerebral veins should be considered. In addition the role of prothrombotic risk factors, including PAI-1 4G/5G promoter polymorphism, in cerebral vein thrombosis should be clarified in a multicentre study.

**Key words** Thrombosis · Deep cerebral veins · Preterm · Newborn · Plasminogen activator inhibitor-1

**Abbreviations** PAI-1 plasminogen activator inhibitor-1 · CT computed tomography

### Introduction

Thrombosis of the deep venous drainage of the brain has been characterised by clinical and radiographic findings in adults [2]. Reports of thrombosis of the deep cerebral veins in term newborns are rare [1, 11] and the condition has been reported in only two premature infants [11, 19].

We describe deep cerebral venous infarction in a preterm infant homozygous for plasminogen activator inhibitor-1 (PAI-1) 4G/4G promoter polymorphism,

which may constitute an additional prothrombotic factor initiating the clinical manifestation of cerebral venous thrombosis in carriers of prothrombotic risk factors [15].

### Case report

A male infant at 33 weeks of gestation was delivered by Caesarean section because of the HELLP-syndrome of the mother. The mother had abdominal pain, hypertension (150/100 mmHg), lightly

Co-investigators with Karin Auberger in the childhood thrombophilia study group were Marion Hofer, Georg Münch, Georg Simbruner (Kinderklinik und Kinderpoliklinik im Dr v. Haunerschen Kinderspital der Universität München), Ralf Junker (Institut für Klinische Chemie und Laboratoriumsmedizin, Westfälische Wilhelms-Universität, Münster), Ulrike Nowak-Göttl (Pädiatrische Hämatologie und Onkologie, Klinik und Poliklinik für Pädiatrie, Westfälische Wilhelms-Universität, Münster)

Friedrich A. M. Baumeister (✉)  
Kinderklinik und Poliklinik

der Technischen Universität München,  
Kinderklinik Schwabing, Kölner Platz 1,  
80804 München, Germany  
e-mail: u7r11cf@mail.lrz-muenchen.de  
Tel.: +49-89-30682591

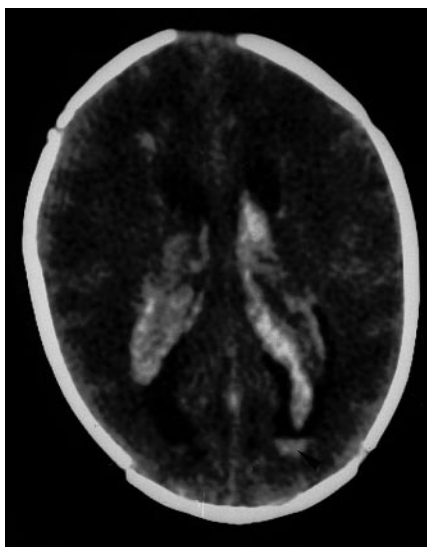
Karin Auberger · Karl Schneider  
Kinderklinik und Kinderpoliklinik im Dr v. Haunerschen  
Kinderspital der Universität München,  
Lindwurmstraße 4, 80337 München, Germany

increased alanine aminotransferase (61 U/l, normal <23 U/l), thrombocytopenia (75,000/μl) and oedema. The Apgar scores were 7 at 1 and 8 at 5 and 10 min. The infant had a birthweight of 1560 g and was in a clinically stable condition requiring ventilatory support for 3 days because of a mild respiratory distress syndrome. Polycythaemia with a venous haematocrit of 69% was treated with a partial plasma exchange transfusion on the 2nd day of life. The further postnatal course was uneventful until the 18th day of life, when unexpected sudden generalised opisthotonic seizures with extensor rigidity of the limbs occurred, together with a tense fontanelle. The haematocrit decreased from 48% to 36% within two days. The infant was lethargic and hypotonic. His pupils were equal and reactive. The sucking reflex was weak, and grasp and tendon reflexes were absent. The intermittent seizures were controlled with midazolam and later with phenobarbital. The infant gradually improved over the following 3 weeks; sucking, grasp and tendon reflexes reappeared, hypotonia decreased and he became more active. At the age of 8 months he was suffering from spastic quadriplegia, mental retardation and epileptic seizures.

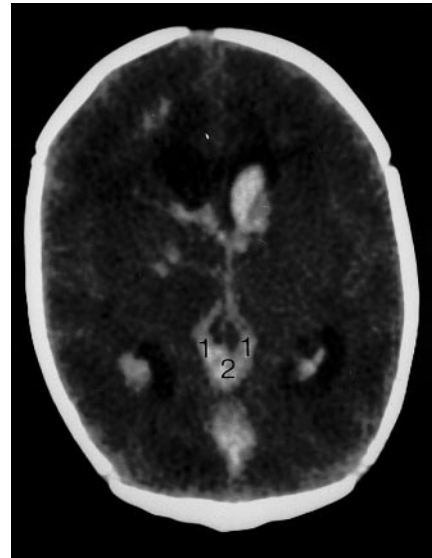
The initial ultrasound scan performed on day 3 was completely normal. An ultrasound scan immediately after the seizure on day 18 and computed tomography (CT) 12 h later revealed 1) bilateral infarction of the thalami, 2) bilateral haemorrhagic infarction of the white matter, extending from frontal to occipital, with a sharp delimitation against an unaffected subcortical area 0.5 to 1 cm below the cortex, 3) haemorrhagic infarction of the plexus in both lateral ventricles and intraventricular haemorrhage (Fig. 1), and 4) while the flow in the superior sagittal sinus was normal, duplex-scanning demonstrated no flow in the great vein of Galen, indicating venous occlusion. Thrombosis was visualised in the non-contrast enhanced CT by the abnormally hyperdense appearance of the internal cerebral veins, the vein of Galen (Fig. 2) and the straight sinus. The diagnosis of thrombosis was also supported by an increase in D-dimers up to 8 mg/l (normal <1.0 mg/l) (Nycocard) 4 days after the first seizure.

Subsequent sonographic observations demonstrated recanalization after 8 days and the development of bilateral multicystic regression in the following weeks.

The child was homozygous (4G/4G) for the deleted allele of the PAI-1 gene. PAI-1 4G/5G polymorphism was determined using a modified method of Falk et al. [8].



**Fig. 1** Cerebral spiral CT 12 h after the seizure showed diffuse hypodensity throughout both cerebral hemispheres, with haemorrhaging into the cortical white matter and into the plexus of both lateral ventricles. Blood was seen in the posterior horn of the left lateral ventricle (arrow)



**Fig. 2** Non-contrast enhanced CT revealed the thrombus in the internal cerebral veins (1) and the vein of Galen (2) through its abnormally dense appearance

The clinical evaluation and laboratory investigations excluded septicaemia, asphyxia and any abnormalities in PT (77%, normal 45–85), PTT (52.6 s, normal: 35–65) antithrombin (95%, normal 30–50), protein S (71%, normal 30–50), protein C activity (30%, normal 30–50; 8 months 75%), fibrinogen (193 mg/dl, normal 150–350), plasminogen (77%; normal 50–100), activated protein C resistance (2,27), lipoprotein (a) (5 mg/dl, normal <30), platelet count and platelet size. Mutations of factor V (G1691 A) and prothrombin (G20210 A) were excluded and maternal anticardiolipin antibodies were negative. Metabolic screening revealed normal values for lactate and homocysteine (3.7 μmol/l, normal <10). The patient was heterozygous for a mutation of the methylenetetrahydrofolate reductase gene (C<sub>677</sub> > T transition). Aminoacidopathias and organoacidurias, especially 3-hydroxyacyl coenzyme A dehydrogenase deficiency and carbohydrate-deficient glycoprotein syndrome, could be excluded. No malformation of the vena cerebri magna was demonstrated by magnetic resonance imaging.

## Discussion

This case report describes thrombotic infarction of the whole region drained by deep cerebral veins. Deep cerebral venous thrombosis during the neonatal period had already been observed in 1875, as mentioned by Ehlers [3]. However only a few reports of this condition in newborns at term and only two in premature infants have been published so far [1, 11, 19]. Compared to dural sinus thrombosis, thrombosis of the deep cerebral veins is rare [19, 20].

Thrombosis of the great vein of Galen and/or the deep cerebral veins leads to venous infarction with haemorrhagic necrotic zones in the drained regions, especially in the thalamus and the periventricular white matter [11, 12]. Because the venous drainage of the choroid plexus of the lateral ventricles occurs by way of the deep cerebral veins, thrombosis of these veins is

nearly always associated with intraventricular haemorrhage [11, 12].

Consequently a pattern of bilateral cerebral lesions affecting the thalamus, white matter and choroid plexus suggests occlusion of the vena cerebri magna and/or the deep cerebral veins.

In the premature infant described here, the diagnosis of deep cerebral venous thrombosis was confirmed by Doppler sonography and CT. The duplex scan demonstrated the absence of flow in the great vein of Galen, indicating venous occlusion, while non-contrast enhanced CT visualised the thrombus. The description differs from previous reports by the maximal extension of deep cerebral venous infarction, with bilateral lesions of the thalamus, white matter and choroid plexus associated with intraventricular haemorrhage.

The pathogenesis of cerebral venous infarction often remains unclear. It has been reported in association with coagulopathy, hyperviscosity, asphyxia, sepsis, meningitis and compression of the jugular veins [1, 11, 15, 18, 20].

A greater prevalence of prothrombotic mutations than in full-term infants has been demonstrated in pre-term infants of very low birth weight (<1500 g) [10], indicating an increased risk of thrombosis in the latter group. In the patient reported here, apart from the polycythaemia which was treated with blood-plasma exchange transfusion, the PAI-1 polymorphism (4G/4G) might be a possible risk factor for the thrombotic event.

The fibrinolytic potential of the vasculature is modulated primarily by the activity of plasminogen activators, which convert plasminogen into the fibrin-degrading enzyme plasmin. PAI-1 is a major physiological inhibitor of fibrinolysis [4, 14, 21]. The regulation of PAI-1 transcription by endothelial cells is incompletely understood. However the 4G/5G polymorphism in the PAI-1 promoter is of functional importance in regulating the expression of the PAI-1 gene under stimulation [14]. Cell culture experiments have demonstrated that the 4G allele of the PAI-1 promoter results in increased mRNA transcription in response to cytokine stimulation compared to the 5G allele, while there is little or no difference under basal conditions [14].

Patients who are homozygous for the 4G allele have higher PAI-1 levels than patients who are either heterozygous or homozygous for the 5G-allele [13, 14, 16, 21] and there is considerable evidence for the relevance of increased PAI-1 activity in thrombotic disorders [14]. In an animal model with transgenic mice, elevated levels of PAI-1 were closely associated with the development of venous occlusions [4]. In patients with familial autosomal dominantly transmitted hypofibrinolysis, high PAI-1 concentrations are associated with idiopathic osteonecrosis, which is thought to be caused by inadequate lysis of thrombin in the bone venous circulation [9]. An up-regulation of PAI-1 has been demonstrated in thrombotic microangiopathy of the kidney [22] and the 4G/4G genotype is associated with increased PAI-1 activity and myocardial infarction [5, 16].

From the available clinical data there is no certainty that an increased PAI-1 level causing poor fibrinolytic function is an independent risk factor for venous thrombosis [17, 21, 23]. However there is evidence that increased PAI-1 levels may be a particular risk for thrombotic events in association with other prothrombotic factors. Postoperative venous thrombosis is associated with impaired fibrinolysis caused by increased levels of PAI-1 [17]. Further the PAI-1 4G/4G-genotype is associated with pulmonary embolism in patients with hereditary protein S deficiency [23] and with cerebral sinus thrombosis in factor V-Leiden carriers [15].

The HELLP-syndrome of the mother is probably an additional exogenous prothrombotic factor. In patients with pre-eclampsia high levels of PAI-1 result in depressed fibrinolysis, positively correlated with the severity of placental damage [6, 7].

Further investigations should focus on the interaction of the HELLP-syndrome or pre-eclampsia with PAI-1 promoter 4G/5G polymorphism or further prothrombotic risk factors in neonatal thrombosis of the cerebral veins.

---

## References

- Barron TF, Gusnard DA, Zimmerman RA, Clancy RR (1992) Cerebral venous thrombosis in neonates and children. *Pediatr Neurol* 8:112–116
- Crawford SC, Digre KB, Palmer CA, Bell DA, Osborn AG (1995) Thrombosis of the deep venous drainage of the brain in adults: Analysis of seven cases with review of the literature. *Arch Neurol* 52:1101–1108
- Ehlers H, Courville CB (1936) Thrombosis of internal cerebral veins in infancy and childhood. *J Pediatr* 8:600–623
- Erickson LA, Fici GJ, Lund JE, Boyle TP, Polites HG, Marotti KR (1990) Development of venous occlusions in mice transgenic for the plasminogen activator inhibitor-1 gene. *Nature* 346:74–76
- Eriksson ER, Kallin B, van T Hooft FM, Bavenholm P, Hamsten A (1995) Allele-specific increase in basal transcription of the plasminogen-activator inhibitor 1 gene is associated with myocardial infarction. *Proc Natl Acad Sci USA* 92:1851–1855
- Estellés A, Gilabert J, Aznar J, Loskutoff DJ, Schleef RR (1989) Changes in the plasma levels of type 1 and type 2 plasminogen activator inhibitors in normal pregnancy and in patients with severe preeclampsia. *Blood* 4:1332–1338
- Estellés A, Gilabert J, Espana F, Aznar J, Galbis M (1991) Fibrinolytic parameters in normotensive pregnancy with intra-uterine fetal growth retardation and in severe preeclampsia. *Am J Obstet Gynecol* 165:138–142
- Falk G, Almqvist A, Nordenhem A, Svensson H, Wiman B (1995) Allele specific PCR for detection of a sequence polymorphism in the promoter region of the plasminogen activator inhibitor-1 (PAI-1) gene. *Fibrinolysis* 9:170–174
- Glueck CJ, Glueck HI, Welch M, Freiberg R, Tracy T, Hamer T, Stroop D (1994) Familial idiopathic osteonecrosis mediated by familial hypofibrinolysis with high levels of plasminogen activator inhibitor. *Thromb Haemost* 71:195–198
- Göpel W, Kim D, Gortner L (1999) Prothrombotic mutations as a risk factor for preterm birth. *Lancet* 353:1411–1412
- Govaert P, Achten E, Vanhaesebrouck P, De Praeter C, Van Damme J (1992) Deep cerebral venous thrombosis in thalamo-ventricular hemorrhage of the term newborn. *Pediatr Radiol* 22:123–127

12. Govaert P, De Vries LS, Beek FJA, van Bel F (1997) Bleeding into basal ganglia and ventricle (deep venous infarction). In: Bax MCO, Davies PA (eds) *An atlas of neonatal brain sonography*. Mac Keith Press, London, pp 207–210
13. Grubic N, Stegnar M, Peternel P, Kaider A, Binder BR (1996) A novel G/A and the 4G/5G polymorphism within the promoter of the plasminogen activator inhibitor-1 gene in patients with deep vein thrombosis. *Thromb Haemost* 84:431–443
14. Humphries SE, Panahloo A, Montgomery HE, Green F, Yudkin J (1997) Gene-environment interaction in the determination of levels of haemostatic variables involved in thrombosis and fibrinolysis. *Thromb Haemost* 78:457–461
15. Junker R, Nabavi DG, Wolff E, Lüdemann P, Nowak-Göttl U, Käse M, Bäumer R, Ringelstein EB, Assmann G (1998) Plasminogen activator inhibitor-1 4G/4G genotype is associated with cerebral sinus thrombosis in factor V leiden carriers. *Thromb Haemost* 80:706–707
16. Ossei-Gerning N, Mansfield MW, Stickland MH, Wilson IJ, Grant PJ (1997) Plasminogen activator inhibitor-1 promoter 4G/5G genotype and plasma levels in relation to a history of myocardial infarction in patients characterized by coronary angiography. *Arterioscler Thromb Vasc Biol* 17:33–37
17. Prins MH, Hirsh J (1991) A critical review of the evidence supporting a relationship between impaired fibrinolytic activity and venous thromboembolism. *Arch Intern Med* 151:1721–1731
18. Riela AR, Roach ES (1993) Etiology of stroke in children. *J Child Neurol* 8:201–220
19. Rivkin MJ, Anderson ML, Kaye EM (1992) Neonatal idiopathic cerebral venous thrombosis: an unrecognized cause of transient seizures or lethargy. *Ann Neurol* 32:51–56
20. Shevell MI, Silver K, O’Gorman MO, Gordon VW, Montes JL (1989) Neonatal dural sinus thrombosis. *Pediatr Neurol* 5:161–165
21. Wiman B (1995) Plasminogen activator inhibitor 1 (PAI-1) in plasma: its role in thrombotic disease. *Thromb Haemost* 74:71–76
22. Xu Y, Hagege J, Mougenot B, Sraer J-D, Ronne E, Rondeau E (1996) Different expression of the plasminogen activation system in renal thrombotic microangiopathy and the normal human kidney. *Kidney Int* 50:2011–2019
23. Zöller B, Garcia de Frutos P, Dahlbäck B (1998) A common 4G allele in the promoter of the plasminogen activator inhibitor-1 (PAI-1) gene as a risk factor for pulmonary embolism and arterial thrombosis in hereditary protein S deficiency. *Thromb Haemost* 78:802–807