

# Neglect and Constructive Disorder

SHI Qijia (施琪嘉)

Department of Neurology, Tongji Hospital, Tongji Medical University, Wuhan 430030

Feng Jianhua (冯建华)

Red Cross Hospital, Qinhai 810000

YANG Ming (杨敏)

Local Hospital, Xinyang, Henan 464100

CHANG Liying (常丽英)

Department of Neurology, Central Hospital, Xiangfan, Hubei 441021

**Summary:** A 61 year-old right handed man, who suffered from right cerebral infarction with evidences of visual-spatial neglect and constructive disorder, was reported. When copying simple geometric designs, he omitted to copy figures on the left side of the page; he tended to bisect the line to the right of the line's real center; after memorizing the familiar pictures he mainly mentioned the pictures on the right side of the page; when copying the "Rey Complex" he also ignored the structures on the left side. The relations of the neglect and construction disorder are discussed.

**Key words:** neglect; constructive apraxia; visual-spatial disorder

## 1 CASE REPORT

A sixty-one years-old man was admitted because of left limbs weakness for 2 days. The patient had the sudden tumbling without headache and loss of consciousness, and soon he developed left limb weakness and dysarthria.

With unilateral gazing to the right side, the patient's head was toward to the right on examination. He had left facial, tongue and limbs palsy (strength: 0/5). Cranial CT showed the cerebral infarction in the dominant area of the right hemisphere.

## 2 RESULTS

### 2.1 Aphasia Examination

Aphasia Test developed by the affiliated hospital of Beijing Medical University was conducted in the first week after onset and no aphasic symptoms were found.

### 2.2 Visual Neglect Examination

**2.2.1 The Line Bisection Test<sup>[2]</sup>** The result was 2C14R (fig. 1), e. g. the written lines were 14 times inclined to the right sides, 2 times at the middle and 4 times ig-

nored (the ignored lines were all located in the left visual field of the patient).




Fig. 1 The Line Bisection Test

**2.2.2 Vernea Test<sup>[2]</sup>** The patient was asked to fulfilled the three "X" into a box. He showed a tendency of right fulfilling (fig. 2)

**2.2.3 Writing Ability Examination** His writing was normal (fig. 3).

**2.2.4 Meaning Pictures Recall Test** The pictures the patient recalled were: star, clock, arrow, question mark, raining and smile face (fig. 4).

### 2.2.5 Description of Symmetric Picture

The patient identified 6 windows in the right side, 12 in the left sides and he painted an arrow on the right side (fig. 5).

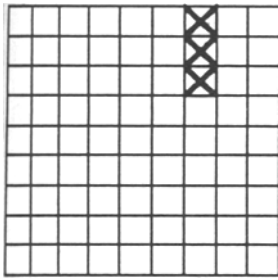


Fig. 2 Vernea test

湖北武汉同济医科大学同济医院

Fig. 3 The patient's writing



Fig. 4 Meaning Pictures Recall Test



Fig. 5 Description of symmetric pictures. The structures on the left side were ignored (fig. 6).

2.3 Constructive Test

Rey Complex Figure<sup>[2]</sup> was employed and the patient's score was 7 (normal score

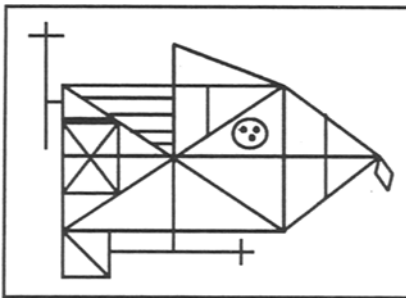
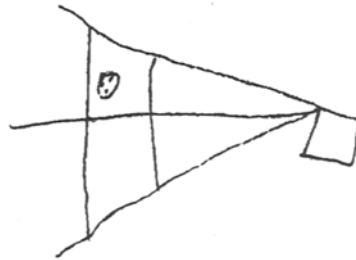


Fig. 6 Rey complex figure and patient's presentation



2.4 Match Test and Tri-dimensional Test

The patient failed to perform the "Match Test" and "Tri-dimensional Test" (fig. 7).

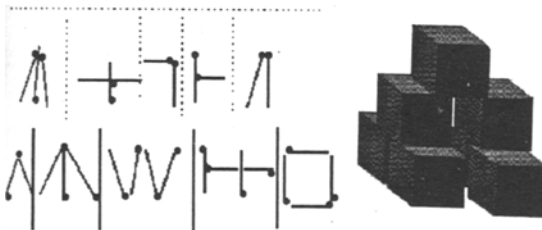


Fig. 7 "Match Test" and "Tri-dimensional Test"

3 DISCUSSION

"Visual-spatial neglect Syndrome" was defined first by Oppenheimer (1883) and Holmes<sup>[3]</sup> as the phenomenon of "neglect" or "ignorance" to the contralateral visual stimulus of the brain lesion side. Clinically,

the patients with the lesion on the right hemisphere showed no responses or postponed reaction to the stimulus coming from the contralateral side of visual field, which were also defined as "agnosia of opposite half of space". This was verified in our case by Line Bisection Test (fig. 1), Verneer Test (fig. 2), Meaning Pictures Recall Test (fig. 4), and symmetric picture Describing Test (fig. 5). It was believed, that the lesion involving the right frontal, temporal and central lobes could result in neglect, the real neglect was in close relation to the lesion of the central lobe of the non-dominant hemisphere, although the neglect was seen after central lobe onset in the dominant hemisphere<sup>[4]</sup>. According to the Battersby's review, 33 % patients with the neglect had lesions located in the temporal and central lobes of the non-dominant hemisphere, whereas 20 % were located in the frontal and central lobes. Mesulam suggested that the ocular motor abnormality in relation to the frontal lesion presented the obstacle to the contralateral visual field scanning, so-called "automatic attention diminishment" (frontal neglect)<sup>[5]</sup>. Our case showed unilateral gazing to the right side, with the lesions in the right hemisphere, and the gazing was soon improved after one week. So his neglect could be the real neglect.

The patient had constructive problems. He failed to complete Rey complex test, Match Test and the three-dimensional test. The phenomena was described as "Constructive apraxia", a combined disorder of sensation-motor reaction involving the central lobe. Dee reported 42 cases of visual-space disorders among 46 patients with con-

structive apraxia<sup>[4]</sup>.

While our case had severe neglect and constructive symptoms, his writing ability was preserved (fig. 3), with up-deviation from left to right side. It was described by Wang, that the visual-spatial writing disorder of Chinese patient was caused by the thalamus and central or occipital lobes lesions of the non-dominant hemisphere<sup>[6]</sup>. It is said, that the Chinese characters are integrated in both hemispheres, and since the left hemisphere of our case was preserved, his symptoms improved after one week, so the constructive related agraphia was not presented by our case. Our case suggested that the Chinese patients would have a good outcome of their visual-spatial disorder, as the Chinese characters are built constructively. By the same token, Chinese agraphia may get better prognosis, since the Chinese scripts are thought to be integrated bilaterally.

#### REFERENCES

- 1 高素荣. 失语症. 北京:北京医科大学协和医科大学联合出版社,1993,p265-280.
- 2 Cronbach L J. Essentials of Psychological Testing. 4th ed. New York:Harper & Row,1984. p35.
- 3 Halsband U. Unilateral spatial neglect and defective performance in one half of space. J Neurosciences, 1985, 28:173
- 4 Walsh K W. Neuropsychology. 汤慈美,方俐洛,王新德译. 北京:科学出版社, 1987. p219-223.
- 5 Mesulam M M. A cortical network for directed attention and unilateral neglect. Annals of Neurology, 1981,10(4):309
- 6 王新德. 中国失语症的研究. 中华神经精神杂志,1986,19:109

(Received July 10, 1997)