

'Herald hemiparesis' of basilar artery occlusion: early recognition by transcranial Doppler ultrasound

J. Montaner, C. Molina, J. Alvarez-Sabin and A. Codina

Stroke Unit, Department of Neurology, Hospital Vall d'Hebrón, Pg. Vall d'Hebron 119-129, 08035 Barcelona, Spain

Keywords:

basilar thrombosis, herald hemiparesis, transcranial Doppler ultrasound

Received 20 May 1999

Accepted 3 September 1999

A transient hemiparesis may be occasionally present at an early stage of the thrombosis of the basilar artery (herald hemiparesis). We report on one of these cases and the valuable role of transcranial Doppler ultrasound (TCD) to the early detection of the stroke-in-evolution. TCD in the emergency room is a good tool to assess a basilar occlusion, searching for direct (absence of signal at the basilar artery) and indirect (reversal flow of the pre-communicating segment of posterior cerebral artery through the posterior communicating artery) signs. Early recognition and treatment of this condition could avoid the development of the full syndrome of the basilar artery thrombosis.

Introduction

A transient hemiparesis may be occasionally present at an early stage of the thrombosis of the basilar artery. Liu *et al.* (1983) described three patients who had presented with dysarthria and unilateral sensory or motor deficit which then evolved or progressed. The point of their article was to call attention to the misleading early presentation due to basilar artery disease and the later progression of deficit. Tuhim *et al.* (1984) reported the frequency of initial unilateral hemiparesis in 15 of 59 brainstem infarctions of which 10 progressed. This fact was nicely described by Fisher (1988), who named it 'herald hemiparesis'. We report one of these cases and the valuable role of transcranial Doppler ultrasound (TCD) to the early detection of the stroke-in-evolution. Early recognition and treatment of this condition could avoid the development of the full syndrome of the basilar artery thrombosis.

Case report

MC is a 34-year-old female who has suffered from migraine (without previous aura) since she was young. Oral contraceptives were used by the subject for 10 years. She has never used triptans. No other cardiovascular risk factor was present. The patient was referred to our hospital because of a sudden onset occipital headache with nausea and vomiting, followed some minutes later by a severe dysarthria and right-sided hemiparesis. Upon arriving at the emergency room, a neurological examination assessed the deficit and its total resolution two hours after the onset of symptoms.

At that moment TCD showed an absence of signal corresponding to basilar artery at insonation depth of between 80 and 100 mm by suboccipital approach. In addition, an inversion of flow in both pre-communicating segments of the posterior cerebral artery (PCA) with elevated velocities (150 cm/s) and an ortograde flow (from carotid artery to PCA) in both posterior communicating arteries (PcomA) was observed when a transtemporal approach was used (Figure 1a). These findings were suggestive of an occlusion of the basilar artery and anticoagulant therapy was started. A cerebral angiography performed 24 h later confirmed the diagnosis, showing a complete occlusion of the basilar artery between the origin of the anteroinferior cerebellar artery and the superior cerebellar artery (Figure 1b). When the flow through both internal carotid arteries was studied, the top of the basilar was filled through a patent posterior communicating artery (mainly at the right side) and we could observe posterior cerebral arteries and superior cerebellar arteries. Magnetic resonance imaging showed no parenchymal infarction. The patient remains asymptomatic. Magnetic resonance angiography follow-up showed the recanalization of the basilar artery three months later.

Discussion

Hemiparesis may be present in different syndromes of the vertebrobasilar system. In this case we focus on the hemiparesis of impending basilar artery occlusion, herald hemiparesis, as described by Fisher. This hemiparesis is often mild when the patient is seen in the emergency room and may precede the tetraplegia with coma or a locked-in state. Early detection of herald hemiparesis is by no means easy, because usually

Correspondence: J. Montaner at the above address.

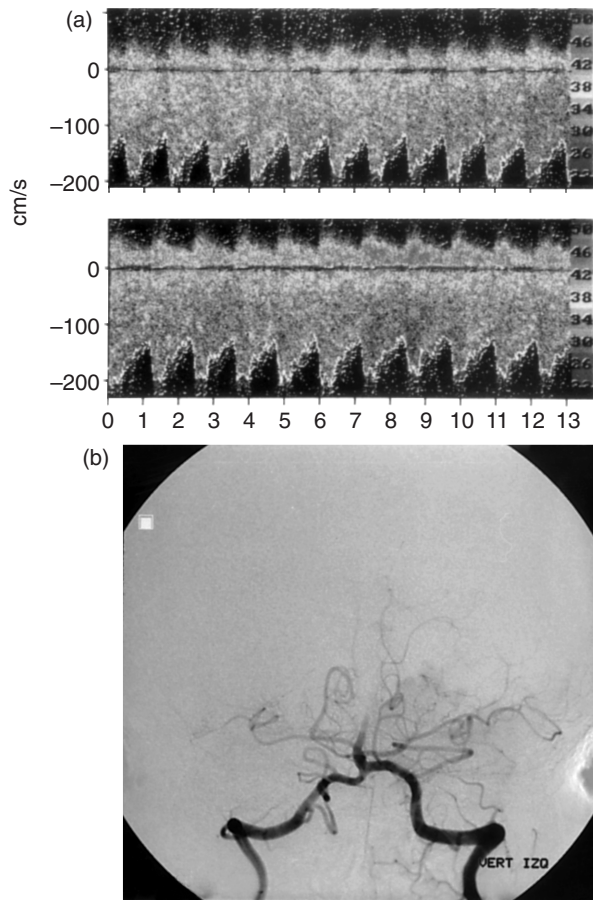


Figure 1 (a) TCD showing an orthograde flow in both posterior communicating arteries with elevated velocities. (b) A cerebral angiography, confirming the basilar artery occlusion.

this situation suggests that the vascular lesion lies in the cerebral hemisphere rather than in the brain stem. A high degree of suspicion and a minor brain-stem signs search is required. The occurrence of transient ischemic attacks of vertigo, dizziness, diplopia or hemiplegia, sometimes on alternating sides in the previous days or weeks, suggest vertebrobasilar ischemia. In a patient with hemiparesis the presence of severe dysarthria, bilateral extensor plantar responses, horizontal nystagmus, slight cerebellar dysmetria in the contralateral limbs and myoclonic jerks (Miwa *et al.*, 1992) should be considered as warning signs to indicate the herald hemiparesis with subsequent severe brainstem infarction. An occipital headache at stroke onset is another clinical clue.

The origin of the occlusion may be a unilateral thrombosis of paramedian basilar branches and several hours later the growing thrombus blocks the orifice of the paramedian basilar branch of the other side of the pons. Although basilar migraine, basilar dissection or

vasospasm were included in the differential diagnosis, our patient did not fulfil clinical and radiological criteria for them.

Strategies to detect this syndrome should include TCD after a computed tomography (CT) scan has ruled out an intracerebral haemorrhage. Previously, Doppler sonography has shown its usefulness in suspected basilar artery occlusion by detecting a pattern of high-resistance flow in the vertebral arteries, which normally have a low-resistance flow, with normal carotid arteries (Garcia Guijo *et al.*, 1994). Extracranial and intracranial Doppler sonography has been used to confirm or exclude suspected acute basilar artery occlusion (Ringelstein *et al.*, 1985). Unfortunately, considerable technical limitations of Doppler sonography, especially in the diagnosis of basilar artery occlusion, has not been overcome until now. The detection of the PcomA with the use of TCD is very difficult because the small dimensions of the vessel often necessitates the use of compression manoeuvres (Bass *et al.*, 1990). TCD is able to indirectly assess collateral flow through the PcomA if elevated flow velocity is found in the pre-communicating segment of the PCA and normal or reduced values are found in the post-communicating segment (Schneider *et al.*, 1988). New techniques as transcranial colour-coded duplex sonography (Klötzsch *et al.*, 1996) and CT angiography (Brandt *et al.*, 1999) will help to improve the diagnosis of basilar artery occlusion.

At present, TCD in the emergency room, is a good tool to assess a basilar occlusion, searching for direct (absence of signal at the basilar artery) and indirect signs (reversal flow of the pre-communicating segment of PCA through PcomA).

These findings lead us to confirm the diagnosis made angiography and to initiate anticoagulant or thrombolytic treatment.

References

- Bass A, Krupski WC, Dille RB, Bernstein EF, Otis SM (1990). Comparison of transcranial and cervical continuous-wave doppler in the evaluation of intracranial collateral circulation. *Stroke* **21**:1584–1588.
- Brandt T, Knauth M, Wildermuth S *et al.* (1999). CT angiography and doppler sonography for emergency assessment in acute basilar artery ischemia. *Stroke* **30**:606–612.
- Garcia Guijo C, Rubio G, Jimenez Ortiz C (1994). Herald hemiparesis of basilar artery occlusion suggested by doppler sonography. *Am J Roentgenol* **162**:238.
- Klötzsch C, Popescu O, Berlitz P (1996). Assessment of the posterior communicating artery by transcranial color-coded duplex sonography. *Stroke* **27**:486–489.
- Liu J, Tuhir S, Weinberger J, Song SK, Anderson PJ (1983). Premonitory symptoms of stroke in evolution to the

- locked-in state. *J Neurol Neurosurg Psychiatry* **46**:221–226.
- Fisher M (1988). The 'Herald Hemiparesis' of basilar artery occlusion. *Arch Neurol* **45**:1301–1303.
- Miwa H, Hirasawa M, Yoshino H, Hayashi Y, Mizuno Y (1992). The early hemiparesis of stroke in evolution of basilar artery. Case report. *No Shinkei* **44**:49–52.
- Ringelstein EB, Zeumer H, Poeck K (1985). Noninvasive diagnosis of intracranial lesions in the vertebrobasilar system. A comparison of Doppler sonographic and angiographic findings. *Stroke* **16**:848–855.
- Schneider PA, Rossman ME, Bernstein EF, Torem S, Ringelstein EB (1988). Effect of internal carotid artery occlusion on intracranial hemodynamics. Transcranial Doppler evaluation and clinical correlation. *Stroke* **19**:589–593.
- Tuhim S, Banko M, Price TR (1984). A syndrome that predicts worsening in brainstem infarction. *Neurology* (Suppl 1):165.