

# DISSECTING ANEURYSM OF THE ANTERIOR CHOROIDAL ARTERY: ANGIOGRAPHICAL AND MR IMAGING FINDINGS

Hideki Matsuura, M.D., Yasunari Otawara, M.D., Michiyasu Suzuki, M.D., and Akira Ogawa, M.D.

*Department of Neurosurgery, Iwate Medical University, Morioka, Japan*

Matsuura H, Otawara Y, Suzuki M, Ogawa A. Dissecting aneurysm of the anterior choroidal artery: angiographical and MR imaging findings. *Surg Neurol* 2000;53:334–6.

## BACKGROUND

Intracranial dissecting aneurysms are relatively rare. We present a rare case of a dissecting aneurysm originating from the anterior choroidal artery; this is the first reported case.

## CASE DESCRIPTION

A 42-year-old man suffered sudden onset of right hemiparesis and dysarthria. Computed tomography on admission revealed a small low density area in the posterior limb of the internal capsule. MR imaging revealed aneurysmal dilatation of the anterior choroidal artery, and angiography revealed aneurysmal dilatation and stasis of dye in the venous phase at the anterior choroidal artery, which resolved in the chronic stage.

## CONCLUSION

We describe a rare case of a dissecting aneurysm of the anterior choroidal artery. The radiological findings were characteristic of dissecting aneurysms in spite of the rare location. © 2000 by Elsevier Science Inc.

## KEY WORDS

*Dissecting aneurysm, anterior choroidal artery, radiological diagnosis.*

**I**ntercranial dissecting aneurysms are relatively rare. They have been reported in the vertebral artery [1], internal carotid artery, anterior cerebral artery [2,3], middle cerebral artery [4], posterior cerebral artery [5], and posterior inferior cerebellar artery [6], but not the anterior choroidal artery.

We describe a case of dissecting aneurysm of the anterior choroidal artery. The radiological findings

were characteristic of dissecting aneurysms despite the rare location.

## CASE REPORT

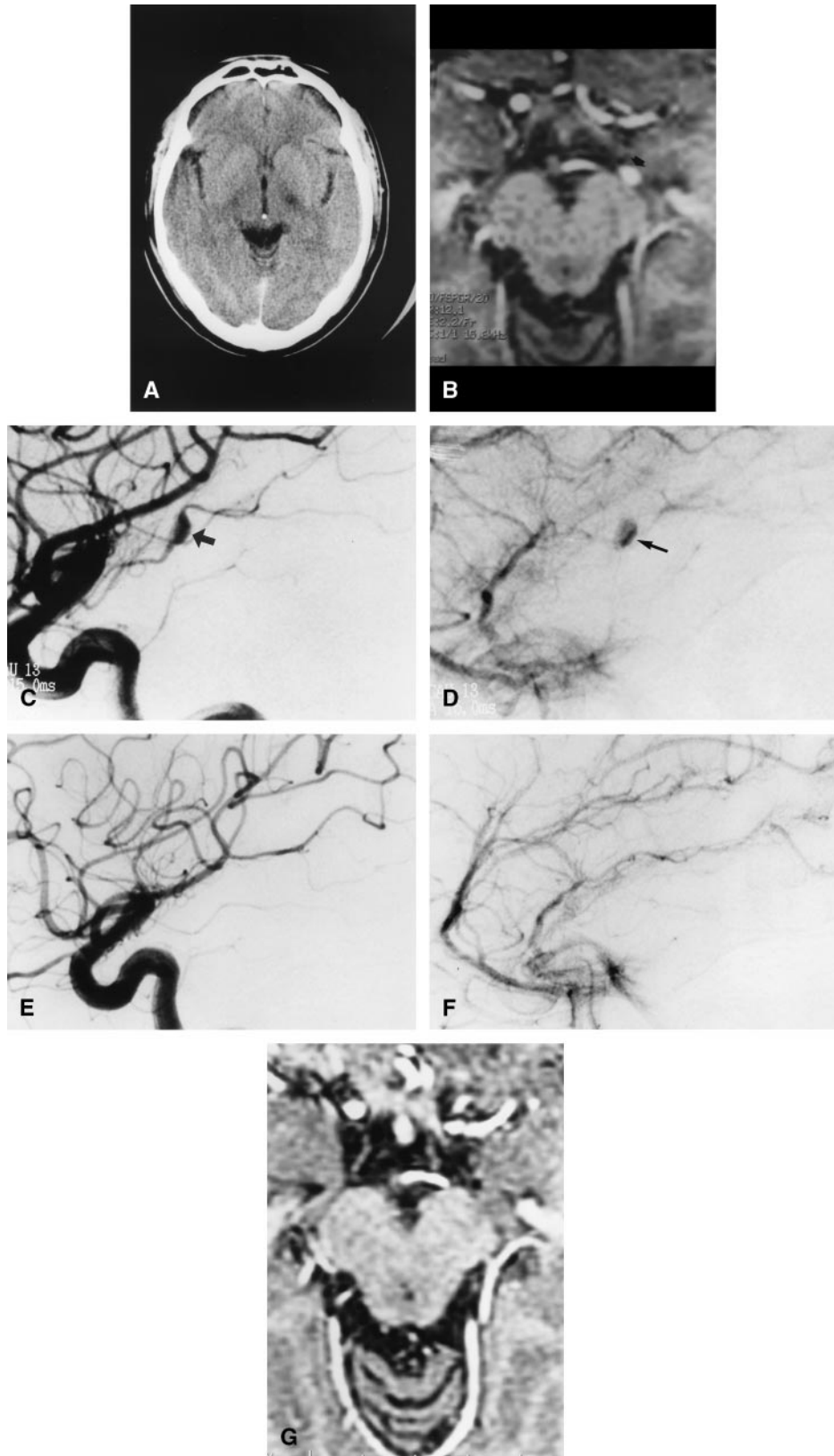
A 42-year-old man suffered sudden onset of right hemiparesis and dysarthria when driving a car. He was admitted to our institute on the second hospital day. Neurological findings on admission were right hemiparesis, dysarthria, and right facial nerve palsy. No sensory disturbances or hemianopsia were observed. He did not have a history of myocardial disease or systemic inflammatory disease.

Computed tomography (CT) on admission revealed a small low density area in the posterior limb of the internal capsule (Figure 1A). Magnetic resonance (MR) imaging was performed by using T1-weighted (340/12 [TR/TE]) spin-echo, T2-weighted (2800/105 [TR/effective TE]) fast spin echo, and spoiled GRASS (SPGR) sequences. T2-weighted MR imaging revealed a small high signal intensity area in the posterior limb of the internal capsule. SPGR imaging revealed an aneurysmal dilatation of the left anterior choroidal artery (Figure 1B).

Left carotid angiography on admission revealed an aneurysmal dilatation (Figure 1C) and stasis of dye in the venous phase (Figure 1D) at the anterior choroidal artery. Angiographical findings on Day 21 showed no change. Anti-coagulation therapy and rehabilitation allowed good neurological recovery. Angiography showed no aneurysmal dilatation or stasis of dye on Day 118 (Figures 1E and 1F). Repeat MR imaging 1 year later showed no aneurysmal dilatation of the left anterior choroidal artery (Figure 1G).

Inflammatory findings such as increased body

Address reprint requests to: Dr H. Matsuura, Department of Neurosurgery, Iwate Medical University, 19-1 Uchimarui, Morioka 020-8505, Japan.  
Received May 11, 1999; accepted October 22, 1999.



**1** A 42-year-old man with dissecting aneurysm of the anterior choroidal artery. (A), Computed tomography on admission revealed a small low density area in the posterior limb of the internal capsule. (B), Spoiled GRASS MR image revealing an aneurysmal dilatation (open arrow) of the left anterior choroidal artery. (C), Arterial phase digital catheter angiogram on admission showing an aneurysmal dilatation (arrow) of the left anterior choroidal artery. (D), Venous phase digital catheter angiogram on admission showing stasis of dye in the venous phase (arrow). (E), Arterial phase digital catheter angiogram on Day 118 showing disappearance of the aneurysmal dilatation of the left anterior choroidal artery. (F), Venous phase digital catheter angiogram on Day 118 showing disappearance of the stasis of dye in the venous phase. (G), Spoiled GRASS MR image 1 year after onset revealing no aneurysmal dilatation of the left anterior choroidal artery.

temperature, white blood cell count, or C-reactive protein, were not noted during the hospitalization.

## DISCUSSION

Dissecting aneurysm of the anterior choroidal artery has not been reported so far. This is the first reported case.

MR imaging is generally believed to provide the final diagnosis of dissecting aneurysm. MR imaging detects intramural hemorrhage as a thickened vessel wall with a narrowed lumen, surrounded by a semilunar-shaped eccentric hyperintense signal from the mural hematoma [2]. These findings were not present in our case. SPGR images could not show the false lumen, but did demonstrate the aneurysmal dilatation. This finding had disappeared a year later. In this case, MR imaging could provide only a probable diagnosis.

Angiography is generally recognized as the "gold standard" for diagnosing arterial dissection [7]. The angiographical findings are characteristic: luminal narrowing ("string sign"), double lumen ("intimal flap"), pearl-and-string sign, pseudo-aneurysm, and total occlusion [3,7,8]. These findings usually disappear and the normal arterial caliber is restored one to three months later [7]. Angiography of our case showed pseudo-aneurysm and stasis of dye, which had disappeared 4 months later. These findings provide the diagnosis of dissecting aneurysm.

Recently, the trend has been for diagnosis to be based on noninvasive methods such as MR imaging. However, MR imaging provided only a probable diagnosis in this case. The diagnosis of dissecting aneurysm of relatively small vessels may require both angiography and MR imaging.

## REFERENCES

1. Friedman AH. Arterial dissections. In: Wilkins RH, Rengachary SS, eds. *Neurosurgery*. 2nd ed. New York: McGraw-Hill, 1996:2173-6.

2. Guillon B, Levy C, Bousser MG. Internal carotid artery dissection: An update. *J Neurol Sci* 1998;153:146-58. 145-8.
3. Jafar JJ, Kmiryo T, Chiles BW, Nelson PK. A dissecting aneurysm of the posteroinferior cerebellar artery: Case report. *Neurosurgery* 1998;43:353-6.
4. Maillo A, Diaz P, Morales F. Dissecting aneurysm of the posterior cerebral artery: Spontaneous resolution. *Neurosurgery* 1991;29:291-4.
5. Otawara Y, Suzuki M, Abe M, Tomizuka N, Ogawa A. Dissecting aneurysms of the anterior cerebral artery and accessory middle cerebral artery. *Neurosurg Rev* 1997;20:145-8.
6. Sekino H, Nakamura N, Kato Y, Basugi N. Dissecting aneurysms of the vertebro-basilar system: Clinical and angiographic observation. *No Shinkei Geka* 1981;9: 125-3.
7. Sharif AA, Remley KB, Clark HB. Middle cerebral artery dissection: A clinicopathologic study. *Neurology* 1995; 45:1929-31.
8. Yasui T, Sakamoto H, Kishi H, Komiyama M, Iwai Y, Yamanaka K, Nishikawa M. Bilateral dissecting aneurysms of the vertebral arteries resulting in subarachnoid hemorrhage: Case report. *Neurosurgery* 1998;42: 162-4.

---

## COMMENTARY

I am always skeptical of those who claim to be presenting the initial case of something. In this instance, however, I think it is likely that this is a unique case and, in any event, the superb quality of the images and the very convincing findings justify its publication. I frankly would not have treated the patient with anticoagulation, although there is a widely-held view that this is an effective therapy for acute dissections. However, one cannot argue too strongly with success and the patient reported here did well.

**Bryce Weir, M.D.**  
*Section of Neurosurgery*  
*University of Chicago*  
*Chicago, Illinois*