

# Transcatheter Snare Removal of Acute Middle Cerebral Artery Thromboembolism: Technical Case Report

Bohdan W. Chopko, M.D., Ph.D.<sup>1</sup>, Charles Kerber, M.D.<sup>2</sup>, Wade Wong, D.O.<sup>2</sup>, Bassem Georgy, M.D.<sup>2</sup>

<sup>1</sup>Department of Surgery, Division of Neurological Surgery, University of California at San Diego Medical Center, San Diego, California

<sup>2</sup>Department of Radiology, University of California at San Diego Medical Center, San Diego, California

## ABSTRACT

### OBJECTIVE AND IMPORTANCE

We describe the case of a patient in whom a snare designed for the removal of foreign bodies was successfully used to retrieve a thromboembolism from the middle cerebral artery. This technique can be used to reestablish blood flow when maximal pharmacological therapies have failed.

### CLINICAL PRESENTATION

A 38-year-old man with scrotal squamous cell carcinoma presented with the abrupt onset of left hemiparesis and numbness. Computed tomography of the head showed no hemorrhage or hypodensity, and right middle cerebral artery thrombosis was suspected.

### INTERVENTION

Cerebral angiography demonstrated a near-total occlusion of the right middle cerebral artery at the M1–M2 junction. The administration of

**Key words:** Abciximab, Endovascular, Snare, Stroke, Thrombolysis, Urokinase

**Received:** October 14, 1999

**Accepted:** January 11, 2000

Intra-arterial approaches to the treatment of acute cerebral arterial thromboembolism are far from perfectly effective, and situations may arise in which standard pharmacological and mechanical disruption strategies fail. We report the use of an intra-arterial snare to remove a fresh middle cerebral artery clot that remained hemodynamically significant, despite multiple thrombolytic maneuvers.

### CLINICAL PRESENTATION

A 38-year-old man, known to have scrotal squamous cell carcinoma, had the sudden onset of left hemiparesis. Fifty minutes later, at an emergency department evaluation, the patient was awake and alert, and exhibited profound paresis of the left upper extremity, moderate paresis of the left lower extremity, and a left central facial palsy. A sensory examination demonstrated diminished pinprick sensation along the left hemicorpus inferior to the neck. The results of a computed tomographic scan were unremarkable, except for increased density in the right middle cerebral artery. We decided to proceed with cerebral angiography and intra-arterial thrombolysis.

intra-arterial urokinase, systemic heparin, and systemic abciximab, and mechanical maceration failed to lyse the clot. A 4-mm gooseneck snare was guided through a microcatheter, and the clot was snared and withdrawn. Immediate postoperative angiography demonstrated the reconstitution of normal flow. Pathological examination of the snared material was consistent with clot. By postoperative Day 5, the patient had regained full strength, except for the fingers of the left hand, which remained moderately weak. Computed tomography demonstrated a right insular and extreme capsular infarct.

### CONCLUSION

To our knowledge, this is the first reported use of a snare to remove clot in the setting of thromboembolic stroke. As the use of intra-arterial thrombolysis increases, transcatheter snare removal of pharmacologically resistant clot may be considered as a salvage strategy.

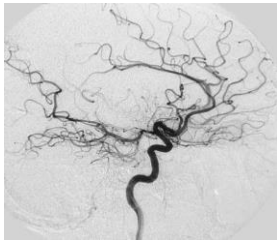
### INTERVENTION

The angiographic procedure began 4.5 hours after the onset of symptoms. A cerebral angiogram, obtained with the patient under general anesthesia, revealed a near-total occlusion of the middle cerebral artery at the M1–M2 junction (Fig. 1). The patient was systemically heparinized and maintained throughout the procedure with an activated clotting time greater than 200 seconds. A 0.018-inch microcatheter system was placed through a 6-French delivery catheter into the terminal region of the right internal carotid artery. Multiple passes were made through the clot with a 0.018-inch guidewire. Next, urokinase (Abbokinase; Abbott Laboratories, North Chicago, IL) was infused through the microcatheter at various positions distal, within, and proximal to the major occlusion. After the administration of 750,000 U of urokinase, most of the occlusion remained. At this point, a loading dose (0.25 mg/kg intravenously) of abciximab (ReoPro; Eli Lilly and Co., Indianapolis, IN) was administered and then a continuous infusion (10 µg/h intravenously) was given. Further maceration of the clot was performed with the guidewire, and an additional 250,000 U of urokinase were administered. Despite these

efforts, a major occlusion persisted (Fig. 2). At this point, 6.5 hours had elapsed since symptom onset. A 4-mm gooseneck snare (Amplatz; Microvena Corp., White Bear Lake, MN) was then used to retrieve the clot, in two separate snaring maneuvers (Fig. 3), which led to an immediate reconstitution of flow (Fig. 4). For each maneuver, the snare was gently tightened around the clot and then the microcatheter and guiding catheter were withdrawn as a unit. Pathological evaluation of the snared material revealed blood clot, with no evidence of tumor.

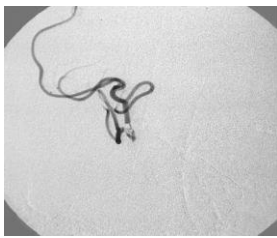
**FIGURE 1.**

Right internal carotid angiogram obtained at the time of presentation, lateral view, midarterial phase, showing a significant perfusion defect in the middle cerebral artery territory.



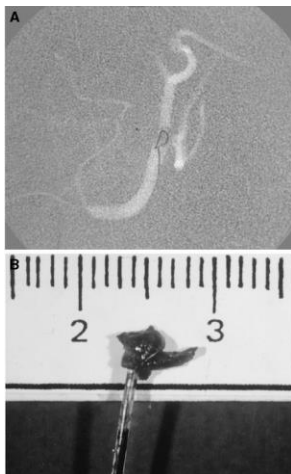
**FIGURE 2.**

Angiogram of the proximal right middle cerebral artery obtained after superselective injection, demonstrating persistent occlusion, despite treatment with mechanical disruption and administration of 1,000,000 U of intra-arterial urokinase, systemic heparin, and systemic abciximab.



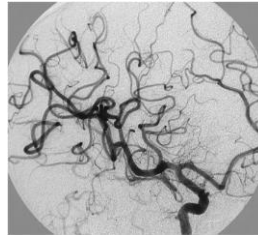
**FIGURE 3.**

A, Angiogram showing the 4-mm snare, deployed within the middle cerebral artery and maneuvered to encircle the clot. B, photograph of the clot contained within the snare, immediately after removal from the delivery catheter. Scale is in cm.



**FIGURE 4.**

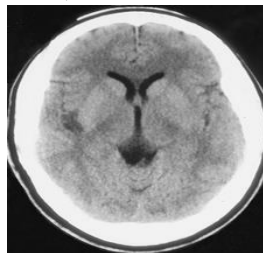
Right internal carotid angiogram, oblique view, performed immediately after snare removal of the clot, demonstrating the complete reconstitution of flow through the area of prior blockage.



The patient was awakened immediately after the procedure and within 2 hours had regained significant strength. A computed tomographic scan of the head, performed at the end of the procedure, showed a focal high density in the right sylvian fissure, which disappeared within 6 hours and was interpreted to be contrast staining. By postoperative Day 5, the patient had normal strength in the left lower and proximal left upper extremities, and mild left hand weakness. The sensory disturbance had resolved, except for numbness in the distal left upper extremity. Head computed tomography demonstrated a small infarct in the right insula, claustrum, and extreme capsule (Fig. 5).

**FIGURE 5.**

Noncontrast computed tomographic scan obtained on postoperative Day 5, showing that despite excellent angiographic results and functional recovery, a circumscribed infarct, centered within the right insula, was evident.



## CONCLUSION

Case reports of the successful snare retrieval of foreign bodies, such as detachable coils and catheter fragments, from cerebral vessels have been described<sup>(4,6,7)</sup>. A recent article also details the use of a snare in one patient to remove clot from within a dural sinus<sup>(5)</sup>. To our knowledge, however, the retrieval of intra-arterial clot using a snare has not been reported. The use of the snare carries significant risks, including vessel rupture and loss of control of the snared material leading to embolization and fragmentation. In addition, the selection of snare size is critical. We chose a snare diameter larger than that of the occluded vessel, anticipating snare elongation upon deployment, to ensure complete clot entrapment. Because of these technical issues, we suggest that the use of the snare be reserved for extraordinary situations after more conventional means have failed. With the advent of studies that demonstrate the benefits of intra-arterial thrombolysis, such as the Prolyse in Acute Cerebral Thromboembolism trials<sup>(1-3)</sup>, sponsored by Abbott Laboratories, we can anticipate a larger caseload; thus, increasing numbers of patients will set the stage for the development of alternative strategies for flow reconstitution when pharmacology fails.

## REFERENCES

1. Connors JJ III, Wojak JC Current directions in emerging stroke therapy, in Connors JJ III, Wojak JC (eds): *Interventional Neuroradiology: Strategies and Practical Techniques*. Philadelphia, W.B. Saunders Co., 1999, pp 629–644.
2. del Zoppo GJ, Higashida RT, Furlan AJ, Pessin MS, Rowley HA, Gent M PROACT: A phase II randomized trial of recombinant pro-urokinase by direct arterial delivery in acute middle cerebral artery stroke. *Stroke* 29:4–11, 1998.
3. Furlan AJ, Higashida R, Wechsler L, Gent M, Rowley H, Kase C, Pessin M, Ahuja A, Callahan F, Clark WM, Silver F, Rivera F Intra-arterial pro-urokinase for acute ischemic stroke: The PROACT II study—A randomized controlled trial: Prolyse in Acute Cerebral Thromboembolism. *JAMA* 282:2003–2011, 1999.
4. Halbach VV, Dowd CF, Higashida RT, Balousek PA, Ciricillo SF, Edwards MS Endovascular treatment of mural-type vein of Galen malformations. *J Neurosurg* 89:74–80, 1998.
5. Philips MF, Bagley LJ, Sinson GP, Raps EC, Galetta SL, Zager EL, Hurst RW Endovascular thrombolysis for symptomatic cerebral venous thrombosis. *J Neurosurg* 90:65–71, 1999.
6. Standard SC, Chavis TD, Wakhloo AK, Ahuja A, Guterman LR, Hopkins LN Retrieval of a Guglielmi detachable coil after unraveling and fracture: Case report and experimental results. *Neurosurgery* 35:994–998, 1994.
7. Watanabe A, Hirano K, Mizukawa K, Kamada M, Okamura H, Suzuki Y, Ishii R Retrieval of a migrated detachable coil: Case report. *Neurol Med Chir (Tokyo)* 4:247–250, 1995.

## COMMENTS

Chopko et al. report their experience with a 38-year-old man with squamous cell carcinoma of the scrotum who presented with left hemiparesis and numbness associated with an embolic event, most likely the result of a hypercoagulable state related to his malignancy. Despite the exhaustive use of thrombolytics, including urokinase, heparin, and ReoPro (Eli Lilly and Co., Indianapolis, IN), recanalization was minimal. Mechanical disruption of the clot, as originally reported by Dodder, is often useful in this situation; however, in that patient, the addition of a snare led to a remarkable recovery. I think that a snare is potentially useful, although, as the authors indicate, the intracranial use is not totally benign. The authors helped their patient with a relatively innovative approach.

**Robert H. Rosenwasser**  
*Philadelphia, Pennsylvania*

The authors have presented an excellent report of the use of a snare after an apparently suboptimal result with thrombolytic agents for an occluding middle cerebral artery thromboembolus. They successfully used a gooseneck endovascular snare for clot removal. Their description highlights the importance of using alternative methods when pharmacological agents fail, for whatever reason, to dissolve clot. In this case, the embolus may have been mature.

**George P. Teitelbaum** *Interventional Neuroradiologist*  
*Los Angeles, California*

The administration of intra-arterial thrombolytics results in complete clot lysis in almost half of all patients with ischemic stroke; in the other half, it results in partial or no recanalization<sup>(2)</sup>. The heterogeneous composition of the clot and vascular pathological conditions, such as atherosclerotic stenosis underlying the thrombus,

are implicated in the relative failure of pharmacological agents. Mechanical lysis of the clot using balloon catheters has been reported to promote the frequency of recanalization<sup>(1,3)</sup>. Mechanical disruption of clot also enhances the penetration of thrombolytics into the clot matrix. The biggest concern with mechanical disruption of clot is the possibility of embolization of clot fragments into the distal vasculature.

The use of transcatheter snares to withdraw clot from the occluded artery is another concept that needs evaluation. A transcatheter snare may be placed in intravascular sites where passage of balloon catheters is not feasible. The use of a snare device may also limit distal embolization of clot fragments because there is less mechanical rupture, compared with angioplasty. Two important aspects should be considered before the use of these devices. Arterial tortuosity may be a limiting factor in preventing successful passage of the device to the occlusion site. Furthermore, snare devices are designed to hold solid objects, such as catheter or wire fragments, whereas clots are fragile structures that may fragment as the snare loop closes. A modification of the retrieval device design may overcome this limitation. At present, the use of a transcatheter snare device may be considered if there is no response to standard thrombolysis. Further administration of thrombolysis and/or platelet IIb/IIIa inhibitors may be necessary to prevent distal embolization after mechanical manipulation of the thrombus.

**Adnan I. Qureshi**  
**L. Nelson Hopkins**  
*Buffalo, New York*

1. Ringer AJ, Fessler RD, Qureshi AI, Guterman LR, Hopkins LN: Intracranial angioplasty for arterial occlusion resistant to thrombolysis in acute stroke. *J Neurosurg* 92:211, 2000 (abstr).
2. Suarez JJ, Sunshine JL, Tarr R, Zaidat O, Selman WR, Kernich C, Landis DMD: Predictors of clinical improvement, angiographic recanalization, and intracranial hemorrhage after intra-arterial thrombolysis for acute ischemic stroke. *Stroke* 30:2094–2100, 1999.
3. Ueda T, Sakaki S, Nochi I, Kumon Y, Kohno K, Ohta S: Angioplasty after intraarterial thrombolysis for acute occlusion of intracranial arteries. *Stroke* 29:2568–2576, 1998.

This technical case report describes the mechanical retrieval of an acute thromboembolus to the middle cerebral artery, after treatment with intra-arterial lytic therapy and ReoPro failed to adequately open up a middle cerebral artery occlusion. The patient significantly improved after the clot was snared, as a result of the establishment of reperfusion.

This technique has been previously reported at meetings by interventional neuroradiologists from the Cleveland Clinic and Emory University. However, this appears to be the first published, documented case. When pharmacological intervention does not establish adequate reperfusion during an acute ischemic stroke, other types of intervention may be warranted. In this case, it significantly helped to establish reperfusion efficaciously by snaring out the clot. With newer types of mechanical devices on the horizon, including early trials of intracranial balloon angioplasty, stents, suction/vacuum devices, thrombectomy catheters, and laser devices, it is possible that more patients may benefit from early, acute intervention procedures, either with lytic agents or mechanical devices, for the treatment of ischemic stroke.

**Randall T. Higashida** *Interventional Neuroradiologist*  
*San Francisco, California*