

Brief Report

Neurologic manifestations of cerebral air embolism as a complication of central venous catheterization

Josef G. Heckmann, MD; Christoph J. G. Lang, MD; Klaus Kindler, MD; Walter Huk, MD; Frank J. Erbguth, MD; Bernhard Neundörfer, MD

From the Departments of Neurology (Drs. Heckmann, Lang, Kindler, Erbguth, and Neundörfer) and Neuroradiology (Dr. Huk), University of Erlangen-Nuremberg, Germany.

Address requests for reprints to: Josef G. Heckmann, MD, Department of Neurology, University Erlangen-Nuremberg, Schwabachanlage 6, 91054 Erlangen, Germany.

Objective, Patients, and Methods: A severe case of cerebral air embolism after unintentional central venous catheter disconnection was the impetus for a systematic literature review (1975-1998) of the clinical features of 26 patients (including our patient) with cerebral air embolism resulting from central venous catheter complications.

Results: The jugular vein had been punctured in eight patients and the subclavian vein, in 12 patients. Embolism occurred in four patients during insertion, in 14 patients during unintentional disconnection, and in eight patients after removal and other procedures. The total mortality rate was 23%. Two types of neurologic manifestations may be distinguished: group A (n = 14) presented with encephalopathic features leading to a high mortality rate (36%); and group B (n = 12) presented with focal cerebral

lesions resulting in hemiparesis or hemianopia affecting mostly the right hemisphere, with a mortality rate as high as 8%. In 75% of patients, an early computed tomography indicated air bubbles, proving cerebral air embolism. Hyperbaric oxygen therapy was performed in only three patients (12%). A cardiac defect, such as a patent foramen ovale was considered the route of right to left shunting in 6 of 15 patients (40%). More often, a pulmonary shunt was assumed (9 of 15 patients; 60%). For the remainder, data were not available.

Conclusion: When caring for critically ill patients needing central venous catheterization, nursing staff and physicians should be aware of this potentially lethal complication.

KEY WORDS: central venous catheterization; cerebral air embolism; embolism; complication; adverse effect

Air embolism is a rare cause of stroke, occurring in a number of situations such as trauma, hemodialysis, oral-genital sexual relations in women, childbirth, high altitude accidents, diving accidents, open heart surgery, thoracotomy, pneumoradiologic procedures, arterial angiography, and neurosurgery (1-6). Previously, diagnosis was made by signs

and symptoms occurring during a high-risk setting. In isolated cases, the introduction of computed tomographic (CT) scan made it possible to show air bubbles in the brain (1, 4).

Cerebral air embolism after central venous catheterization procedures is a rare but hazardous complication (1, 3, 4, 7). In the literature are two reviews, one on 24

patients (8) and another on 79 patients (9). In both reports, however, the authors did not differentiate between cerebral air embolism and embolism in other locations. In other reviews, only general clinical and experimental considerations of venous air embolism are reported (10-12).

Few data exist on the neurologic features of cerebral air embolism after central venous catheterization. The aim of this article is two-fold: first, a severe case of cerebral air embolism in relation to accidental disconnection of a central venous catheter is reported; and second, all published cases of cerebral air embolism after central venous catheterization in the literature between 1975 and 1998 are reviewed in a systematic way. We hope to provide information that will allow clinicians to recognize the condition more readily, to intervene more promptly, and to prevent this hazardous complication, whenever possible.

Case Report, Patients, and Methods

A 72-yr-old man was receiving cardiological care after aortocoronary bypass surgery after myocardial infarction and angiography-documented coronary artery disease. There was no intraoperative complication. A postoperative pneumothorax was treated immediately via a thoracic drain. Three days later, the drain was successfully removed. The patient was in stable cardiopulmonary condition and without neurologic deficits when transferred to the cardiological department for further recovery.

In the evening, 14 days later, the patient unintentionally disconnected the central venous catheter and was found unresponsive to verbal and noxious stimulation. All limbs were paretic. Deep tendon reflexes were symmetrical, and plantar reflexes were extensor bilaterally. The patient's cardiopulmonary condition was stable. Because continuous heparin had been given, an intracerebral hemorrhage was initially

assumed, and the patient was transferred at midnight to a radiologic institution where CT scan was available. An intracerebral hemorrhage was excluded, but unfortunately, the CT results were misinterpreted. Small air bubbles in the right hemisphere were not detected (Fig. 1, *arrows*). The chest radiograph performed later was unremarkable with regard to a hemo- or pneumothorax.

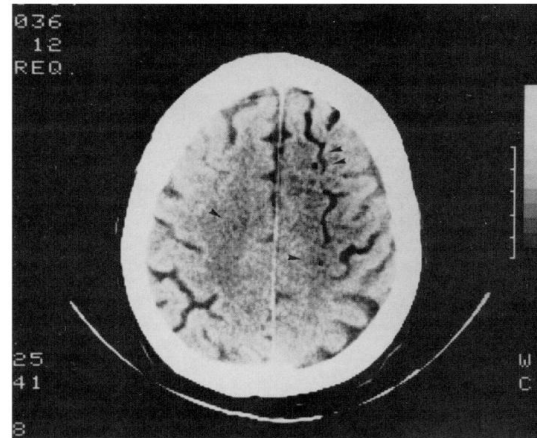


Figure 1. Cerebral computed tomography 3 hrs after onset of signs and symptoms. Multiple air bubbles are seen more prominently in the right hemisphere subarachnoid vessels.

The patient remained in a severe tetraparesis and akinetic mutism, leading to a first neurologic consultation. The control CT indicated prominent hypodense lesions of the right hemisphere, minor lesions of the left frontotemporal region, and very mild lesions in both hypothalamic areas (Fig. 2). Consequently, the first CT was reviewed and the air bubbles were detected. Air embolism was documented by using measurement in (-16) Hounsfield units (1, 4). At this time, a specific treatment with hyperbaric oxygen was not considered to be of value and, therefore, was not performed.

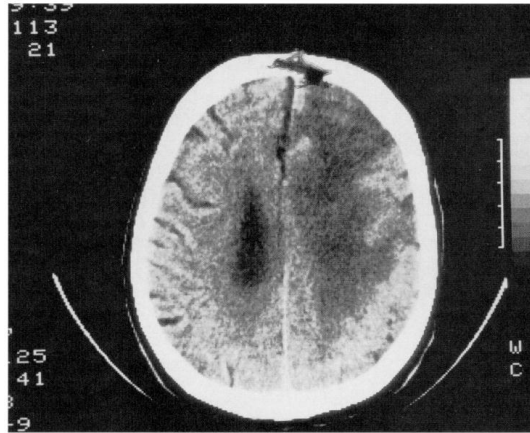


Figure 2. Follow-up computed tomography 3 days later showing hypodense lesion of the right hemisphere.

A presurgical coronary catheter investigation demonstrated severe proximal coronary artery stenosis of the left anterior interventricular branch and the left intermediate branch. Ventriculography demonstrated hypokinesia of the anterolateral wall. There were no hints of a patent foramen ovale or similar right-to-left shunts.

Three months later, the patient was still in akinetic mutism, without signs of neurologic improvement. Focusing on this problem, we performed an extensive literature search (MEDLINE, Index Medicus, Excerpta Medica, Psychological Abstracts, Chemical Abstracts, and Current Contents) under the headings "central venous catheterization," "central venous," "catheterization," "cerebral air embolism," "cerebral air," "air," "embolism" for the years 1975-1998. All available data including follow-up examinations were evaluated. Central venous catheterization procedures, clinical symptomatology, treatment, course, CT findings, and cardiac findings were transformed into homonymous terms and broken down into tables containing the most relevant clinical features (Table 1). Stress was placed on the type of catheterization procedures, the clinical manifestation of cerebral air

embolism, neuroradiologic findings, cardiological findings, and the course of the disease. In some cases, conflicting or missing data could not be resolved; in other cases, data had to be simplified for tabulation.

Table 1. Relevant clinical findings, 1975 to 1998

	Age (yr)	Gender	Type of CV Procedure	Cerebral Manifestations
Group A				
Ponsky and Porjes, 1971 (7)	61	M	Disconnection, CVL	Coma, seizures
Grace, 1977, c. 1 (26)	52	F	Disconnection, SV	Coma
Grace, 1977, c. 2 (26)	58	F	Disconnection, SV	Coma
Michel et al., 1982 (27)	72	M	Disconnection, IJV	Coma
Houng et al., 1983 (1)	75	M	Insertion, SV	Coma
Jensen and Lipper, 1986, c. 1 (13)	29	M	Disconnection, SV	Coma
Neubauer et al., 1988 (28)	54	M	Disconnection, IJV	Coma
Phifer et al., 1991 (29)	62	F	Removal, IJV	Coma
Turnage and Harper, 1991, c. 2 (30)	67	M	Removal, IJV	Sopor
Ploner et al., 1991 (31)	68	M	Disconnection, SV	Coma
Menzin et al., 1992 (32)	73	M	Removal, IJV	Coma
Alkous et al., 1995 (33)	73	F	Insertion, SV	Tetraplegia
Schlatterbeck et al., 1997 (17)	79	M	Insertion, SV	Coma
Hackmann et al., 1998	72	M	Disconnection, SV	Super, tetraparesis
Group B				
Merkin and Schwartzman, 1977, c. 4 (3)	52	M	Disconnection, CVL	Hemianopia, seizures
Mader and Haid, 1979 (2)	33	F	Air injection, AV	Hemiparesis, hemianopia
Jacobsen et al., 1983 (15)	19	M	Disconnection, SV	Hemiparesis
Karim et al., 1984, c. 1 (34)	60	M	Disconnection, SV	Hemianopia, hemihyposthesia
Kearns et al., 1984, c. 2 (34)	63	M	Removal, CVL	Hemianopia
Jensen and Lipper, 1986, c. 2 (13)	34	F	Disconnection, CVL	Hemiparesis, stupor
Dilkes et al., 1991 (14)	23	F	Insertion, SV	Hemiparesis
Black et al., 1991 (15)	58	M	Removal, IJV	Hemiparesis
Moorthy et al., 1991 (16)	66	M	Removal, IJV	Hemiparesis, coma
Halliday et al., 1994 (35)	26	F	Disconnection, CVL	Hemiparesis, visual loss
Hartung et al., 1994, c. 2 (36)	59	M	Disconnection, IJV	Hemiparesis, aphasia
Yu and Levy, 1997 (37)	45	F	Hemodialysis, SV	Hemiparesis

Table 1. Continues.

CT Result	Treatment	Outcome	Cardiac Defect
No CT	ICU	Lethal	PFO
No CT	ST	Recovery with deficit	No information
No CT	ST	Complete or good recovery	No information
Air bubbles	CPR	Lethal	PFO
Air bubbles	HBO	Recovery with deficit	PFO
CT unremarkable	ST	Complete or good recovery	No information
Air bubbles	ICU	Recovery with deficit	No cardiac defect
No CT	ST	Complete or good recovery	No information
No CT	CPR	Lethal	No information
Air bubbles	ICU	Lethal	No cardiac defect
No CT	CPR	Complete or good recovery	No information
Air bubbles	No information	Recovery with deficit	No information
Air bubbles	ICU	Lethal	No cardiac defect
Air bubbles	ST	Recovery with deficit	No cardiac defect
No CT	No information	Complete or good recovery	No information
No CT	HBO	Complete or good recovery	Cardiac defect
No CT	ST	Complete or good recovery	PFO
Air bubbles	ST	Recovery with deficit	No cardiac defect
Infarction	No information	Recovery with deficit	No cardiac defect
Infarction	ST	Complete or good recovery	No information
Air bubbles	ST	Recovery with deficit	No information
No information	ICU	Lethal	No cardiac defect
Air bubbles	ST	Recovery with deficit	No cardiac defect
CT unremarkable	HBO	Complete or good recovery	No cardiac defect
Air bubbles	ST	Complete or good recovery	No information
Air bubbles	No information	No information	Cardiac defect, PFO

CV, central venous; CT, computed tomography; CVL, central venous catheter; c., case; ICU, intensive care unit; PFO, patent foramen ovale; SV, subclavian vein; ST, symptomatic treatment; IJV, internal jugular vein; CPR, cardiopulmonary resuscitation; HBO, hyperbaric oxygenation; AV, atrio-venous.

RESULTS

We strongly believe that cerebral air embolism in our patient occurred during the unintentional central venous catheter disconnection and that the air bubbles probably traversed from the veins to the arteries via pulmonary right-to-left shunts. A cardiac defect was not probable because ventriculography showed neither a patent

foramen ovale nor an atrial septum defect. In addition, any relationship to the previous coronary bypass surgery and the postoperative minor thoracotomy after pneumothorax was considered unlikely because the cerebral accident occurred ≤ 14 days after thoracic drain removal and 17 days after coronary artery surgery.

The results of the literature search are reported in Table 1. Including our patient, the search encompassed 17 men and nine women ranging in age from 19 to 79 yrs (average, 54.7 yrs). In 12 patients (38%) the unintended injury occurred during a subclavian vein catheterization procedure, in eight patients during jugular vein catheterization (31%), in one patient (4%) resulting from an inadvertent air injection into an antecubital vein, and in five patients (19%) no detailed information was provided. Most events happened during disconnection (14 patients; 54%), less frequently after removal and other procedures (eight patients; 31%), or insertion (four patients; 15%). The neurologic manifestations can be divided into two groups. Group A (n = 14) had predominantly encephalopathic features, typically with an acute confusional state, akinetic mutism (as with our patient), various stages of coma, or generalized seizures. Group B (n = 12) demonstrated focal neurologic signs, of which hemiparesis (9 of 12, mostly left-sided) was most frequent, followed by homonymous hemianopia (5 of 12), hemihyesthesia (1 of 12), aphasia (1 of 12), and stupor (1 of 12). A CT scan available in 16 patients demonstrated air bubbles in 12 patients (75%) and signs of infarction in two patients (13%); CT was unremarkable in two patients (13%).

Data on cardiac defects were available in 15 patients. Cardiac defects occurred in six patients (40%). In nine patients, including our patient, a physiologic arteriovenous pulmonary shunt was

considered the reason for right-left shunting (60%).

Detailed information about the treatment of cerebral air embolism was available for 22 patients. Specific hyperbaric oxygen therapy, which is recommended by some authors (1-4), was performed in only three patients (12%). The other patients received symptomatic treatment, including cardiopulmonary resuscitation and intensive care unit therapy.

Cerebral air embolism was lethal in six patients (23%); however, nine patients (35%) survived with severe residual neurologic deficits and ten patients (38%) survived with good or complete recovery. In one patient (4%), no information on the course of the disease was given. With regard to the two types of neurologic manifestations, group A with an encephalopathic pattern had a higher mortality rate (36%) and a lower rate of good or complete recovery (29%) than group B, in which the mortality rate was 8% and the rate of good or complete recovery was 50%. Group A patients had a higher age (mean, 63.9 yrs) than group B patients (mean, 44 yrs).

DISCUSSION

The initial approach to our anticoagulated patient with acute neurologic dysfunction was to look for intracerebral hemorrhage and to exclude toxic, metabolic, or infectious disorders. Cerebral air embolism was not suspected initially and, therefore, diagnosed late. Approximately 72 hrs after the onset of signs and symptoms, the correct diagnosis was made and the mechanism of stroke was reconstructed.

Ideally, in patients with central venous catheter, cerebral air embolism should be suspected early during the course of neurologic dysfunction. Appropriate diagnostic measures useful to identify this entity include arterial blood gas analysis,

chest radiography, echocardiography, and CT (11-13). In addition, if air embolism during monitoring procedures occurs, a decrease of end-tidal PCO₂ is one of the earliest signs, reflecting the disordered ventilation-perfusion matching and increased physiologic deadspace breathing (12).

Venous air embolism may occur during insertion, use, or maintenance of the catheter and after catheter disconnection and removal (14-17). In the patients reviewed, the most hazardous situation was unintentional disconnection.

After venous air embolism, severe cardiovascular and pulmonary changes typically occur. The sequelae depend on the amount of air, the speed of entry, and the location within the body (12). An "air lock" in the right heart obstructs the outflow, resulting in right heart failure with consequent hypo-oxygenation and cardiovascular depression (12). It is worth mentioning that through a 14-gauge needle, if the pressure gradient is 5 cm H₂O, it is possible that 100 mL of air per second will enter the vascular system (18). Paradoxical air embolism occurs under cardiac defect conditions and via physiologic pulmonary arteriovenous shunts (19-21).

Two types of neurologic manifestations can be observed. In group A, patients presented with clinical signs and symptoms of encephalopathy, including decreased consciousness, deep coma, seizures, and sometimes overlapping focal signs. These patients have a poor outcome and a high mortality rate. In addition, the mean age of this subgroup is high. Whether in these patients a depression of the cardiocirculatory system is leading to a general cerebral hypoxia and ischemia cannot be determined based on this review. It may be speculated that the higher age may be a risk factor because in elderly individuals, the reserve capacity of oxygen

and energy substrates is diminished when compared with those values in younger individuals. Group B presents mostly predominant focal signs pointing to the right hemisphere and the right posterior circulation, probably because air bubbles follow the bloodstream directly from the aorta to the right innominate artery or the right vertebral artery (22).

Computed tomography is a valuable tool in detecting cerebral air bubbles, especially when performed soon after the incident (13). However, it is essential that the examiner be familiar with bubble appearance. Late CT changes are not specific and are difficult to distinguish from ischemic infarction or diffuse leukoencephalopathy, as our CT follow-up demonstrated.

Successful treatment of air embolism consists of the following: a) stopping the air entry; b) aspiration of the air from the right ventricle if a central catheter is being used; c) placing the patient in a head-down left lateral position (Durant's maneuver); and d) initiating general intensive care unit measures as soon as possible, including oxygen supply and cardiopulmonary resuscitation. Hyperbaric oxygen treatment in special centers is recommended (1-4); however, its real efficacy has recently been questioned (23). In the literature we reviewed, hyperbaric oxygenation could only be performed in a minority of patients, probably because of logistic problems involved in the long distance transport of a critically ill patient to a specialized treatment center. However, these three patients all survived, two of them recovering completely and one of them recovering well. Despite this, the data reviewed do not warrant the assumption that hyperbaric oxygenation is superior to general symptomatic treatment. In our patient, the diagnosis of cerebral air embolism was unfortunately delayed. At the time of correct

diagnosis, the CT scan no longer indicated air bubbles and hyperbaric oxygenation was, therefore, not initiated.

Paradoxical embolism is typically considered to be related to cardiac defects, such as a patent foramen ovale or atrial septal defect. The results of this review, however, show that this condition is less frequent than hemodynamically relevant pulmonary shunts. This is important, for example, in neurosurgical procedures in which cerebral air embolism cannot only occur via cardiac defects, but also via transpulmonary passage (24). The new method of contrast-enhanced transcranial Doppler during Valsalva maneuvering will be able to detect these pulmonary shunts (25).

In conclusion, when caring for patients with central venous catheters, strong emphasis has to be placed on preventing air embolism. General guidelines (Trendelenburg position, occlusion of the needle, adequate central venous catheter care, and occlusive dressing after removal) should be strictly observed (11, 12). Neurologic deterioration during central venous catheterization procedures should always be taken as a potential sign of cerebral air embolism and lead to prompt diagnosis, thus limiting cerebral damage.

REFERENCES

1. Hwang TL, Fremaux R, Sears ES, et al: Confirmation of cerebral air embolism with computerized tomography. *Ann Neurol* 1983; 13:214-215
2. Mader JT, Hulet WH: Delayed hyperbaric treatment of cerebral air embolism: Report of a case. *Arch Neurol* 1979; 36:504-505
3. Menkin M, Schwartzman RJ: Cerebral air embolism: Report of five cases and review of the literature. *Arch Neurol* 1977; 34:168-170
4. Voorhies RM, Fraser RAR: Cerebral air embolism occurring at angiography and diagnosed by computerized tomography. *J Neurosurg* 1984; 60:177-178
5. Vourc'h G: Paradoxical air embolism. *N Engl J Med* 1971; 285:56
6. Wijman CAC, Kase CS, Jacobs AK, et al: Cerebral air embolism as a cause of stroke during cardiac catheterization. *Neurology* 1998; 51:318-319
7. Ponsky JL, Pories WJ: Paradoxical cerebral air embolism. *N Engl J Med* 1971; 284:985
8. Kashuk JL, Penn I: Air embolism after central venous catheterization. *Surg Gynecol Obstet* 1984; 159:249-252
9. Seidelin PH, Stolarek H, Thompson AM: Central venous catheterization and fatal air embolism. *Br J Hosp Med* 1987; 38:438-439
10. Defalque RJ, Fletcher MV: Neurological complications of central venous cannulation. *JPEN J Parenter Enteral Nutr* 1988; 12:406-409
11. Feliciano DV, Mattox KL, Graham JM, et al: Major complications of percutaneous subclavian venous catheters. *Am J Surg* 1979; 138:869-873
12. Orebaugh SL: Venous air embolism: Clinical and experimental considerations. *Crit Care Med* 1992; 20:1169-1177
13. Jensen ME, Lipper MH: CT in iatrogenic cerebral air embolism. *AJNR Am J Neuroradiol* 1986; 7:823-827
14. Dilkes MG, Dunwoody G, Bull TM, et al: A case of intracerebral air embolism secondary to the insertion of a Hickman line. *JPEN J Parenter Enteral Nutr* 1991; 15:488-490

15. Jacobsen WK, Briggs BA, Mason LJ: Paradoxical air embolism associated with a central total parenteral nutrition catheter. *Crit Care Med* 1983; 11:388-389
16. Moorthy SS, Tisinai KA, Speiser BS, et al: Cerebral air embolism during removal of a pulmonary artery catheter. *Crit Care Med* 1991; 19:981-983
17. Schlotterbeck K, Tanzer H, Alber G, et al: Zerebrale luftembolie nach zentralem venenkatheter. *Anesthesiol Intensivmed Notfallmed Schmerzther* 1997; 32:458-462
18. Ordway CB: Air embolus via CVP catheter without positive pressure. *Ann Surg* 1974; 179:479-481
19. Black M, Calvin J, Chan KL, et al: Paradoxical air embolism in the absence of an intracardiac defect. *Chest* 1991; 99:754-755
20. Butler BD, Hills BA: Transpulmonary passage of venous air emboli. *J Appl Physiol* 1985; 59:543-547
21. Tommasino C, Rizzardi R, Beretta L, et al: Cerebral ischemia after venous air embolism in the absence of intracardiac defects. *J Neurosurg Anesthesiol* 1998; 8:30-34
22. Caplan LR: Posterior circulation disease: Clinical findings, diagnosis, and treatment. Cambridge, MA, Blackwell Scientific Publications, 1996
23. Layon AJ: Hyperbaric oxygen treatment for cerebral air embolism: Where are the data? *Mayo Clin Proc* 1991; 66:641-646
24. Marquez J, Sladen A, Gendell H, et al: Paradoxical cerebral air embolism without an intracardiac septal defect. *J Neurosurg* 1981; 55:997-1000
25. Heckmann JG, Hilz MJ, Hecht M, et al: Transesophageal echocardiography and contrast-transcranial Doppler sonography yield a higher rate for the detection of patent foramen ovale than one method alone. *Eur J Neurol* 1998; 5:S78
26. Grace DM: Air embolism with neurologic complication: A potential hazard of central venous catheter. *Can J Surg* 1977; 20:51-53
27. Michel L, Poskanzer DC, McKusick KA, et al: Fatal paradoxical air embolism to the brain: Complication of central venous catheterization. *JPEN J Parenter Enteral Nutr* 1982; 6:68-70
28. Neubauer N, Umek H, Kristoferitsch: A cerebral air embolism due to a central venous catheter in the computed tomogram. *Rontgenblatter* 1988; 41:462-464
29. Phifer TJ, Bridges M, Conrad SA: The residual central venous catheter track: An occult source of lethal air embolism-Case report. *J Trauma* 1991; 31:1558-1560
30. Turnage S, Harper JV: Venous air embolism occurring after removal of a central venous catheter. *Anesth Analg* 1991; 72:559-560
31. Ploner F, Saltuari L, Marosi MJ, et al: Cerebral air emboli with use of central venous catheter in mobile patient. *Lancet* 1991; 338:1331
32. Mennim P, Coyle CF, Taylor JD: Venous air embolism associated with removal of central venous catheter. *BMJ* 1992; 305:171-172
33. Aikawa H, Mori H, Miyake H, et al: A case of cerebral air embolism predominant in the left hemisphere following subclavian catheterization. *Radiat Med* 1995; 13:73-76
34. Kearns PJ, Haulk AA, McDonald TW: Homonymous hemianopia due to cerebral air embolism from central

venous catheters. *West J Med* 1984; 140:615-617

35. Halliday P, Anderson DN, Davidson AI, et al: Management of cerebral air embolism secondary to a disconnected central venous catheter. *Br J Surg* 1994; 81:71
36. Hartung EJ, Sgouropoulou S, Bierl R, et al: Severe air embolism caused by a pulmonary artery introducer sheath. *Anesthesiology* 1994; 80:1402
37. Yu ASL, Levy E: Paradoxical cerebral air embolism from a hemodialysis catheter. *Am J Kidney Dis* 1997; 29:453-455