

Case Reports

Amnesia due to Fornix Infarction

Shyam S. Moudgil, MD; Mouhannad Azzouz, MD; Abdulkader Al-Azzaz, MD;
Marc Haut, PhD; Ludwig Gutmann, MD

Background and Purpose—The fornix connects various structures involved in memory. We report a patient with anterograde amnesia after an acute ischemic infarct in the anterior fornix.

Case Description—A 71-year-old female with acute-onset amnesia had neuroimaging studies showing ischemic infarction of both columns and the body of the fornix and the genu of the corpus callosum. Neuropsychological evaluation revealed anterograde amnesia without evidence of callosal disconnection. The patient showed marked improvement in her memory function on the follow-up visit.

Conclusions—Amnesia in this case is likely due to infarction of the anterior fornix structures. (*Stroke*. 2000;31:1418-1419.)

Key Words: amnesia ■ fornix (brain) ■ stroke, ischemic

The fornix plays an important role in the human memory by connecting the hippocampus with other structures involved with memory, including the anterior thalami, septal nuclei, and mammillary bodies. Amnesia, resulting from lesions involving the fornix, has been attributed to the damage of this vital link. In several reports,¹⁻⁵ a variety of lesions has damaged the fornix, causing a spectrum of memory deficits. Amnesia, after ischemic infarction of the fornix, has not been previously reported in the available English literature. We report a case of anterograde amnesia after acute infarction of the anterior portion of the fornix.

Case Report

A 71-year-old female with a history of well-controlled hypertension developed sudden memory impairment. While in a restaurant 1 day before admission to the hospital, she could not remember what she had ordered for dinner. She also could not recall incidents of the immediate past. On arrival at the hospital, her blood pressure was 110/70 mm Hg, and her heart rate was 60 bpm and regular. She was alert and oriented to time, person, and place. Neurological examination was normal except for tests of memory function.

Hemoglobin, carboxyhemoglobin, total leukocyte count, sedimentation rate, electrolytes, liver enzymes, thyroid-stimulating hormone, cerebrospinal fluid examination, and EEG were normal. Carotid Doppler showed mild atherosclerosis without significant stenosis. Echocardiogram showed mild aortic stenosis with normal left ventricular function.

MRI of the brain 24 hours after the onset of the symptoms revealed lesions involving both columns and the body of the fornix and the genu of the corpus callosum and extending

slightly into the medial frontal lobe. These lesions were of low signal intensity on T1-weighted images and high signal intensity on T2-weighted images, fluid-attenuated inversion recovery, and diffusion-weighted images (Figure) and were consistent with acute ischemia.

Bedside neuropsychological evaluation performed acutely revealed anterograde amnesia for verbal and visual information but intact confrontation-naming and low average-problem-solving skills. She recalled, at most, 4 of 10 words over 3 trials, with a total of 4 intrusions.⁶ She could initially recognize the words, but over time, she could not. Her immediate memory for the Rey-Osterreith Complex Figure (Lezak⁷) was at the first percentile, and after a delay, it was nonexistent. Her performance was average on the Boston Naming Test^{8,9} and Wisconsin Card Sorting Test.^{10,11} There was no evidence of callosal disconnection on motor and sensory examination.

On the follow-up visit 1 month later, she showed significant improvement in her short-term memory. She was able to recall 3 objects after 5 minutes and displayed marked progress in her ability to register verbal and visual information. However, she had no recall of the events of her hospitalization.

Discussion

The fornix serves as the major efferent pathway connecting the hippocampus with other limbic and diencephalic structures. Lesions in the fornix disconnect the hippocampus and thus lead to memory deficits very similar to those observed with hippocampal lesions.¹² Amnesia due to the damage of the fornix has been seen in patients with a variety of lesions.

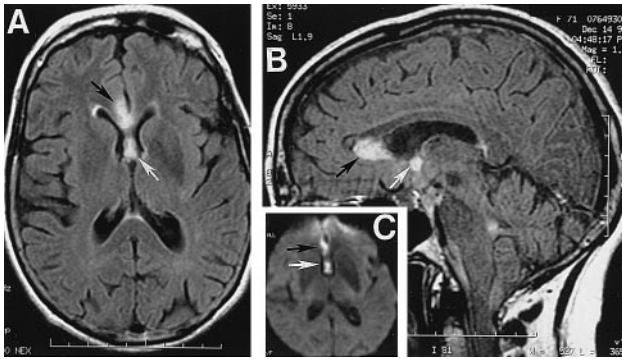
Received February 1, 2000; final revision received March 20, 2000; accepted March 20, 2000.

From the Departments of Neurology (S.S.M., M.A., A.A.-A., M.H.), Radiology (A.A.-A., M.H.), and Behavioral Medicine and Psychiatry (M.H.), West Virginia University School of Medicine, Morgantown, WV.

Correspondence to Ludwig Gutmann, MD, Department of Neurology, PO Box 9180, West Virginia University Health Sciences Center, Morgantown, WV 26505-9180. E-mail lgutmann@wvu.edu

© 2000 American Heart Association, Inc.

Stroke is available at <http://www.strokeaha.org>



MRI in fluid-attenuated inversion recovery sequence in axial (A) and sagittal (B) planes and diffusion-weighted image (C) showing acute ischemic lesions in anterior fornix (white arrows) and genu of corpus callosum (black arrows).

Fornix lesions causing amnesia have been located anteriorly with hemangioma¹ and after colloid cyst removal² and posteriorly with spongioblastoma³ and gunshot injury.⁴ The fornix has been shown to be diffusely involved in focal encephalitis.⁵ Removal of a colloid cyst via an anterior transcallosal approach carries greater risk of damage to the fornix.

There are reports of surgical sectioning of both fornices without clinically evident memory deficits in the management of temporal lobe epilepsy. In an analysis of 142 cases of bilateral anterior fornix transection in epileptic patients, Garcia-Bengochea and Friedman¹³ found no patient with persistent memory loss. However, the authors noted the possibility of missed memory deficits because a significant number of such patients had various degrees of psychotic symptoms, and no formal neuropsychological testing was performed.

Amnesia as a result of infarction of the fornix has been reported once previously.¹⁴ An autopsy study of a patient with Korsakoff's syndrome showed old infarcts of the columns of both fornices. The case was complicated by additional infarction of other structures, including anterior thalamus, mammillary body, basal ganglia, and cingulate gyrus.

The fornix derives its blood supply mainly from the short medial central arteries, which are branches of the proximal anterior cerebral artery. These are 4 to 10 in number and enter the brain through the anterior perforated substance. Structures supplied by these perforating branches include olfactory trigone, olfactory striae, preoptic region, anterior hypothalamus, genu of the corpus callosum, septum, anterior commissure, fornix, and the anteroinferior aspect of the striatum. Alternatively, these branches may arise from the anterior communicating artery.¹⁵

Anterior cerebral artery infarcts are rare and represent $\approx 3\%$ of all acute ischemic infarcts.¹⁶ Infarcts of the anterior cerebral artery territory due to occlusion of perforating branches are extremely rare. Our patient had infarction of the fornix and genu of the corpus callosum, which most likely represents occlusion of ≥ 1 of the perforating branches. In view of the absence of a thromboembolic source, the mechanism of occlusion was, most likely, small-vessel disease, as seen in chronic hypertension.

The location of the fornix lesion causing amnesia has received discussion in the literature. Amnesia has been reported in both anterior and posterior lesions. In the posterior lesions, damage to the dorsal hippocampal commissure has been suggested as the cause for amnesia.⁴ Our case, with its discrete focal involvement of anterior columns and the body of the fornix, indicates that amnesia may result from lesions of the anterior fornix. However, we could not exclude minor involvement of the septohippocampal fibers and medial forebrain bundle.

Our patient also had infarction of the genu of the corpus callosum. Lesions of the anterior corpus callosum may lead to callosal disconnection syndrome, which is characterized by left-hand ideomotor apraxia, left-hand agraphia, left-hand tactile anomia, and left alien hand. Extracallosal damage to the nearby frontal lobe plays a crucial role in the causation of this syndrome.¹⁷ Our patient did not manifest any of the signs of callosal disconnection, which was likely because of the absence of significant extracallosal involvement.

References

1. Yasuno F, Hirata M, Takimoto H, Taniguchi M, Nakagawa Y, Ikejiri Y, Nishikawa T, Shinozaki K, Tanabe H, Sugita Y, et al. Retrograde temporal order amnesia resulting from damage to the fornix. *J Neurol Neurosurg Psychiatry*. 1999;67:102–105.
2. Hodges JR, Carpenter K. Anterograde amnesia with fornix damage following removal of IIIrd ventricle colloid cyst. *J Neurol Neurosurg Psychiatry*. 1991;54:633–638.
3. Heilman KM, Sybert GW. Korsakoff's syndrome resulting from bilateral fornix lesions. *Neurology*. 1977;27:490–493.
4. D'Esposito M, Verfaellie M, Alexander MP, Katz DI. Amnesia following traumatic bilateral fornix transection. *Neurology*. 1995;45:1546–1550.
5. Yamamoto T, Kurobe H, Kawamura J, Hashimoto S, Nakamura M. Subacute dementia with necrotizing encephalitis selectively involving the fornix and splenium: retrograde development of Alzheimer's neurofibrillar tangles in the subiculum. *J Neurol Sci*. 1990;96:159–172.
6. Welsh KA, Butters N, Mohs RC, Beekly D, Edland S, Fillenbaum G, Heyman A. The consortium to establish a registry for Alzheimer's disease (CERAD). V: a normative study of the neuropsychological test battery. *Neurology*. 1994;44:609–614.
7. Lezak MD. *Neuropsychological Assessment*. 3rd ed. New York, NY: Oxford University Press; 1995.
8. Kaplan E, Goodglass H, Weintraub S. *The Boston Naming Test*. Philadelphia, Pa: Lea & Febiger; 1983.
9. Ivnik RJ, Malec JF, Smith GE, Tangalos EG, Petersen RC. Neuropsychological tests' norms above age 55: COWAT, BNT, MAE Token, WRAT-R Reading, AMNART, STROOP, TMT, and JLO. *Clin Neuropsychol*. 1996;10:262–278.
10. Berg E. A simple objective technique for measuring flexibility in thinking. *J Gen Psychol*. 1948;39:15–22.
11. Bondi M, Monsch A, Butters N, Salmon D, Paulson J. Utility of a modified version of the Wisconsin card sorting test in the detection of dementia of the Alzheimer's type. *Clin Neuropsychol*. 1993;7:161–170.
12. Tucker DM, Roeltgen DP, Tully R, Hartmann J, Boxell C. Memory dysfunction following unilateral transection of the fornix: a hippocampal disconnection syndrome. *Cortex*. 1988;24:465–472.
13. Garcia-Bengochea F, Friedman WA. Persistent memory loss following section of the anterior fornix in humans: a historical review. *Surg Neurol*. 1987;27:361–364.
14. Brion S, Pragier G, Guerin R, Teitgen M. Syndrome de Korsakoff par ramollissement bilatéral du fornix: le problème des syndromes amnésiques par lésion vasculaire unilatérale. *Rev Neurol*. 1969;120:255–262.
15. Gade A. Amnesia after operations on aneurysms of the anterior communicating artery. *Surg Neurol*. 1982;18:46–49.
16. Gacs G, Fox AJ, Barnett HJM, Vinuela F. Occurrence and mechanisms of occlusion of the anterior cerebral artery. *Stroke*. 1983;14:952–959.
17. Gazzaniga MS, Bogen JE, Sperry RW. Dyspraxia following division of the cerebral commissures. *Arch Neurol*. 1967;16:606–612.