

Endovascular Treatment of Dural Sinus Thrombosis With Rheolytic Thrombectomy and Intra-Arterial Thrombolysis

Kira Chow, MD; Y. Pierre Gobin, MD; Jeffrey Saver, MD; Chelsea Kidwell, MD;
Paul Dong, MD; Fernando Viñuela, MD

Background and Purpose—Cerebral venous thrombosis is a rare entity that can be difficult to manage. Intrasinus thrombolysis is an increasingly applied intervention, but this modality carries an increased risk of hemorrhage. We describe for the first time an option with a potentially lower incidence of intracranial bleeding, the combination of the AngioJet rheolytic thrombectomy catheter with intra-arterial thrombolysis, in 2 patients with extensive dural sinus thromboses, preexisting intracranial hemorrhage, and severe progressive neurological deficits despite heparin therapy.

Methods—Four procedures were performed in 2 patients with thromboses in the superior sagittal and transverse sinuses (right in 1 patient and bilateral in 1 patient) and cortical veins. Rheolytic thrombectomy was performed in the sigmoid, transverse, straight, and superior sagittal sinuses; this technique involves the use of the Bernoulli effect to create a vacuum that fragments and aspirates thrombus. For associated persistent cortical vein thromboses, low-dose intra-arterial thrombolysis was used.

Results—Both patients had excellent angiographic results with sinus reopening after rheolytic thrombectomy and cortical vein reopening after intra-arterial thrombolysis. Follow-up CT showed no change in 1 patient and increased preexisting intracranial hemorrhage in the other. One patient had a negative hypercoagulable workup, and the other patient had probable anti-phospholipid antibody syndrome. At 6 months, both patients had excellent clinical outcome with no neurological deficits except mild short-term memory loss in 1 patient.

Conclusions—The combination of rheolytic thrombectomy with intra-arterial thrombolysis is a treatment modality that allows accelerated recanalization of occluded dural sinuses and cerebral veins with lower doses of thrombolytic agents. (*Stroke*. 2000;31:1420-1425.)

Key Words: sinus thrombosis ■ thrombectomy ■ thrombolysis

Dural sinus thrombosis remains poorly understood. The natural course is unpredictable, and the true incidence is unknown because cases have often gone unrecognized. Sixteen cases of superior sagittal sinus (SSS) thrombosis were discovered during 12 500 autopsies.¹ Cerebral venous thrombosis was reported to be the cause of death in 21.7 persons per year in England and Wales between 1952 and 1961,² and depending on the series, mortality rates range from 5% to 30%.³ Conditions that are known predisposing factors for dural sinus thrombosis include, but are not limited to, puerperium, trauma, malignancy, disseminated intravascular coagulation, hypercoagulable states, infections, medications (eg, synthetic steroids and contraceptive hormones), connective tissue disorders, and dehydration.³⁻⁵

Clinical symptoms and severity vary depending on the extent and location of thrombus, venous collateral vessels, and rate of thrombus progression.⁶ Occlusions in the superficial venous system are better tolerated than are those in the deep venous system, due to a plentiful collateral supply in the superficial system. Involvement of the deep venous system

has often been associated with a grave prognosis.^{5,7-9} In acute occlusions, collateral flow cannot be established, and significant edema with mass effect may result. Other poor prognostic indicators include extension into cerebral veins,^{1,2} coma,^{3,10} rate of evolution of deficits,^{3,10} and presence of focal findings,³ but these factors have not been proved in larger series.¹¹

Optimal treatment is still controversial, in part because of the variable nature of disease progression. Cerebral dehydrating agents, steroids, acetazolamide, cerebrospinal fluid drainage, barbiturates,¹² and decompressive craniectomy have been used to lower intracranial pressure but are of unproved benefit. Anticoagulation is a common first-line treatment. One randomized controlled study¹³ showed improved outcome in patients treated with heparin compared with patients who received no treatment. The goal of the use of anticoagulation is to prevent thrombus propagation, which has been implicated as the cause of the progressively worsening clinical status in some patients. However, anticoagulation does not lyse the thrombus that occludes the sinus.^{11,14} When

Received December 3, 1999; final revision received March 15, 2000; accepted March 15, 2000.

From the University of California Los Angeles Medical Center and School of Medicine.

Correspondence to Y. Pierre Gobin, MD, UCLA Medical Center, Radiology 172115, B7-146A, 10833 Le Conte Avenue, Los Angeles, CA 90095-1721.

E-mail pgobin@mednet.ucla.edu

© 2000 American Heart Association, Inc.

Stroke is available at <http://www.strokeaha.org>

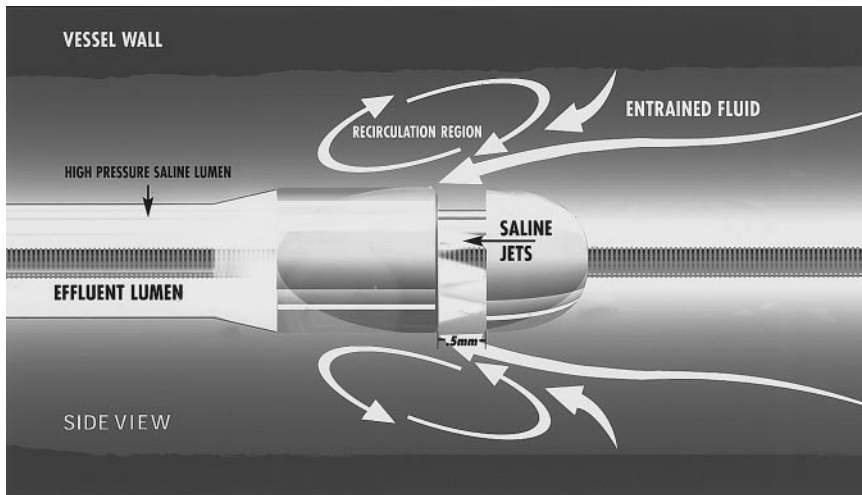


Figure 1. Schematic of the 5F LF140 AngioJet catheter. Six high-pressure saline jets create a low-pressure zone and vortices around the catheter tip. Thrombus surrounding the catheter is macerated and aspirated into the effluent lumen of the catheter.

sinus occlusion is poorly tolerated due to insufficient collateral blood flow, active reestablishment of venous drainage through thrombolysis to prevent cerebral edema and mass effect may be a more plausible alternative. The successful use of peripherally infused urokinase and heparin has been occasionally reported.^{14–16} When heparin therapy fails, the patient's prognosis is poor, and more invasive therapies for direct revascularization of the sinus may be indicated. To this end only, intravenous and intrasinus thrombolysis and surgical revascularization procedures such as sinus thrombectomy and bypass have been reported.¹⁷

Intravenous thrombolysis has resulted in variable outcomes.¹⁶ High-dose peripheral infusion of streptokinase and urokinase can take days to recanalize vessels¹⁸ because the concentration of thrombolytic agent that actually arrives at the site of occlusion is low. Thrombolysis is accelerated through direct intrasinus infusion of the thrombolytic agent, and recent series with this method have reported promising results.^{10,19–21} There also is a lower incidence of hemorrhage associated with locally catheter-administered thrombolytic agents¹⁰ because of the lower doses needed and because its direct delivery into the occluded sinus bypasses the infarcted brain tissue.¹⁹ Reports of positive outcomes after local thrombolysis in patients who deteriorate despite heparin therapy are abundant, and this modality is quickly becoming a routine intervention at tertiary centers.^{5,6,10,14,18,19,22–30} This technique has been used even in patients for whom cerebral edema or hemorrhage is seen on CT or MRI.^{19,24,25}

Even when delivered directly into the sinus, thrombolytic agents are associated with an increased risk of hemorrhage and delayed recanalization. The AngioJet is a mechanical thrombectomy catheter that works by creating a vacuum to fragment and aspirate the thrombus through the catheter (Figure 1).³¹ This device has been used for many indications in peripheral interventional radiology, and its use in dural sinus thrombosis has been described in 2 patients^{32,33} with associated intrasinus thrombolysis in 1 patient.³³ In the 2 cases of dural sinus thrombosis that we describe here, both patients had severe neurological symptoms despite heparin therapy and had evidence of intracranial hemorrhage on brain imaging. Therefore, the AngioJet was used to lyse the large

thrombi present in the venous sinuses, and low-dose intra-arterial thrombolysis was used for the remaining occlusions in the cortical veins.

Case Reports

Case 1

A 36-year-old woman with a prior history of left transverse sinus thrombosis 4 years earlier was transferred to our institution with a 2-week history of severe headache, nausea, vomiting, and photophobia followed by focal motor seizures. Despite adequate anticoagulation with heparin, progressive somnolence, bilateral facial weakness, and left hemiparesis occurred. aPTT on presentation to our institution was 81.5 seconds.

CT and MRI revealed thrombosis of the SSS and right transverse sinus, right posterior temporal venous infarction with hemorrhagic transformation, and edema of the right centrum semiovale. Due to the severity of the patient's symptoms and the presence of intracranial hemorrhage, the option to recanalize the sinuses with rheolytic thrombectomy was offered to the patient, who gave informed consent for the off-label use of the AngioJet.

The patient received intravenous heparin during the procedure and her entire hospital stay. The initial angiogram confirmed occlusion of the superior sagittal, right transverse, and sigmoid sinuses and right frontal and parietal cortical veins (Figure 2A). With a 140-cm AngioJet catheter, rheolytic thrombectomy was first performed in the right sigmoid and transverse sinuses. Subsequently, the AngioJet catheter could not be passed beyond the midportion of the transverse sinus. Angioplasty was performed. Then, the AngioJet catheter was advanced into the SSS (Figure 2B), where rheolytic thrombectomy achieved complete recanalization (Figure 2C). Thrombi remained within the right parietal cortical veins (Figure 2D).

The patient was more alert but had persistent left hemiplegia in the morning, and CT scans showed increased right hemispheric edema. Follow-up right carotid angiography showed persistent thrombi within the right parietal cortical veins (Figure 2E). We decided to dissolve the remaining thrombi in the right cortical veins with intra-arterial

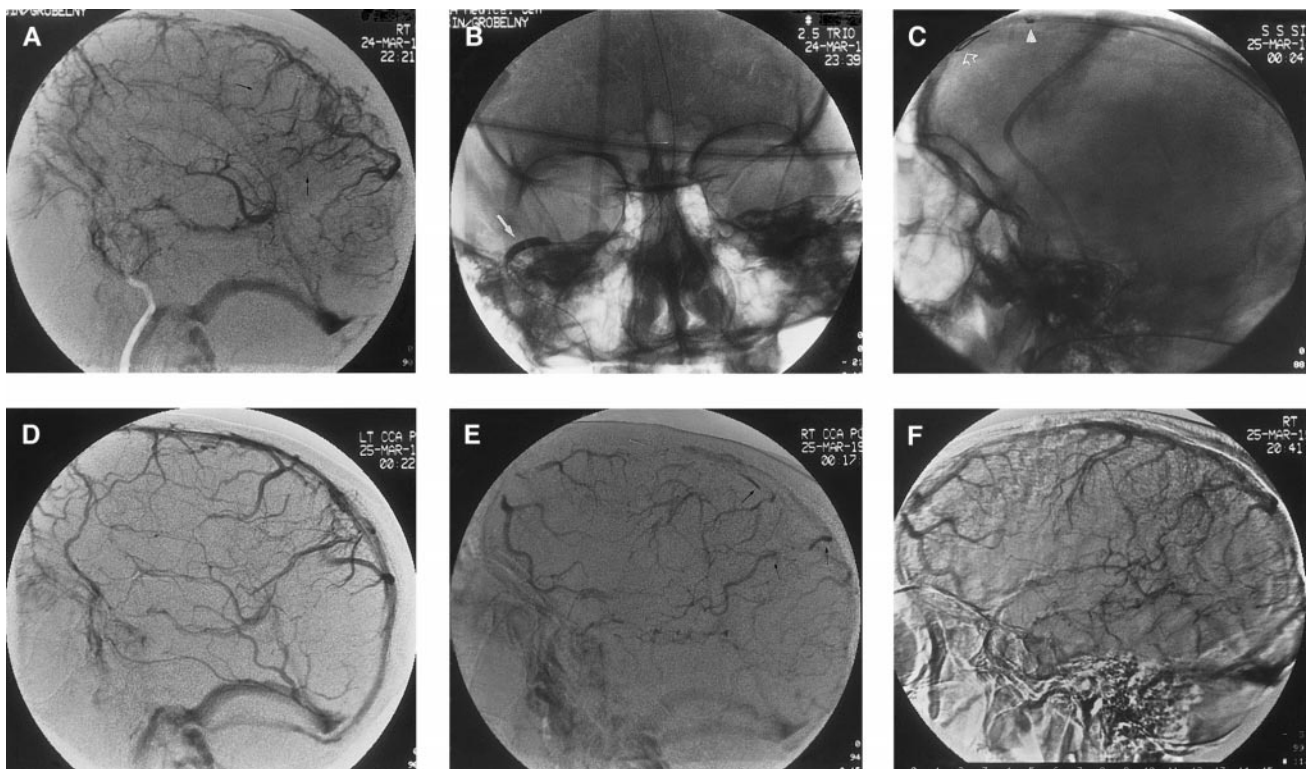


Figure 2. A, Right internal carotid angiogram (lateral view, venous phase) showing a lack of opacification of the SSS and the right transverse and sigmoid sinuses. Note the stagnation in the right parietal cortical veins (arrows). B, Unsubtracted anteroposterior view during balloon angioplasty (arrow) of the right transverse sinus. C, Unsubtracted lateral view. The AngioJet catheter (arrowhead indicates tip, arrow indicates body of catheter) has been advanced into the anterior third of the SSS over a 14I exchange guidewire (open arrow). D, Left internal carotid angiogram (lateral view, venous phase) after rheolytic thrombectomy of the SSS and right transverse/sigmoid sinus. The sinuses are reopened. E, Right internal carotid angiogram (lateral view, venous phase) after rheolytic thrombectomy. There is persistent contrast stagnation in the right parietal veins (arrows). F, Right internal carotid angiogram (lateral view, venous phase) after intra-arterial thrombolysis with 400 000 IU urokinase injected during 4 hours. There is improved filling of the right parietal cortical veins. The patient made a full recovery.

thrombolysis. Because of the risk of increasing the preexisting intracranial hemorrhage, a rather low dose of 400 000 IU at a rate of 100 000 IU/h over 4 hours was injected into the right internal carotid artery (ICA). Serial angiograms demonstrated gradual improvement of the capillary drainage rate and successive reopening of the parietal cortical veins (Figure 2F). Postthrombolysis CT revealed no new infarctions and no hemorrhagic complications.

During the next few days, the patient continued to improve neurologically and went home after 1 week with a normal neurological examination. Hypercoagulable panels, including activated protein C resistance and prothrombin gene mutation, were negative. Discharge medications included warfarin and phenytoin. She returned to work 2 weeks later. At 6 months, the patient had resumed her previous activities and lifestyle without complaints.

Case 2

A 21-year-old woman with an 8-week pregnancy had a 2-week history of severe headaches and nausea. She developed generalized weakness and presented to an outside emergency department, where she experienced 2 generalized tonic-clonic seizures. Her CT scan was normal, but a cerebral angiogram showed extensive sinus thrombosis. A ventriculostomy was placed, and the patient received mannitol,

steroids, anticonvulsant medications, and heparin. During the next day, she became obtunded and quadriparetic and was transferred to our institution for further care. At that time, aPTT was 79.1 seconds. Repeat CT scan showed a mild bleed surrounding the ventriculostomy drain and in the lateral ventricle but no infarction. Because of the intracranial hemorrhage, the patient's family gave informed consent for rheolytic thrombectomy with off-label use of the AngioJet.

The patient received intravenous heparin during the procedure and her entire hospital stay. The initial angiogram showed thrombosis of the SSS and left transverse/sigmoid sinuses, poor visualization of the right transverse sinus, multiple thromboses in the cortical veins, and poor visualization of the deep venous system (Figure 3A). With a 140-cm AngioJet catheter, rheolytic thrombectomy was performed in the right sigmoid and transverse sinuses and the posterior third of the SSS. However, the AngioJet could not be further advanced into the anterior SSS because the approach from the femoral vein did not provide sufficient support.

The AngioJet catheter was advanced from a cervical puncture site in the left internal jugular vein into the anterior third of the SSS, and rheolytic thrombectomy of the entire SSS and left transverse sinus was performed. Then, the AngioJet catheter was placed in the straight sinus at the junction with the vein of Galen, and rheolytic thrombectomy

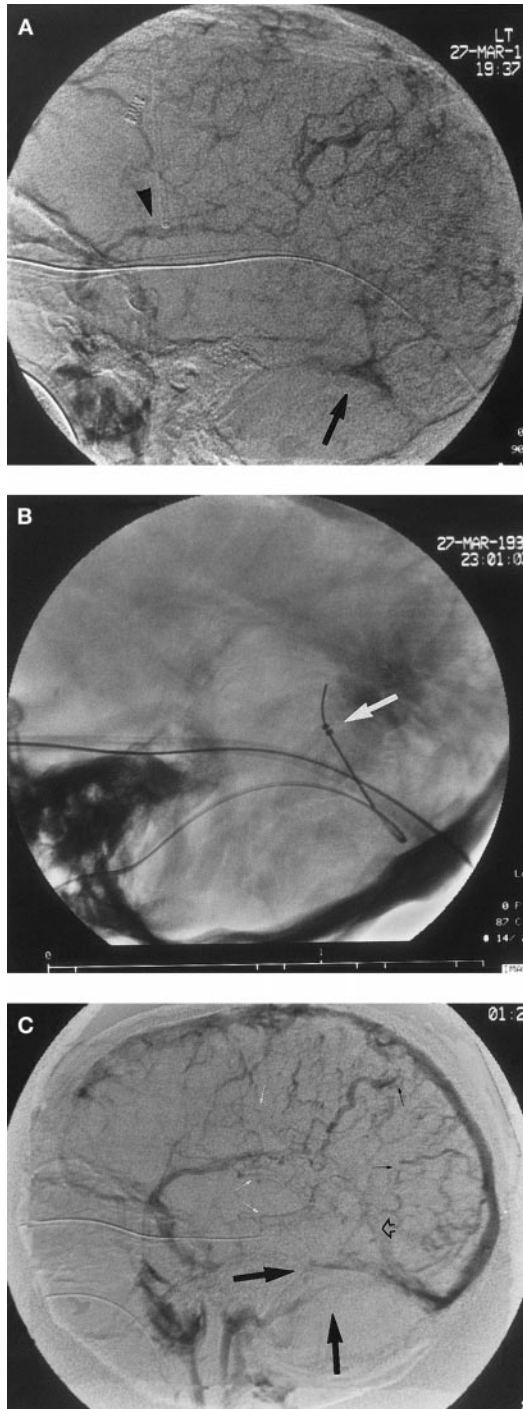


Figure 3. A, Right internal carotid angiogram (late venous phase, lateral view). None of the SSS, straight sinus, or left transverse/sigmoid sinus is visualized. The right transverse sinus is poorly seen (arrow), and the venous drainage is mostly anterior through the middle cerebral vein (arrowhead), cavernous sinus, and pterygoid plexus. B, Unsubtracted lateral view during rheolytic thrombectomy of the straight sinus with the AngioJet (arrow). C, Right internal carotid angiogram (lateral view, venous phase) performed after rheolytic thrombectomy of the SSS, straight sinus, and bilateral transverse/sigmoid sinus and after intracarotid and vein of Galen thrombolysis. The SSS has fully reopened. The right and left transverse sinuses (large arrows) and straight sinus (open arrow) are partially seen. Opacification of the deep venous system is faint but present (small white arrows: inferior sagittal sinus, internal cerebral vein, and basal vein). There are persistent cortical vein occlusions (small arrows).

of the straight sinus was performed. Repeat cerebral angiograms at the vein of Galen showed patency of the major sinuses with extensive persistent cerebral vein thromboses, including multiple cortical veins and both internal cerebral veins.

During the next 4 hours, 400 000 IU urokinase was infused intra-arterially into the ICAs (50 000 IU during 30 minutes alternatively in each ICA), and 100 000 IU urokinase was infused directly into the vein of Galen. Repeat angiography showed improvement in visualization of the superficial cortical veins and straight sinus (Figure 3B).

After the procedure, the patient was clinically unchanged, but the CT scan showed increased hemorrhage around the ventriculostomy drain and within the ventricles. Heparin was continued. On the next day, follow-up angiography revealed resistant thrombi in the deep venous system and in multiple cortical veins overlying the parietal lobes. The infusion of an additional 100 000 IU urokinase into each ICA and 100 000 IU urokinase into the vein of Galen during 2 hours resulted in mild improvement in visualization of the cortical veins and deep venous system. Follow-up CT scan immediately after this second procedure showed no worsening of the intracranial hemorrhage.

However, during the next 2 days, CT scans showed small venous hemorrhagic infarcts in the left parietal region, an enlargement of hemorrhage around the ventriculostomy drain to a 2-cm frontal hematoma, and increased intraventricular hemorrhage. Systemic heparin was stopped. Despite these findings on CT, the patient became more alert and regained strength in all 4 extremities. On postprocedure day 3, the patient elected to undergo therapeutic dilatation and curettage. On postprocedure day 4, the ventriculostomy drain was removed. On postprocedure day 6, the patient developed a pelvic deep venous thrombosis, and a Greenfield inferior vena caval filter was placed.

MRI on postprocedure day 6 showed patent dural sinuses without evidence of new intracranial bleeding. The patient was neurologically normal at that time and was restarted on heparin. The results of a hypercoagulable laboratory panel showed weakly positive dilute Russell viper venom times, which suggested the presence of anti-phospholipid antibodies. The patient was negative for activated protein C resistance and prothrombin gene mutation. On postprocedure day 12, the patient was discharged home on warfarin and carbamazepine. At a 6-month follow-up in the neurology clinic, the patient had a normal neurological examination except for mild deficit in short-term recall.

Discussion

We describe 2 cases of dural sinus thrombosis treated with the combination of rheolytic thrombectomy to recanalize the major intracranial sinuses and low-dose intra-arterial thrombolysis to lyse associated thromboses in cerebral veins. To our knowledge, this combination of therapies has not been previously described.

Because of the variable natural history of dural sinus thrombosis, it can be difficult to determine the extent to which aggressive therapy should be pursued. Both patients described here were young and otherwise healthy, with severe

progressive neurological symptoms despite adequate anticoagulation with heparin. Both were also at risk of extending preexisting intracranial hemorrhages, so the thrombolytic dose was minimized after the AngioJet treatment. Furthermore, patient 2 had occlusion of both deep and superficial venous drainage, a prognostic sign that indicates a poor prognosis and possible death.¹¹ Therefore, the AngioJet catheter was used for accelerated lysis of the large thrombi in the venous sinuses, and then low-dose intra-arterial thrombolysis was used for the remaining occlusions of the cortical veins.

The AngioJet is a double-lumen guidewire-directed catheter with an outer diameter of 5F that tapers to 3.5F, introduced within a 7F or an 8F guiding catheter. Three high-pressure saline jets exit the catheter at a pressure of 2500 psi and are directed into the catheter exhaust lumen. Based on the Bernoulli principle, a vacuum is created to fragment and aspirate the thrombus through the catheter.³¹ Use of the device has been reported in the treatment of occluded coronary arteries in myocardial infarction,^{34,35} saphenous vein grafts obstructed by atherosclerosis and thrombus,³⁶ acute limb ischemia,^{36,37} pulmonary embolism, and in combination with stents in coronary arteries.³⁸

The application of the AngioJet catheter to the treatment of dural sinus thrombosis has many potential benefits. First, the AngioJet catheter is one of the few available options when high doses of thrombolytic agents are contraindicated. More importantly, the bulk of thromboses in the dural sinuses are large compared with those occurring within the cerebral arteries, because the caliber of the sinuses is much larger than that of arteries.³³ Even locally delivered thrombolytic agents can require a substantial amount of time to completely lyse a massive clot; previous studies have documented thrombolytic infusions of 88 to 244 hours, with an average of 171 hours (7.13 days).^{21,26} In contrast, the AngioJet catheter accomplished recanalization of the major dural sinuses in a 2- to 4-hour procedure, thus limiting the potential of the development of cerebral edema, mass effect, venous hypertension, and resultant infarction.

Limitations to the use of the AngioJet include its large size and stiffness. These characteristics make navigation difficult and prevent access to smaller cerebral arteries and veins. In its present state, the AngioJet is not sufficiently supple to be easily passed through the tortuous intracranial sinuses; therefore, it requires a significant amount of force at the distal end. To maximize the force applied to the catheter, direct cervical puncture of the internal jugular vein was performed for placement of a 5F sheath in patient 2; from this location, the AngioJet was easier to manipulate and could be advanced to all major intracranial sinuses, including the straight sinus. Because the walls of the sinuses are thick dura mater, with a low risk of rupture, catheterization of all sinuses with the AngioJet catheter is relatively safe. This is not the case, however, for cerebral veins or the vein of Galen. The walls of these structures are thin and fragile and associated with an increased risk of rupture and cerebral hemorrhage. Therefore, thrombi in these locations should not be treated with the AngioJet and are ideally lysed with the direct infusion of

thrombolytic agents such as urokinase. This scenario occurred in both of our patients, as we described.

Another limitation of the AngioJet is its inability to dilate underlying organic stenoses,³⁸ as demonstrated in patient 1, in whom the tight stenoses in the transverse sinus necessitated balloon angioplasty to allow advancement of the AngioJet.

Positive angiographic and clinical results after the use of the AngioJet in the treatment of dural sinus thrombosis were first reported in 2 patients with bilateral transverse and SSS thromboses for whom anticoagulation therapy failed.^{32,33} In the 2 patients described here, the AngioJet was used to recanalize occluded intracranial sinuses. Intra-arterial urokinase was infused to reopen the remaining occlusions in the cortical veins and deep cerebral veins; we believe intra-arterial delivery results in an increased concentration of the thrombolytic agent within the cortical veins compared with intrasinus infusion. To our knowledge, this application of intra-arterial thrombolysis has not been described in the literature.

The optimal treatment for dural sinus thrombosis is unclear. The combination of the AngioJet rheolytic thrombectomy catheter with intra-arterial thrombolysis may offer a new option in patients with extensive thromboses of the dural sinuses and cerebral veins with resultant progressive neurological deterioration. This treatment modality allows for accelerated recanalization of occluded dural sinuses and cerebral veins with lower doses of thrombolytic agents administered during a short time period. Further comparative studies may help clarify the role of AngioJet versus other therapeutic regimens for the treatment of severe dural sinus thrombosis.

References

- Ehlers H, Courville CB. Thrombosis of internal cerebral veins in infancy and childhood: review of the literature and report of five cases. *J Pediatr*. 1936;8:600–623.
- Kalbag RM, Woolf AL. *Cerebral Venous Thrombosis*. London, UK: University Press; 1967.
- Ameri A, Bousser MG. Cerebral venous thrombosis. *Neurol Clin*. 1992; 10:87–111.
- Atkinson EA, Fairburn B, Heathfield KWG. Intracranial venous thrombosis as a complication of oral contraception. *Lancet*. 1970;1: 914–918.
- Gerszten PC, Welch WC, Spearman MP, Jungreis CA, Redner RL. Isolated deep cerebral venous thrombosis treated by direct endovascular thrombolysis. *Surg Neurol*. 1997;48:261–266.
- Spearman MP, Jungreis CA, Wehner JJ, Gerszten PC, Welch WC. Endovascular thrombolysis in deep cerebral venous thrombosis. *AJNR Am J Neuroradiol*. 1997;18:502–506.
- Muramatsu S, Mizuno Y, Murayama H, Ikemoto S. Hereditary anti-thrombin III deficiency with a superior sagittal sinus thrombosis: evidence for a possible mutation starting in the mother of the propositus. *Thromb Res*. 1990;57:593–600.
- Haley JCE, Brashear R, Barth JT, Cail WS, Kassell NF. Deep cerebral venous thrombosis: clinical, neuroradiological, and neuropsychological correlates. *Arch Neurol*. 1989;46:337–340.
- Smith AG, Cornblath WT, Deveikis J. Local thrombolytic therapy in deep cerebral venous thrombosis. *Neurology*. 1997;48:1613–1619.
- Scott JA, Pascuzzi RM, Hall PV, Becker GJ. Treatment of dural sinus thrombosis with local urokinase infusion. *J Neurosurg*. 1988;68: 284–288.
- Bousser MG, Chiras J, Bories J, Castaigne P. Cerebral venous thrombosis: a review of 38 cases. *Stroke*. 1985;16:199–213.
- Hanley DF, Feldman E, Borel CO, Rosenbaum AE, Goldberg AL. Treatment of sagittal sinus thrombosis associated with cerebral hemorrhage and intracranial hypertension. *Stroke*. 1988;19:903–909.

13. Einhäupl KM, Villringer A, Meister W, Mehraein S, Garner C, Pellkofer M, Haberl RL, Pfister HW, Schmiedek P. Heparin treatment in sinus venous thrombosis. *Lancet*. 1991;338:597–600. Erratum in *Lancet* 1991; 12:958.
14. Barnwell SL, Higashida RT, Halbach VV, Dowd CF, Hieshima GB. Direct endovascular thrombolytic therapy for dural sinus thrombosis. *Neurosurgery*. 1991;28:135–142.
15. Vines FS, Davis DO. Clinical-radiological correlation in cerebral venous occlusive disease. *Radiology*. 1971;98:9–22.
16. Di Rocco C, Iannelli A, Leone G, Moschini M, Valori VM. Heparin-urokinase treatment in aseptic dural sinus thrombosis. *Arch Neurol*. 1981; 38:431–435.
17. Sindou M, Mercier P, Bokor J, Brunon J. Bilateral thrombosis of the transverse sinuses: microsurgical revascularization with venous bypass. *Surg Neurol*. 1980;13:215–220.
18. Kim SY, Suh JH. Direct endovascular thrombolytic therapy for dural sinus thrombosis: infusion of alteplase. *AJNR*. 1997;18:639–645.
19. Higashida RT, Helmer E, Halbach VV, Hieshima GB. Direct thrombolytic therapy for superior sagittal sinus thrombosis. *AJNR Am J Neuroradiol*. 1989;10:S4–S6.
20. Bookstein JJ, Fellmeth B, Roberts A, Valji K, Davis G, Machado T. Pulse-spray pharmacomechanical thrombolysis: preliminary clinical results. *AJR Am J Roentgenol*. 1989;122:1097–1100.
21. Rael JR, Orrison WW Jr, Baldwin N, Sell J. Direct thrombolysis of superior sagittal sinus thrombosis with coexisting intracranial hemorrhage. *AJNR Am J Neuroradiol*. 1997;18:1238–1242.
22. Persson L, Lilja A. Extensive dural sinus thrombosis treated by surgical removal and local streptokinase infusion. *Neurosurgery*. 1990;26: 117–121.
23. Aoki N, Uchinuno H, Tanikawa T, Kagawa M, Takakura K. Superior sagittal sinus thrombosis treated with combined local thrombolytic and systemic anticoagulation therapy. *Acta Neurochir*. 1997;139:332–335.
24. Horowitz M, Purdy P, Unwin H, Carstens G 3rd, Greenlee R, Hise J, Kopitnik T, Batjer H, Rollins N, Samson D. Treatment of dural sinus thrombosis using selective catheterization and urokinase. *Ann Neurol*. 1995;38:58–67.
25. Tsai FY, Wang AM, Matovich VB, Alfieri K. MR staging of acute dural sinus thrombosis: correlation with venous pressure measurements and implications for treatment and prognosis. *AJNR Am J Neuroradiol*. 1992; 13:1137–1141.
26. Smith TP, Higashida RT, Barnwell SL, Halbach VV, Dowd CF, Fraser KW, Teitelbaum GP, Hieshima GB. Treatment of dural sinus thrombosis by urokinase infusion. *AJNR Am J Neuroradiol*. 1994;15:801–807.
27. Frey JL, Muro GJ, McDougall CG, Dean BL, Jahnke HK. Cerebral venous thrombosis: combined intrathrombus rtPA and intravenous heparin. *Stroke*. 1999;30:489–494.
28. Griesemer DA, Theodorou AA, Berg RA, Spera TD. Local fibrinolysis in cerebral venous thrombosis. *Pediatr Neurol*. 1994;10:78–80.
29. Frey JL, Hasan S, Dean BL, Hodak J, Borden N. Intrathrombus administration of rt-PA in intracranial venous thrombosis. *Neurology*. 1996; 46(suppl):255. Abstract.
30. Renowden SA, Oxbury J, Molyneux AJ. Case report: venous sinus thrombosis: the use of thrombolysis. *Clin Radiol*. 1997;52:396–399.
31. Muller-Hulsbeck S, Bangard C, Schwarzenberg H, Gluer CC, Heller M. In vitro effectiveness study of three hydrodynamic thrombectomy devices. *Radiology*. 1999;211:433–439.
32. Scarrow AM, Williams RL, Jungreis CA, Yonas H, Scarrow MR. Removal of a thrombus from the sigmoid and transverse sinuses with a rheolytic thrombectomy catheter. *AJNR Am J Neuroradiol*. 1999;20: 1467–1469.
33. Dowd CF, Malek AM, Phatouros CC, Hemphill JC III. Application of a rheolytic thrombectomy device in the treatment of dural sinus thrombosis: a new technique. *AJNR Am J Neuroradiol*. 1999;20:568–570.
34. Nakagawa Y, Matsuo S, Yokoi H, Tamura T, Kimura T, Hamasaki N, Nosaka H, Nobuyoshi M. Stenting after thrombectomy with the AngioJet catheter for acute myocardial infarction. *Cathet Cardiovasc Diagn*. 1998; 43:327–330.
35. Nakagawa Y, Matsuo S, Kimura T, Yokoi H, Tamura T, Hamasaki N, Nosaka H, Nobuyoshi M. Thrombectomy with AngioJet catheter in native coronary arteries for patients with acute or recent myocardial infarction. *Am J Cardiol*. 1999;83:994–999.
36. Silva JA, Ramee SR, Collins TJ, Jenkins JS, Lansky AJ, Ansel GM, Dolmatch BL, Glickman MH, Stainken B, Ramee E, White CJ. Rheolytic thrombectomy in the treatment of acute limb-threatening ischemia: immediate results and six-month follow-up of the multicenter AngioJet registry: POSSIS Peripheral AngioJet Study AngioJet Investigators. *Cathet Cardiovasc Diagn*. 1998;45:386–393.
37. Muller-Hulsbeck S, Brossmann J, Heller M. [Percutaneous therapy of occlusions of calf arteries with newly developed hydrodynamic thrombectomy catheter, AngioJet LF140]. *Rofo Fortschr Geb Rontgenstr Neuen Bildgeb Verfahr*. 1998;168:514–517.
38. Nobuyoshi M, Nakagawa Y. AngioJet thrombectomy catheter for the thrombus-laden lesions. *Cathet Cardiovasc Diagn*. 1998;45:394–395.