



Selecting Treatment in Patients with Epilepsy

Ilo E. Leppik & J. Richard Baringer

To cite this article: Ilo E. Leppik & J. Richard Baringer (2000) Selecting Treatment in Patients with Epilepsy, *Hospital Practice*, 35:5, 35-52, DOI: [10.3810/hp.2000.05.197](https://doi.org/10.3810/hp.2000.05.197)

To link to this article: <https://doi.org/10.3810/hp.2000.05.197>



Published online: 24 Jun 2015.



Submit your article to this journal [↗](#)



Article views: 4



View related articles [↗](#)



Citing articles: 2 View citing articles [↗](#)

Selecting Treatment in Patients with Epilepsy

ILO E. LEPIK

University of Minnesota

COMMENTARY

J. RICHARD BARINGER

University of Utah

With improved understanding of epileptic syndromes during the past decade, the number of antiepilepsy medications has increased. Successful treatment starts with accurate diagnosis, because antiseizure drugs are fairly specific for particular syndromes and because surgery in some cases is superior to medical therapy.

CASE PRESENTATION

A 16-year-old girl experienced a generalized tonic-clonic seizure. Because the seizure had occurred while she was sleep deprived, it was hoped that it would be an isolated event, and she was not treated. Two years later, however, she had a second seizure of the same type. A 30-minute electroencephalogram (EEG) was normal, and no metabolic causes were found on the blood tests. The patient was started on carbamazepine therapy.

The patient went to college, where she continued to have seizures despite treatment. She became concerned that carbamazepine was affecting her ability to learn. At age 20, she was referred to an epilepsy center, where she was evaluated with a three-hour EEG. At the end of the EEG, a few seconds of generalized 3-4 Hertz spike and wave discharge occurred, which is pathognomonic for juvenile myoclonic epilepsy. Carbamazepine was replaced with valproic acid. During the next four years, no seizures occurred, and the patient experienced very few side effects from valproic acid.

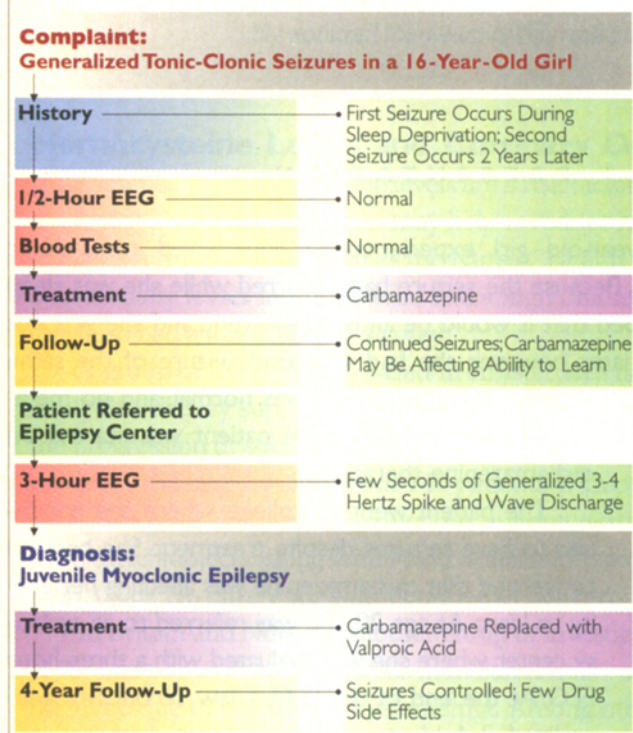
When a patient presents with epilepsy, the first step is to make sure that the epileptic syndrome is properly diagnosed. In this case, the initial diagnosis was incorrect.

As recently as a decade ago, syndrome diagnosis was not of great clinical importance because the therapeutic options for epilepsy were limited. Today, however, it is known that the many epileptic syndromes respond differently to available medications. Thus, it is important to identify the specific syndrome. This can be achieved with the history and diagnostic testing.

Epileptic syndromes can be categorized into two broad types: localization-related or generalized. Localization-related epilepsy involves an abnormality in a focal area of the central nervous system (CNS) that

Dr. Leppik is Clinical Professor of Neurology and of Pharmacy Practice, University of Minnesota Medical School—Minneapolis and Director of Research, MINCEP® Epilepsy Care. Dr. Baringer is Professor and Chairperson, Department of Neurology, University of Utah School of Medicine, Salt Lake City.

Case 1 Algorithm



triggers a partial seizure (also known as psychomotor, simple motor, or Jacksonian seizures). The seizures in localization-related epilepsy result from the propagation of abnormal electrical discharges from the focal abnormality to the rest of the brain.

The vast majority of adult-onset disease is localization-related. In children, on the other hand, the most common type is generalized epilepsy. Instead of a focal area of damage, there may be a fundamental abnormality of the inhibitory-excitatory mechanisms in the brain. These may be present on a cellular or a synaptic level.

An example of generalized disease is juvenile myoclonic epilepsy, a genetic disorder. Recently, the gene locus was postulated to be on the short arm of chromosome 6. Affected patients show a very spe-

cific EEG pattern; indeed, the pattern is virtually pathognomonic. Since the abnormality occurs at the cellular level, magnetic resonance imaging (MRI) is not very helpful in the diagnosis of juvenile myoclonic epilepsy—or other types of generalized epilepsy—but can be very helpful in patients with localization-related epilepsy.

Because the pathophysiologies of localization-related and generalized epilepsy are different, it follows that the choice of medication also differs. In localization-related epilepsy, an antiepileptic drug's effect on the sodium channel is of critical importance. Normally, the sodium channel opens to allow an action potential to develop and then closes at a certain frequency. During initiation or propagation of epileptic seizures, the sodium channel may fire (i.e., open and close) much more rapidly than normal. Many antiepileptic drugs exert a fairly strong action on the sodium channel. Phenytoin and carbamazepine act almost exclusively on the sodium channel, whereas other drugs, such as valproic acid, have additional mechanisms. Thus, initial treatment in a patient with localization-related epilepsy is generally with phenytoin or carbamazepine.

Other drugs used to treat localization-related epilepsy include tiagabine and gabapentin. Both agents elevate γ -aminobutyric acid (GABA) levels; the former does this extracellularly by preventing GABA reuptake while the latter increases intracellular GABA levels. Both are very effective treatments for localization-related epilepsy, (i.e., simple partial motor seizures, complex motor seizures, secondarily generalized tonic-clonic seizures).

With generalized epilepsies, such as juvenile myoclonic epilepsy, the sodium-channel drugs will be of little benefit; indeed, they may actually exacerbate the seizures—hence the failure of carbamazepine to provide seizure control in this patient. Similarly, phenytoin, tiagabine, and gabapentin can exacerbate

absence seizures (sudden momentary breaks in thought or activity) in children. On the other hand, not all epilepsy in children is generalized; head injuries can cause localization-related epilepsy in young patients, for whom sodium-channel anticonvulsants may be the most appropriate treatment.

CASE 2 PRESENTATION

A 54-year-old man presented with simple partial seizures. The seizures did not result in confusion or loss of consciousness but were nevertheless troubling because they affected motor activity. Treatment with phenytoin was begun, and the seizures were brought under control when drug blood levels reached 15 to 16 mcg/mL.

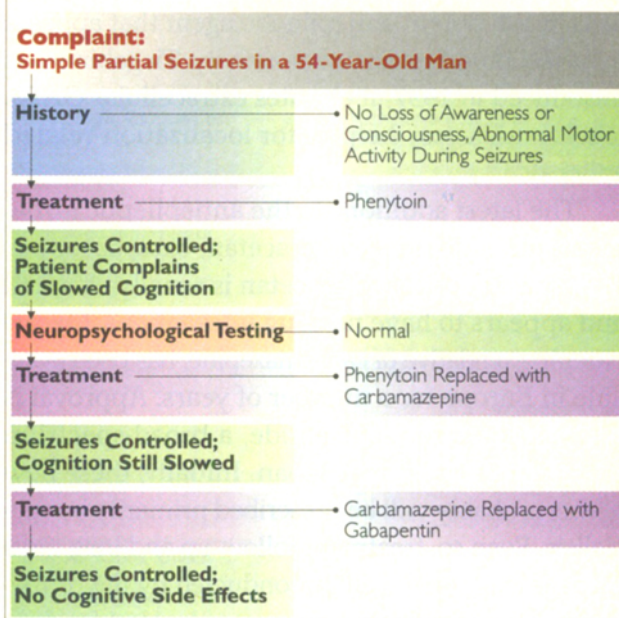
The patient, who operated his own business, complained that phenytoin was slowing his thinking, although this could not be detected with standard neuropsychological testing. Phenytoin was replaced with carbamazepine, which controlled the seizures but also was associated with a slowing of cognitive functioning. Carbamazepine was replaced with gabapentin, which did not cause any cognitive side effects. The patient has been free of seizures for three years.

Quality-of-life issues are an important consideration in the treatment of patients with epilepsy. Paramount among these are unacceptable drug side effects. In highly functioning patients such as this man, cognitive slowing may be such a side effect. It may be undetectable on neuropsychological testing yet very evident to the patient.

Side effects can be particularly problematic with some of the older antiepileptic medications. Fortunately, physicians today have a much wider selection of agents.

Phenytoin, which was introduced in 1938, remains the most widely used antiepileptic medication

Case 2 Algorithm



but is losing ground rapidly to newer agents. Primidone was introduced in the 1950s, carbamazepine in 1974, and valproic acid in 1978. After that, there was a hiatus in the introduction of new agents the United States, partly because of changes in federal law related to proof of efficacy.

In 1993, felbamate became available. Although it is very powerful and has a broad spectrum of activity, the use of felbamate is limited because of rare cases of aplastic anemia and hepatic failure. Gabapentin was also introduced in 1993. Although very helpful for localization-related epilepsy, it may exacerbate generalized epilepsy. Lamotrigine became available in 1994; it is a broad-spectrum drug that can be used to treat both primary and localization-related epilepsies.

Fosphenytoin, created specifically for intramuscular intravenous use, became available in 1996. It is much safer and easier to administer than par-

entral phenytoin. Topiramate also became available in 1996. Although it may produce CNS side effects, it is a potent antiepileptic agent that appears to have a broad spectrum of activity. Tiagabine was introduced in 1997; it elevates extracellular GABA levels and is very helpful for localization-related epilepsy.

The latest additions to the antiepileptic armamentarium include levoteracetan, oxcarbazepine, and zonisamide. Levoteracetan is renally excreted and appears to have no drug interactions. Oxcarbazepine, a relative of carbamazepine, has been available in Europe for a number of years. Approval is also expected for zonisamide, a broad-spectrum antiepileptic drug from Japan. Initially, these new agents probably will be prescribed primarily by specialists. Even so, treatment follow-up and long-term management may well be conducted by the primary care physician, who will have to be alert for drug side effects.

Almost all the drugs that are used to treat epilepsy have some minor side effects, especially at higher doses. As with any drugs that affect the CNS, they may cause fatigue, sleepiness, difficulty in concentrating, and difficulty with rapid mental calculations. Although that holds for both new and old medications, the newer drugs in general appear to have fewer cognitive side effects and less risk of teratogenicity.

CASE 3 PRESENTATION

CA 24-year-old woman was referred for neurologic evaluation after experiencing a single seizure at night. Test results were unremarkable except for minor EEG abnormalities. Carbamazepine was prescribed, but the patient sought a second opinion because she was uncomfortable with the drug's side effects.

The history taken by the second neurologist revealed that the patient's older brother had had seizures when he was in his 20s. Another and longer EEG showed specific epileptiform discharges consistent with primary generalized epilepsy. Carbamazepine was replaced with lamotrigine, which the patient tolerated well.

Even though this patient had had only one seizure during the first 24 years of life, that finding plus the sibling's history was persuasive enough to prompt the second neurologist to recommend antiepileptic medication. Given a diagnosis of generalized epilepsy, the drug of choice would be valproic acid. However, since this patient wanted to have children, she was given lamotrigine. Although more expensive, lamotrigine appears to be associated with a lower incidence of birth defects.

What is the best approach to the evaluation and treatment of an adult patient who has had a single seizure? New epidemiologic studies have shown that a patient who has had a single seizure as an adult has approximately a 25% risk of having a second seizure within the next two years. The probability may be significantly higher in the presence of certain other risk factors.

A family history of epilepsy is significant, and the most significant risk factor is a brother or sister who has had a seizure from any cause at any time. A patient with a positive sibling history has a 60% to 70% risk of a second seizure within two years of the first episode and probably should be treated. The choice of drug depends on the syndrome. Most patients with a history of sibling seizures have familial epilepsy, which is usually best treated with valproic acid or one of the generalized epilepsy medications.

Careful questioning may also reveal a previously unrecognized seizure; for example, the pa-

tient may have had a head injury some years earlier that was soon followed by a seizure. Also, any history of CNS damage, such as a closed head injury with unconsciousness lasting more than 24 hours, a penetrating skull injury, or a stroke, would indicate high risk. Such patients have a greater than 50% risk of a second seizure within two years and should be treated.

The EEG is also critical. If it shows any recognizable seizure pattern, either of generalized or localization-related epilepsy, the patient should be started on appropriate antiepileptic medication.

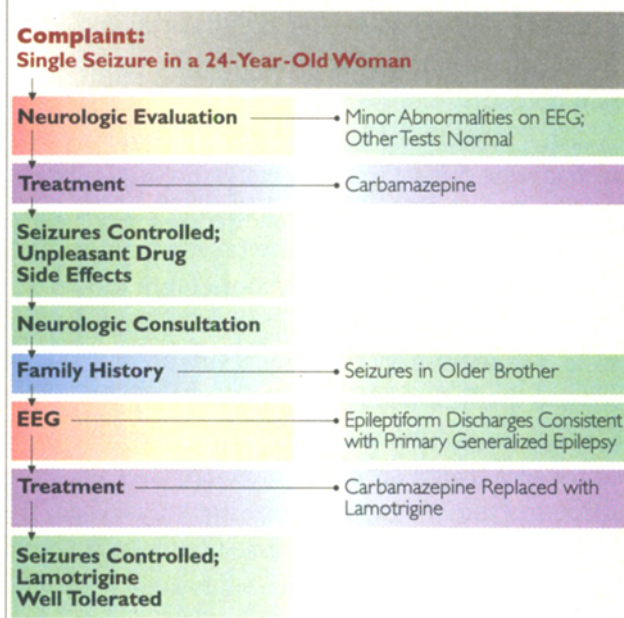
In the majority of patients with a single seizure, however, the evaluation is completely normal; the history, EEG, and MRI reveal nothing. Should these patients be treated?

If the patient lives in a major metropolitan area with good public transportation (so that driving is not an issue), and drug side effects are of concern, it may be reasonable to forgo therapy. Provided that the physician and patient come to a mutual decision not to treat, that choice in my opinion is perfectly acceptable medical practice. On the other hand, if the patient is concerned about that one-in-four chance of having a second seizure in two years, or driving is a major part of the patient's life, then it is reasonable to consider medical therapy for the next two years.

What about the patient who had a single seizure several years earlier, was placed on medication by another physician, and now wants to know whether the medication can be discontinued? Again, by today's standards, it is not good enough for the patient simply to say, "I have epilepsy." The physician needs to know what epileptic syndrome is involved.

If the patient cannot specify the type of epilepsy, an adequate syndrome diagnosis probably was not made, and the most appropriate medication may not have been prescribed. Or the patient may be tak-

Case 3 Algorithm



ing medication unnecessarily. In 66% of adults who were diagnosed with epilepsy some years earlier, the disease is in remission and medication is no longer required. Alternatively, the patient may never have needed medication because he or she does not in fact have epilepsy. Nonepileptic or psychogenic seizures make up a significant proportion of cases labeled as epileptic.

The primary care physician may not be in a good position to decide whether to withdraw antiepileptic medication. If the patient has been taking the drug for years after experiencing only one seizure, it is probably reasonable to consider discontinuing the medication, provided that the patient feels comfortable with that option. The situation is more complex if the patient had many seizures a number of years ago and does not know what kind they were. Such patients may have outgrown the epileptic syndrome and no longer need the medicine. On the other hand,

in patients with juvenile myoclonic epilepsy who have been on successful treatment for a decade, seizures will recur as soon as the medication is withdrawn. Their seizures result are caused by a permanent defect.

Any patient who has not had an updated epilepsy diagnosis during the last decade probably should be reevaluated. The workup does not necessarily involve elaborate testing (many familial syndromes can be diagnosed by history alone), but it does require thorough knowledge of the differential diagnosis. Many primary care physicians are unlikely to possess that knowledge. A survey by the Epilepsy Foundation of America found that the average generalist sees five or six cases of epilepsy a year in the office and might encounter one new case of epilepsy or seizures every two or three years. With such limited exposure, it can be difficult to keep up to date on the latest advances in the field. Thirty years ago, that really did not matter because there were only two or three drugs available for treatment. With the therapeutic choices available today and the knowledge that inappropriate drugs may actually worsen an epileptic syndrome, keeping up to date is very important indeed.

CASE 4 PRESENTATION

A 19-year-old man presented with a generalized tonic-clonic seizure. On history, he noted that he had had a febrile convulsion during infancy.

After treatment with phenytoin was initiated, no generalized seizures occurred, but the patient continued to experience one- to three-minute episodes of automatic behavior followed by a few minutes of confusion. He was unable to recall any events that took place during those episodes.

He was referred to an epilepsy center, where he

was evaluated with a two-day screening battery. A three-hour video EEG showed spikes in the right temporal lobe, neuropsychological testing showed impaired visual memory, and MRI confirmed mesial temporal sclerosis. Injection of sodium amytal into the right carotid artery (the Wada test) showed no significant reduction in visual memory.

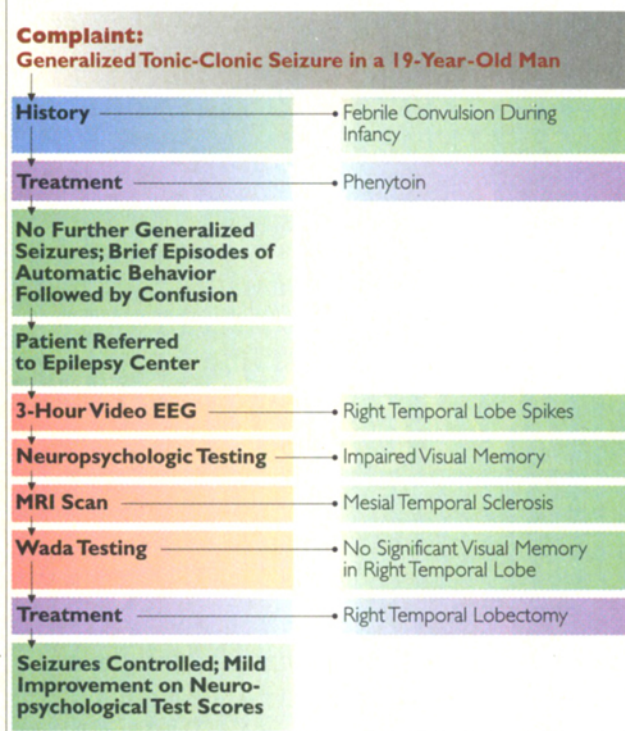
The patient underwent right temporal lobectomy. Surgery was completed without complications, and the patient was discharged five days later. Three weeks later, he was able to resume normal activity. He experienced no more seizures. Subsequent neuropsychological testing showed mild improvement in test scores.

Some epileptic syndromes are very amenable to surgery. The most common example is mesial temporal sclerosis. In our clinic, mesial temporal lobe epilepsy is found in a high percentage of patients with seizures that have resisted pharmacologic control for many years.

The typical history in patients with mesial temporal sclerosis includes one or a series of febrile convulsions before age two. While sensitive, this finding is not specific, since most children with febrile convulsions do not have epilepsy later in life. Characteristically, complex partial seizures then begin in the teenage years or early adulthood. These seizures, which used to be known as temporal lobe seizures, may be heralded by a generalized tonic-clonic seizure. As in this case, however, when patients are placed on antiepileptic medication that blocks the propagation of impulses, the generalized tonic-clonic seizure may be controlled while complex partial seizures continue to occur.

Complex partial seizures involve impairment of consciousness and automatic behavior. Although they may not be as physically violent as generalized tonic-clonic seizures, they nevertheless impose ma-

Case 4 Algorithm



for limitations on driving, education, and other functions of living. Moreover, in a patient who has frequent seizures, the electrical disturbances will cause a definite reduction in mental capabilities.

With today's technology, mesial temporal sclerosis is relatively easy to identify. At our clinic, we use a two-day outpatient screening battery that includes an EEG, neuropsychological testing, and a high-quality MRI scan.

Neuropsychological testing is included because many patients have subtle but detectable specific memory defects. For example, the right temporal lobe usually handles figural and pictorial memory, whereas the left temporal lobe usually handles language memory. Careful testing for visual and language memory will often uncover abnormalities in

patients with mesial temporal sclerosis.

The MRI must be done with a late-model scanner that is capable of special sequencing and angulations through the temporal lobes. With such equipment and a properly obtained scan, one can often see mesial temporal sclerosis

I consider the patient to be a candidate for surgery when the EEG shows spikes in one temporal lobe, neuropsychological testing shows memory difficulty appropriate to that side, and an MRI scan shows mesial temporal sclerosis on that side. In patients with unilateral mesial temporal sclerosis, the outcome after surgery is excellent. At many epilepsy centers in the United States, approximately 80% of such patients with intractable epilepsy (i.e., many seizures a year) are rendered seizure-free or have only rare seizures five years after surgery. In addition, because it is well known that both old and new antiepileptic medications usually do not control the seizures of mesial temporal sclerosis, I recommend that patients undergo surgery promptly, rather than attempting frustrating years of ineffective therapy.

After a surgically correctable temporal lobe lesion has been identified at our clinic, we inject sodium amytal into the left or right internal carotid artery to render one temporal lobe nonfunctional for about 10 to 15 minutes, while the patient remains fully awake. The Wada test provides an opportunity to assess what effect removal of the lobe will have on the patient's memory and speech. We have performed this test in more than 1,200 patients and have found it to be very reliable. Surgery is not performed in patients whose temporal lobe retains a significant degree of function. Lobectomy would leave such patients with a significant memory deficit.

In patients whose seizures began before age five or six, the Wada test usually indicates that all mem-

ory functions have shifted to the undamaged lobe. It is not at all unusual to encounter a patient with mesial temporal sclerosis and a history of a febrile convulsion before age two in whom initial neuropsychological testing shows normal visual and verbal memory. During the Wada test on the involved side, the patient has no loss of memory, but during testing of the contralateral side, both visual and verbal memory are lost. We can proceed to surgery in such cases confident that the involved temporal lobe is essentially nonfunctional and can be excised at little risk to the patient.

The surgery itself is not difficult; in fact, it is less difficult than arriving at the diagnosis. At most centers, surgeons perform a fairly standard amputation of the first 4 to 5 cm of the temporal lobe. Because the lobe is like an appendix, this is accomplished fairly easily. Most patients are discharged four to seven days after surgery and resume relatively normal function within a few weeks.

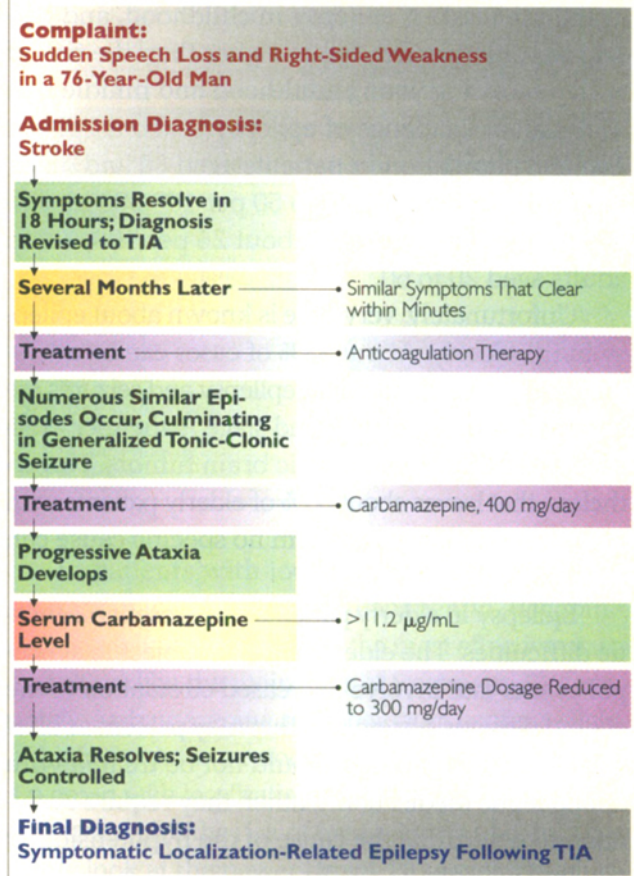
Interestingly, the patient's neuropsychological test scores often improve after temporal lobectomy. The reason is that if one lobe is emitting abnormal electrical activity on a regular basis before surgery, higher intellectual functioning is impaired, even though full-blown seizures may not have occurred.

CASE 5 PRESENTATION

A 76-year-old retired executive experienced sudden loss of speech and right-sided weakness. The diagnosis was stroke, but symptoms cleared within 18 hours. The discharge diagnosis was transient ischemic attack (TIA).

Several months later, the patient experienced similar symptoms, but this time they cleared within several minutes. The episodes then began to occur many times per month, despite treatment with anticoagulant drugs.

Case 5 Algorithm



Finally, he had a generalized tonic-clonic seizure.

Treatment with carbamazepine, 400 mg a day, was begun, after which gradually worsening ataxia developed. The carbamazepine serum level was 11.2 (µg/mL) (normal, 4-12 (µg/mL)). The dose was decreased to 300 mg, and the ataxia resolved.

The episodes of aphasia and weakness ceased. The patient's final diagnosis was symptomatic localization-related epilepsy after a TIA.

Epilepsy is more common in the elderly than in any other segment of the population. In the last

two decades, it has been found that the risk of epilepsy occurring after age 75 is three times higher than the risk of epilepsy in childhood, and perhaps as much as five times higher than the risk of epilepsy during young adulthood and middle age. The annual incidence of epilepsy is about 160 per 100,000 population in patients aged 80 and older, compared with about 40 to 50 per 100,000 in children under age five, and about 25 per 100,000 in adults aged 20 to 60.

Unfortunately, very little is known about epilepsy in the elderly. About 33% of cases can be attributed to a stroke. In addition, epilepsy and seizures are common in patients with end-stage Alzheimer's disease and in those metastatic brain tumors. Nevertheless, that leaves about 50% of elderly patients with new-onset epilepsy in whom no specific cause can be identified.

Epilepsy in elderly patients can present diagnostic difficulties. The elderly may be subject to syncope events that involve decreased circulation to the central nervous system and that may present as brief seizures. Such patients should not be treated with antiepileptic medication. Rather, they require evaluation to determine the cause of the hypotension or cerebral hypoxia.

Not uncommonly, the cause is a cardiac arrhythmia. I recently saw a woman in her 70s who had had epilepsy for a number of years. She presented with a new type of seizure—her husband reported that she would become pale, close her eyes, fall forward, and then wake up after 30 to 60 seconds. I thought that she might be having complex partial seizures. However, EEG video monitoring, which also includes cardiac rhythm monitoring, showed that the episodes were associated with periods of asystole, which usually lasted 15 to 20 seconds before symptoms occurred. Treatment was provided via a cardiac pacemaker.

The treatment of epilepsy in the elderly is complicated by the changes in drug metabolism that occur with age. There are very few data on the mechanisms and magnitude of those changes; consequently, I advise physicians not to prescribe the same dosages in elderly patients that they prescribe in young or middle-aged adults.

Phenytoin, for example, which is one of the most widely used drugs in the elderly, is highly protein-bound. Serum albumin levels tend to be reduced in the elderly, which increases drug availability; moreover, many elderly patients take drugs (e.g., aspirin) that compete with phenytoin for protein binding. Most commercial laboratories measure total phenytoin levels. That can be very misleading, because it is the unbound portion of the drug that is in equilibrium with the receptor sites in the brain. The usual therapeutic range for adults, 10 to 20 $\mu\text{g}/\text{mL}$, assumes normal protein-binding. For patients over age 65, I recommend a therapeutic range of 5 to 15 $\mu\text{g}/\text{mL}$. In the elderly, phenytoin levels above 16 $\mu\text{g}/\text{mL}$, or even above 10 $\mu\text{g}/\text{mL}$ in some cases, can result in dizziness, impaired balance, or fatigue. Measurement of the unbound, or free, phenytoin level can help determine whether such patients are receiving too much phenytoin or simply have symptoms of an aging nervous system.

CASE 6 PRESENTATION

A 22-year-old woman with juvenile myoclonic epilepsy presented for preconception counseling. Her seizures were well controlled with valproic acid. She was engaged to be married and was concerned about the possibility of birth defects from the medication. Her family history was notable for several cases of spina bifida.

Valproic acid was replaced with lamotrigine, after which the patient began to have myoclonic seizures.

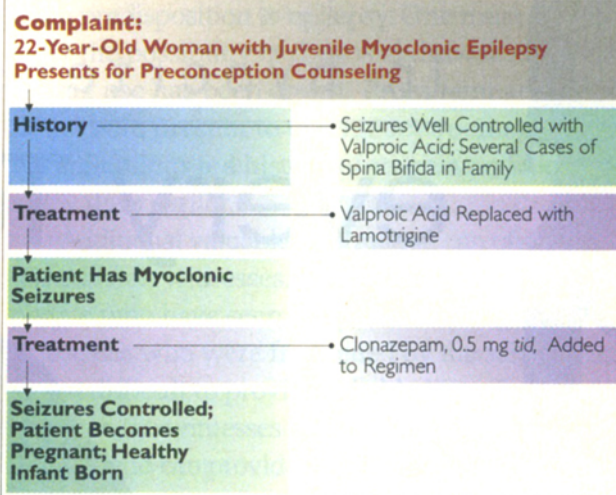
Clonazepam, 0.5 mg three times a day, was added to the regimen, and the myoclonic seizures ceased. She became pregnant and had a healthy infant.

Pregnancy in patients with epilepsy is an important topic because the older antiepilepsy medications—especially valproic acid, and to a lesser degree phenytoin and carbamazepine—have been associated with birth defects both in experimental animals and in humans. Most of the newer antiepilepsy drugs appear to be nonteratogenic in animal studies. There is not yet enough clinical experience to be absolutely certain that the newer agents will be safer, but there are many reasons to suspect that they will be. An ongoing registry will shortly provide definitive data on their teratogenicity.

One of the main fetal malformations associated with valproic acid is spina bifida. The risk for spina bifida in the offspring of a woman taking valproic acid is 1% to 2%, and the risk is greater with a family history of the disorder. Lamotrigine is turning out to be a very useful alternative in women with juvenile myoclonic epilepsy. It appears to be effective in controlling generalized tonic-clonic seizures, and so far has not been associated with major fetal malformations. Unfortunately, lamotrigine is not as effective for the myoclonic seizures that occur in this disorder, so it may be necessary to use a small amount of a benzodiazepine in conjunction with lamotrigine to achieve complete control.

Seizures during pregnancy are generally thought to pose a greater risk to the fetus than medication side effects do, so there is no point in switching a patient to an ineffective medication in order to obtain a slightly lower risk of teratogenicity. Hence, if valproic acid provides the best seizure control for a given patient, it may be preferable to keep her on that medication and to make sure that she receives sufficient supplementation with folic acid (2 - 4 mg/day).

Case 6 Algorithm



In patients with localization-related epilepsy, phenytoin, carbamazepine, gabapentin, tiagabine, and possibly lamotrigine are the most effective drugs and should be the mainstays of treatment. Unfortunately, carbamazepine and phenytoin confer a slightly higher risk for teratogenicity, so if I were treating a woman with localization-related epilepsy who wanted to minimize the risk of teratogenicity, I would certainly look at the newer drugs. However, Dutch researchers recently published a 20-year study on birth defects in women taking various epilepsy medications. Of 150 infants born to women taking phenytoin monotherapy, only one had a birth defect, which was the expected rate for that population. Phenytoin may not be as teratogenic as was once thought.

In the past, it was often customary to try to change medications after conception and to resume the preconception medication after birth. My colleagues and I have learned that this practice is not rational. The best medicine for a patient's epileptic syndrome should be started before conception and continued throughout pregnancy and beyond.

continues on page 51

continued from page 47

CASE COMMENTARY

J. RICHARD BARINGER
University of Utah

Epilepsy comprises a complex set of neurologic disorders that involve abnormal electrical activity in the brain and manifest in a wide variety of seizure types. During the past several decades, classification of the types into precise categories has occupied a generation of epileptologists and been the subject of numerous meetings of the International League Against Epilepsy and other organizations. The goal has been to construct a classification system that encompasses both causes and treatment of epilepsy. That goal has proved to be elusive; inevitably, a substantial proportion of epilepsy cases do not fit precisely into one of the proposed categories.

Leppik provides a far simpler scheme, dividing epileptic syndromes into just two categories: localization-related and generalized. The former are more commonly of adult onset and are associated with identifiable structural abnormalities on MRI. The onset of the latter more often occurs in childhood, and the syndromes tend not to be associated with anatomic anomalies.

In localization-related epilepsy, propagation of the seizure discharge stems from abnormalities in the sodium channel. Drugs that are effective against these epilepsies (e.g., phenytoin, carbamazepine, tiagabine, and gabapentin) may be ineffective in, or actually exacerbate, generalized epilepsies.

The cases that Leppik provides illustrate the extremely valuable information that can be obtained from detailed questioning of patients. Key points include seizures in childhood or infancy, head injury in childhood, and a sibling with epilepsy. I would add to this a history of taking drugs—whether

prescription (e.g., tricyclic antidepressants) or illicit—that may trigger seizures even in patients without a predisposition to epilepsy. One must also consider the possibility of drug withdrawal, especially if drug use has been covert. Prominent among patients who present to emergency rooms with status epilepticus is a history of stopping medications a few days earlier.

Additional valuable information can often be obtained from witnesses. It is important to interview people who have seen the patient during a seizure. Witnesses who were frightened by the seizure may find it difficult to provide reliable historical details, but often the witnesses have seen other persons with seizures and can provide precise observations. For instance, it is not unusual for a patient to experience a seizure as a consequence of syncope, particularly if well-meaning bystanders hold the patient upright during the syncopal event. Often a sophisticated witness is able to describe exactly which way the patient's head turned during the seizure and which arm or leg exhibited tonic or clonic activity.

Extra time spent eliciting historical information is often more helpful than the examination. Nevertheless, the physical and neurologic examinations are important; they may reveal neurocutaneous syndromes associated with seizures, evidence of head injury, lateralizing or focal disturbances (especially in the immediate postictal state), or papilledema.

On the subject of treatment, Leppik makes the valuable observation that modest side effects that are undetectable on neuropsychological testing may nevertheless significantly impair function, especially in patients whose jobs depend on a high level of intellectual performance. In my experience, physicians often focus so closely on seizure control that they overlook drug side effects. I have seen more than an occasional patient whose physician urged

him or her to take increasing doses of medication in order to maintain blood levels in the high therapeutic range, when lower therapeutic ranges would have adequately controlled the seizures with few or no side effects.

The goal of pharmacologic therapy is to eliminate seizures while minimizing side effects.

Achieving that goal may require considerable patience and persistence from both clinician and patient.

Leppik indicates the importance of identifying patients with mesial temporal sclerosis, a condition that can result in partial complex seizures refractory to medical management. Once this seizure has been diagnosed and its resistance to tolerable doses of medication has been established, appropriate investigation (including high-resolution MRI of the temporal lobe and Wada testing) can be performed to establish the feasibility of temporal lobectomy. It is clear that a substantial proportion of these patients can benefit greatly from surgical resection of the anterior portion of the temporal lobe. Often, they remain seizure-free without medication or with substantially lower doses of medication.

Patients with focally generated seizures outside the temporal lobe may benefit from similar intervention. In these patients, the seizure focus is identified with extensive monitoring, sometimes with the help of magnetoencephalography or intraoperatively placed grids. Local excision of the focal tissue may then bring relief from the refractory epilepsy syndrome.

Leppik describes two significant advances in epilepsy management: the development of less toxic and more effective antiepileptic drugs and of sophisticated tools for identifying and localizing seizure generators with high precision. These offer enormous

The goal of pharmacologic therapy is to eliminate seizures while minimizing side effects. Achieving that goal may require considerable patience and persistence.

promise for enhanced control of epilepsy in patients who heretofore have received only limited benefit from treatment. □

SELECTED READING

- Camfield PR et al. Epilepsy after a first unprovoked seizure in childhood. *Neurology* 35:1657, 1985
- Cloyd JC, Lackner TE, Leppik IE. Antiepileptics in the elderly: Pharmacoeconomics and pharmacokinetics. *Arch Fam Med* 3:589, 1994
- Dreifuss FE. The epilepsies: Clinical implications of the international classification. *Epilepsia* 31(Suppl 3):S3, 1990
- Hauser WA et al. Risk of recurrent seizures after two unprovoked seizures. *N Engl J Med* 338:429, 1998
- Leppik IE. Contemporary Diagnosis and Management of the Patient with Epilepsy, 4th ed. Handbooks in Health Care, Newtown, Penn., 1998
- Leppik IE. Compliance during the treatment of epilepsy. *Epilepsia* 29(Suppl 2):S79, 1988
- Mattson RH et al. Comparison of carbamazepine, phenobarbital, phenytoin, and primidone in partial and secondarily generalized tonic-clonic seizures. *N Engl J Med* 313:145, 1985
- Pellock JM, Willmore LJ. A rational guide to routine blood monitoring in patients receiving antiepileptic drugs. *Neurology* 41:961, 1991
- Zahn CA et al. Management issues for women with epilepsy: A review of the literature. *Neurology* 51:949, 1998