

TEMPORAL ARTERY BIOPSY IN HERPES ZOSTER OPTHALMICUS WITH DELAYED ARTERITIS

DAVID I. VICTOR, M.D., AND W. RICHARD GREEN, M.D.

Baltimore, Maryland

The syndrome of herpes zoster ophthalmicus with delayed hemiparesis has been well described.¹ Walker, Gammal, and Allen² recently documented angiographically a delayed unilateral segmental arteritis associated with herpes zoster ophthalmicus. Gilbert³ suggested that this arteritis was the same as "granulomatous arteritis," first described by Cravioto and Feigin⁴ in 1959. Two pathologically confirmed instances of granulomatous arteritis occurred following herpes zoster ophthalmicus.^{5,6} To date, five of the 20 reported cases of granulomatous arteritis, including two demonstrated only angiographically, had a prior history of herpes zoster ophthalmicus. Until now it has been impossible to document the diagnosis of herpes zoster ophthalmicus with delayed arteritis of the central nervous system without angiography or autopsy confirmation.

CASE REPORT

Unaccustomed to wearing shoes with high heels, this 58-year-old man fell and lightly struck his right forehead against a brick fireplace mantel. He sustained only a mild bruise. One week later, the patient developed a "gnawing" pain in his right eye and forehead. This was accompanied by an erythematous papulovesicular eruption over the right side of his forehead, nose, and face, with decreased sensation over the same region. Visual acuity was R.E.: 6/15 (20/50), and L.E.: 6/9 (20/30). The right eye was injected and contained 2+ aqueous flare and cells. Ophthalmoscopic findings were normal.

Five weeks later, the rash and iritis had almost cleared. During the fifth week, family members noted that the patient's behavior seemed strange. When seen here the following day, visual acuity was

R.E.: light perception, and L.E.: 6/9 (20/30). He was confused and inappropriately jocular. However, his language function and parietal-lobe functions were normal. Within two hours right visual acuity was 6/22 (20/70), and a dense left hemianopia of the left eye had evolved into a homonymous hemianopia. The right pupil was 7 mm and was sluggishly responsive to direct consensual light stimulation. The left pupil was 3 mm and was briskly responsive to direct light stimulation, but sluggishly responsive to consensual stimulation. Convergence failed to constrict the right pupil (Fig. 1). Extraocular movements revealed a gaze paresis to the left, with a tendency to turn the head and eyes to the right. A right blepharoptosis was present. Opticokinetic nystagmus was absent on turning the test drum to the right. Slit-lamp and ophthalmoscopic examination were unremarkable. There was decreased sensation to pinprick over the right forehead and upper face. Corneal sensation was depressed in the right eye. Sweat was absent over the entire side of the face. A central facial weakness and a moderate weakness of the left arm and leg were present. Primary sensory responses were normal on the arms and legs. The 2+ deep tendon reflexes were symmetric with plantar flexor responses bilaterally. General examination revealed a blood pressure of 130/80.

Past medical history included chronic alcohol abuse. The patient had been treated for syphilis on two occasions. One year before admission, he had had an episode of left-sided weakness that cleared completely. He had never had diabetes mellitus.

Laboratory examination—White blood cell count (WBC) was 13,000 mm³ with 83% polymorphonuclear cells; hematocrit value, 41%; erythrocyte sedimentation rate, 7 mm/hr; and platelet count, 255,000 mm³. Urinalysis test showed 3+ protein, 4+ glucose, and was positive for acetone (dipstick). Blood glucose level was 400 mg/100 ml. Electrolyte test showed sodium, 132 meq/liter; potassium, 5.2 meq/liter; chlorides, 91 meq/liter; CO₂, 24 meq/liter; and blood urea nitrogen, 18 mg/100 ml. An ultrasonography test revealed a normal midline, and computerized axial tomography (EMI scan) was normal. Lumbar puncture showed an opening pressure of 150 mm H₂O, with clear cerebrospinal fluid (CSF); protein, 52 mg/100 ml; glucose, 203 mg/100 ml; simultaneous blood glucose of 375 mg/100 ml; WBC, 55 mm³ with 98% monocytes and 27 red blood cells. Blood and CSF serology, tuberculin skin tests, and cultures for fungus and tuberculosis were negative. Cryptococcal antigen was negative. Immunoelectrophoresis of the CSF revealed an IgG of 15% of the total protein. Brain scan was normal, but when repeated two weeks later was positive in the right occipital region. Angiography was not performed.

From the Eye Pathology Laboratory, Wilmer Ophthalmological Institute and Department of Pathology, Johns Hopkins Medical Institutions, Baltimore, Maryland.

Reprint requests to W. Richard Green, M.D., Eye Pathology Laboratory, Johns Hopkins Hospital, Baltimore, MD 21205.

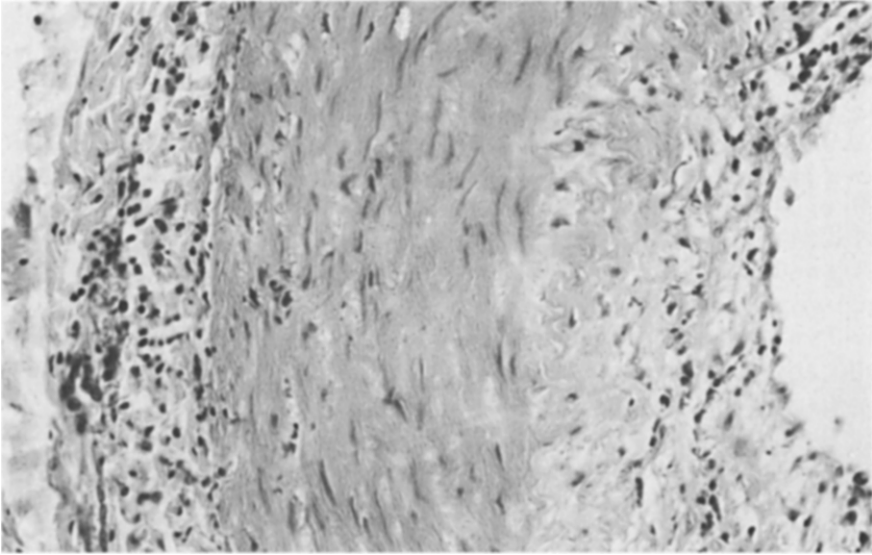


Fig. 1 (Victor and Green). Temporal artery biopsy revealing a round cell infiltrate involving all layers of the vessel wall, with preservation of the media and intima (hematoxylin and eosin, $\times 310$).

On the third hospital day, the patient had a prominent right temporal artery that was hard and easily palpated. A segment of firm temporal artery, 4 mm \times 2 mm, was obtained for biopsy. Microscopic examination revealed a small muscular artery with a moderate lymphocytic and plasmacytic infiltrate in the intima, media, and adventitia. There was only minimal evidence of intimal proliferation. The elastica was rarely interrupted (Figs. 1 and 2). Electron microscopy failed to reveal any virus-like particles in the vessel wall.

Repeat lumbar punctures over a two-month period revealed a persistent CSF lymphocytosis and elevated protein level. The patient's diabetes mellitus, apparently made evident by the infection, initially required insulin but gradually resolved. The patient's muscular weakness and mental status have improved. However, he has a dense hemianopia and a sluggish dilated right pupil.

DISCUSSION

This patient developed herpes zoster ophthalmicus after a minor head trauma. Five weeks later, he developed an altered mental status, a transient ipsilateral amaurosis, an ipsilateral Horner's syndrome and ciliary ganglionitis, and a contralateral hemiparesis and homonymous hemianopia. The Horner's syndrome with sweat involvement indicates involvement of the carotid artery proximal to its bifurcation

on the side of the involved eye. The remaining signs reflect a multifocal insult in the distribution of the carotid artery branches.

Cerebral angiography performed on

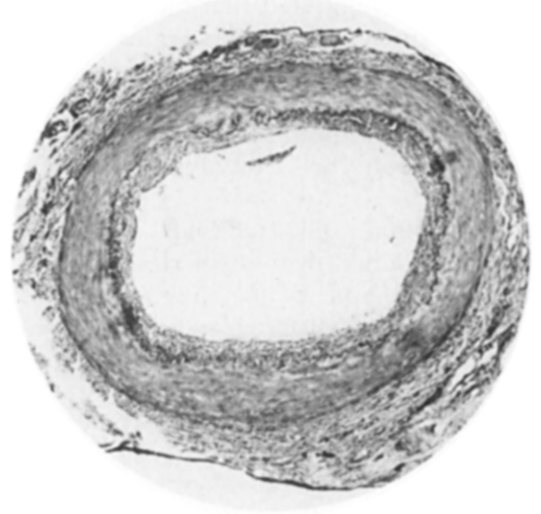


Fig. 2 (Victor and Green). Temporal artery with an intact internal elastic membrane (Verhoeff and van Gieson's, $\times 45$).

three patients with herpes zoster ophthalmicus and delayed hemiparesis revealed direct evidence of a segmental arteritis involving the carotid and its branches ipsilateral to the involved eye.^{2,3,5} One of these cases had pathologic confirmation of a granulomatous arteritis involving intracranial vessels.⁵

The temporal artery biopsy in our patient confirmed the presence of an arteritis involving a small branch of the external carotid artery, ipsilateral to the involved eye. Since no giant cells were seen, we cannot be sure that this arteritis is the same as granulomatous angiitis. However, this case is consistent with the character and distribution of the inflammation in granulomatous arteritis. The preservation of the arterial media and elastica in granulomatous arteritis and in our patient's vasculitis distinguishes them pathologically from giant cell arteritis. Because of the normal erythrocyte sedimentation rate, and the possibility of inducing viral dissemination, the patient was not treated with corticosteroids.

Cope and Jones⁷ suggested that there is an ascending inflammation of nervous tissue with a secondary vasculitis. Schiff and Brain⁸ suggested that there is a diffuse inflammation in the region of the involved eye that spreads centrally. Biggart⁹ suggested that the local perivascular inflammation in the region of the eye spreads centrally to involve the carotid system.

Rosenblum and Hadfield⁶ suggested that there might be a direct viral involvement in the wall of the involved artery. However, electron microscopy on an intracranial vessel wall, which had been routinely imbedded for histologic examination, failed to reveal viral particles. In our case, electron microscopic study of a portion of the vessel that had been immediately fixed in glutaraldehyde failed to reveal viral particles. Since attempts to culture herpes zoster and other viruses

from CSF samples were unsuccessful, together with the delayed but acute onset of the symptoms, this vasculitis may not be a direct viral infection.

Temporal artery biopsy may be a useful way of confirming the diagnosis of central nervous system arteritis after herpes zoster ophthalmicus, and differentiating it from other similar arteritides. Moreover, the biopsy may eliminate the need and risk of cerebral angiography to make this diagnosis.

SUMMARY

A 58-year-old man developed herpes zoster ophthalmicus with delayed hemiparesis. Temporal artery biopsy confirmed the presence of a vasculitis. Electron microscopy of the temporal artery failed to reveal viral particles. Herpes zoster ophthalmicus with delayed arteritis appeared to be a contiguous spread of vasculitis to the carotid system and not a direct viral invasion.

REFERENCES

1. Acers, T. E.: Herpes zoster ophthalmicus with contralateral hemiplegia. *Arch. Ophthalmol.* 71:371, 1964.
2. Walker, R. J., Gammal, T. E., and Allen, M. B.: Cranial arteritis associated with herpes zoster. Case reports with angiographic findings. *Radiology* 107:109, 1973.
3. Gilbert, G., J.: Herpes zoster ophthalmicus and delayed contralateral hemiparesis. Relationship of the syndrome to central nervous system granulomatous angiitis. *J.A.M.A.* 229:302, 1974.
4. Cravioto, H., and Feigin, I.: Noninfectious granulomatous angiitis with a predilection for the nervous system. *Neurology* 9:599, 1959.
5. Kolodny, E. H., Reibeiz, J. J., Caviness, V. S., and Richardson, E. P.: Granulomatous angiitis of the central nervous system. *Arch. Neurol.* 19:510, 1968.
6. Rosenblum, W. I., and Hadfield, M. G.: Granulomatous angiitis of the nervous system in cases of herpes zoster and lymphosarcoma. *Neurology* 22:348, 1972.
7. Cope, S., and Jones, A. T.: Hemiplegia complicating ophthalmic herpes zoster. *Lancet* 2:898, 1954.
8. Schiff, C. I., and Brain, W. R.: Acute meningoencephalitis associated with herpes zoster. A fatal case. *Lancet* 2:70, 1930.
9. Biggart, J. H.: *Pathology of the Nervous System*. Baltimore, William Wood and Co., 1936, p. 160.