

CASE REPORT

Red ear(s) syndrome associated with child neuropsychiatric systemic lupus erythematosus

H-S Lee¹, S-C Bae^{1*}, W-S Uhm¹, J-B Jun¹, I-H Lee¹ and SY Kim¹

¹The Hospital for Rheumatic Diseases, Department of Internal Medicine, Hanyang University College of Medicine, Seoul, South Korea

This case illustrates that a child having severe neuropsychiatric systemic lupus erythematosus (NPSLE) with seizure and cerebral vascular disease showed excellent clinical outcome in response to intravenous methylprednisolone and cyclophosphamide pulse, and presented unexplained red ears phenomenon.

Lupus (2000) 9, 301–303

Keywords: systemic lupus erythematosus; neuropsychiatric systemic lupus erythematosus; seizure; cerebral vascular disease; red ear(s) syndrome

Introduction

The prevalence of neuropsychiatric systemic lupus erythematosus (NPSLE) in children has varied, occurring in 9–45% of children with SLE (systemic lupus erythematosus).^{1–3} Recently there were a few reports of the clinical manifestation, therapy, or prognosis of NPSLE in childhood.^{1–5} The effect of a combined treatment of intravenous methylprednisolone (IVMP) and intravenous cyclophosphamide (IVCy) in children with severe NPSLE was observed to be favorable.⁴

Red ear(s) syndrome was first described by Lance.⁶ He suggested that many etiologies, such as irritation of the third cervical root, temporomandibular joint dysfunction or thalamic syndrome, could be responsible for 'red ear(s) syndrome'. Hirsch also reported red ear(s) syndrome among patients with headache.⁷ To our knowledge, however, there has not been any report of red ear(s) syndrome in SLE patients.

We report a case of severe NPSLE (seizure and cerebral vascular disease) with unexplained red ear(s) syndrome.

Case report

A 9-year-old patient, Korean–Swiss, visited the Emergency Room due to partial-complex seizure with partial impairment of consciousness, which lasted for about 5 min. Three months prior to admission, he had already been diagnosed as having SLE based on typical malar rash, positive ANA, leukopenia and positive anti-dsDNA. But there had not been any history of arterial or venous thrombosis, and livedo reticularis. He had been placed on prednisolone 30 mg and hydroxychloroquine 150 mg daily. Laboratory findings at admission were as follows; 2400/mm³ of WBC, 9.6 g/dl of hemoglobin, 262 × 10³/mm³ of platelets, normocytic normochromic anemia and leukopenia without schistocytes on peripheral blood smear, normal urinalysis, 218 mg/dl of cholesterol, 95 mg/dl of glucose, 24/28 units of ALT/AST, 280 units of LDH, 0.7 mg/dl of creatinine, normal electrolytes, 0.40 mg/dl of C-reactive protein, 58 mm/h of ESR, 16.6/4.02 mg/dl of C3 and C4, positive ANA test (speckled type of 1:320 and cytoplasmic type of 1:160), negative anti-dsDNA (using *Crithidia lucillae*), positive anti-Ro antibody, negative antiribosomal P protein, non-reactive VDRL, negative anticardiolipin antibody and lupus anticoagulant, weakly positive direct Coombs' test. MRI showed the infarction of left basal ganglia and prominent vasculitis of left middle cerebral artery (Figure 1(a)).

*Correspondence: S-C Bae, The Hospital for Rheumatic Diseases, Hanyang University Medical Center, Seoul 133-792, South Korea.
Tel: (+82) 2 2290 9203 or 9246; Fax: (+82) 2 2298 8231;
E-mail: scbae@email.hanyang.ac.kr
Received 1 September 1999; accepted in revised form 23 November 1999

On the second day, another attack of seizure, altered mentality, and right hemiplegia developed. According to ACR nomenclature and case definitions for NPSLE,⁸ he had seizure disorders and stroke syndrome as manifestations of NPSLE. After intravenous bolus injection of diazepam, we tried intravenous methylprednisolone 500 mg pulse (IVMP) and intravenous phenytoin loading. Fifteen minutes after IVMP, right hemiplegia recovered completely and his mentality was cleared. Two additional IVMP daily in succession and intravenous cyclophosphamide 400 mg pulse (IVCy) were done. He started on oral prednisolone 40 mg, oral phenytoin and hydroxychloroquine 200 mg daily.

Brain perfusion SPECT (single photon emission computed tomography) was done, which showed decreased perfusion of left basal ganglia (right/left perfusion ratio of basal ganglia was 1.32). EEG did not show any abnormal findings.

On the 30th hospital day, the second cycle of IVMP 500 mg and IVCy 500 mg was given. On the 37th hospital day, follow-up brain MRI showed that the infarcted area at the left basal ganglia got much smaller but still remained, and previous vasculitis of left MCA artery territory disappeared completely (Figure 1(b)).

Follow-up laboratory findings were as follows; 5600/mm³ of WBC, 11.4 g/dl of hemoglobin, 311 × 10³/mm³ of platelet. His complements were becoming stabilized from 16.6/4.02 mg/dl to 80.9/12.3 mg/dl of C3/C4.

Despite stable and good clinical condition, he had suffered episodes of reddish swelling of the helices of the ears, accompanied by a mild burning sensation of auricle, mild headache, local heat, tinnitus, and pain of mastoid area (Figure 2). This usually occurred bilaterally, once or twice each day, lasted for about one hour, and was more common in the evening. There were no precipitating factors such as fever,

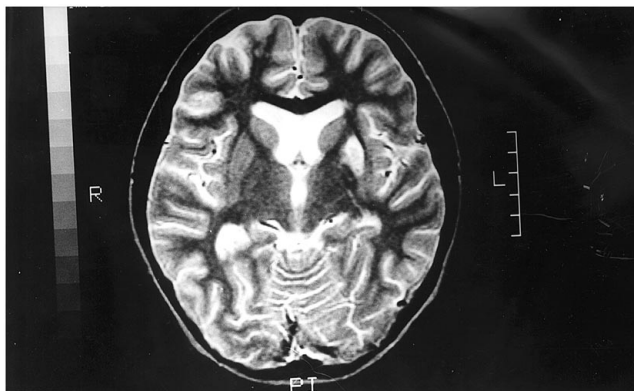
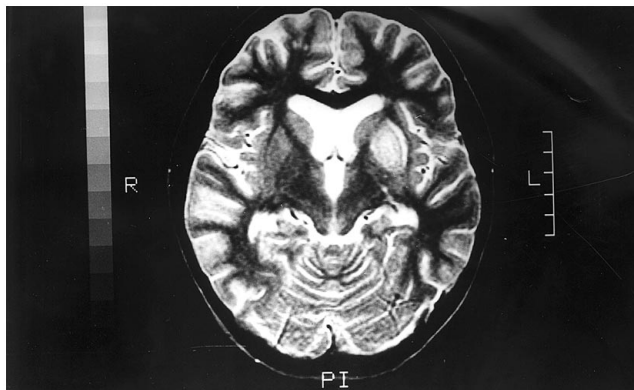


Figure 1(a) T2 weighted MRI of brain showed diffuse brain atrophy, high signal intensity of left basal ganglia, multifocal high signal spots of subcortical white matter and prominent vascularity of left middle cerebral artery. (b) Follow-up T2 weighted MRI showed that the volume of high signal intensity of left basal ganglia got much smaller without enhancement but a small infarction area at the left putamen still remained. Previous vasculitic lesion of left MCA artery territory disappeared completely but multifocal high signal spots were persistent.

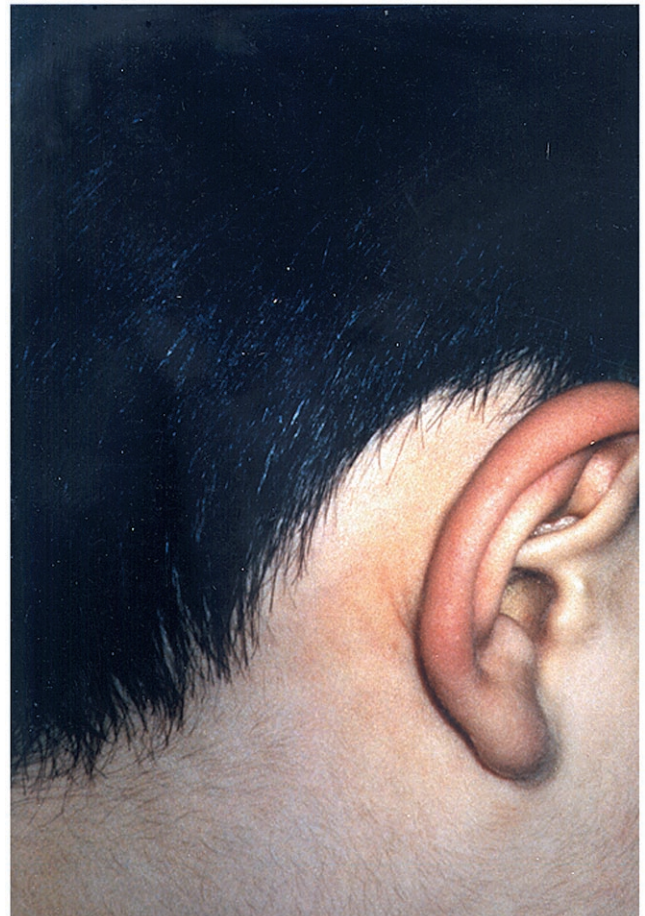

Figure 2 Right ear helix showed redness accompanied with mild burning and local heat.

touching, chewing, grinding, or neck pain. Radiographs of the mastoid bone and paranasal sinuses, audiometry, and tinnitogram showed normal findings.

Discussion

In our case, right hemiplegia with loss of consciousness developed immediately after partial seizure episode, but these neurologic deficits recovered completely in 15 min after IVMP. As reported,^{1–5} early vigorous therapy with combined IVMP and IVCy seemed to be an effective therapy for children with severe NPSLE.

Interestingly, this patient showed unexplained redness of ears. ‘Red ear(s) syndrome’ consisted of many etiologies.^{6,7} Lance suggested that this syndrome would be associated with irritation of the third cervical root, temporomandibular joint dysfunction, thalamic syndrome, or without obvious structural cause.⁶ Among these causes, red ears in conjunction with thalamic syndrome would result from disinhibition of the quinterothalamic neuron to produce continuous burning pain in the face, including pain in the ears.⁶ Hirsch reported the presence of red ear(s) syndrome in patients with headache, which may be caused by an underlying dysregulation of sympathetic outflow.⁷ O’Gradaigh *et al* reported swollen tender indurated red ears and adjacent skin in antiphospholipid syndrome, which resulted from bilateral thrombosis of ears.⁹

The etiology of red ears in our patient is obscure. He did not have any apparent predisposing factor or etiology as described above.^{6,7,9} However, even though it could not be a complete explanation, thalamic lesion would be the most probable cause of

red ear(s) syndrome in this patient because our patient showed the vasculitis of left middle cerebral artery and infarction in left basal ganglia, which might involve the thalamus.

There has not been any report of red ear(s) syndrome in SLE or NPSLE patients. Therefore further observation of the red ear(s) phenomenon in SLE is needed to clarify the association between them and the possible pathogenesis.

We suggest that early aggressive therapy with combined IVMP and IVCy in a child with severe NPSLE is an effective therapy, and red ear(s) syndrome would be a part of the unusual manifestation of NPSLE.

References

- 1 Yancey CL, Doughty RA, Athreya BH. Central nervous system involvement in childhood systemic lupus erythematosus. *Arthritis Rheum* 1981; **24**: 1389–1395.
- 2 Steinlin MI, Blaser SI, Gilday DL *et al*. Neurologic manifestations of pediatric systemic lupus erythematosus. *Pediatr Neurol* 1995; **13**: 191–197.
- 3 Parikh S, Swaiman KF, Kim Y. Neurologic characteristics of childhood lupus erythematosus. *Pediatr Neurol* 1995; **13**: 198–201.
- 4 Baca V, Lavallo C, Garcia R, Catalan T. Favorable response to intravenous methylprednisolone and cyclophosphamide in children with severe neuropsychiatric lupus. *J Rheumatol* 1999; **26**(2): 432–439.
- 5 Bell CL, Partington C, Robbins M *et al*. Magnetic resonance imaging of central nervous system lesions in patients with lupus erythematosus. *Arthritis Rheum* 1991; **34**(4): 432–441.
- 6 Lance JW. The red ear syndrome. *Neurology* 1996; **47**: 617–620.
- 7 Hirsch AR. Red ear syndrome. *Neurology* 1997; **49**: 1190.
- 8 Ad Hoc Committee on Neuropsychiatric Lupus Nomenclature. The ACR nomenclature and case definitions for neuropsychiatric lupus syndromes. *Arthritis Rheum* 1999; **42**(4): 599–608.
- 9 O’Gradaigh D, Scott DGI, Levell N. Hug(h)e(s’) ears: an unusual presentation of antiphospholipid syndrome. *Ann Rheum Dis* 1999; **58**(1): 65–66.