



## CASE STUDY

# An unusual complication of tapping a ventriculoperitoneal shunt

NICHOLAS F MAARTENS, PAUL AURORA,<sup>a</sup> PETER G RICHARDS

Department of Paediatric Neurosurgery, Radcliffe Infirmary, Oxford; <sup>a</sup>Department of Paediatrics, Hospital for Sick Children, Great Ormond Street, London, UK

A case is reported describing a complication of an unsuccessful attempt to aspirate the reservoir of a ventriculoperitoneal shunt system with a suspected shunt infection. This arose due to a misunderstanding of the anatomy of the shunt and resulted in an intracerebral haematoma. The complications of cerebrospinal fluid shunting and the difficulty in the diagnosis thereof are outlined. We discuss the role and method of shunt tapping in diagnosing shunt problems before reviewing the literature describing the rationale. The variation in shunt design is emphasized. Guidelines are then proposed not to dissuade physicians from tapping shunts but to ensure that the procedure is performed safely and in collaboration with neurosurgical units.

*Keywords:* Complication. Haemorrhage. Shunt. Tapping.

## Introduction

Hydrocephalus is the most frequent condition seen in paediatric neurosurgical practice. It is only during the last 40 years that an effective treatment has been devised, with a complication rate approaching an acceptable level.<sup>1</sup> This important advance has been the development of unidirectional, pressure-regulated shunt systems. These are, however, still prone to blockage and infection<sup>2</sup> resulting in up to 48% of all shunt operations being revisions.<sup>3</sup> Both early detection and subsequent treatment of these complications is critical to avoid neurological sequelae. This is not always easy since the symptoms and signs of raised intracranial pressure and meningitis can overlap with many common medical conditions – particularly in children. Being able to exclude a shunt-related problem can understandably become a cause of considerable anxiety, especially to those unfamiliar with neurological disease. As a result neurosurgical units are frequently called upon to exclude shunt-related problems, often inappropriately. Although there are various special investigations to assess shunt functioning, none are consistently

diagnostic. Both Piatt and Aschoff have shown that digital compression of the shunt reservoir is unreliable in this assessment and potentially damaging to the valve mechanism.<sup>4</sup> It is thus often necessary to access the shunt directly, both to obtain a sample of cerebrospinal fluid (CSF) to screen for infection and to ascertain whether the shunt is functioning. Many but not all modern shunt systems incorporate silastic reservoirs allowing subcutaneous access to the shunt. In an emergency, aspirating CSF from the reservoir may be both diagnostic and lifesaving.<sup>2,5-7</sup> We present a case in which a complication occurred following an incorrectly attempted shunt aspiration procedure. We then review the literature experience of diagnostic shunt tapping and propose guidelines for non-neurosurgical units to follow.

## Case study

The patient, an 18-month-old male, had as a neonate been diagnosed as having hydrocephalus secondary to aqueduct stenosis after presenting with progressive craniomegaly. A ventriculoperitoneal

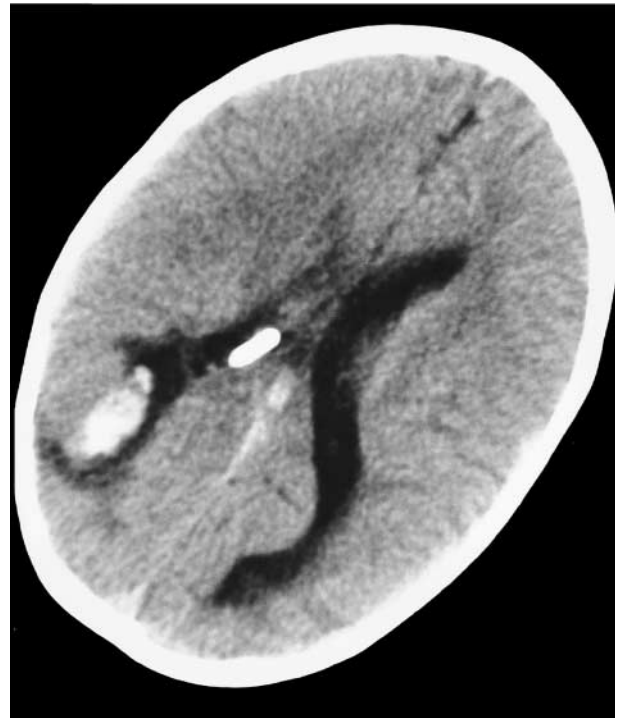Received 10.10.99. Revised 7.1.2000. Accepted 10.2.2000.

Correspondence: Nicholas F Maartens, Department of Neurological Surgery, Radcliffe Infirmary, Oxford OX2 6HE, UK  
e-mail: dmaartens@doctors.org.uk

shunt was implanted at 6 weeks of age and he subsequently experienced no complications, developing normally. He presented to his local emergency department in January 1996 following a generalized tonic-clonic convulsion of 1-minute duration. This had been preceded by a short febrile illness.

On examination he was easily rousable with no meningism and with clinical evidence of an upper respiratory tract infection. A full blood count revealed a leucocytosis and his infection markers were raised. His illness was thought to be viral in origin but due to the presence of the ventriculoperitoneal shunt he was admitted for investigation and observation. A computed tomography (CT) scan was not performed as there were no clinical features to suggest that the shunt was malfunctioning. He remained unwell and 48 hours later, after liaising with the regional neurosurgical service, it was decided to obtain a sample of CSF from the shunt to exclude meningitis. The on-call paediatric registrar attempted percutaneously to access the shunt reservoir with a 23G butterfly needle but after two failed attempts the procedure was abandoned. Before a lumbar puncture could be arranged, a blood culture taken on admission grew *Streptococcus pneumoniae* sensitive to penicillin – presumed to have originated from his chest. The child was commenced on intravenous benzylpenicillin and over the next 24 hours his condition improved spontaneously.

He then became drowsy and lethargic and shortly afterwards had a witnessed left-sided focal convulsion lasting 5 minutes. He was therefore transferred to the regional neurosurgical unit with suspected shunt malfunction or infection. Examination did not reveal any cause for his deterioration but the attending neurosurgeon noted that the shunt system did not have a reservoir. A cranial CT scan was then performed which demonstrated normal sized ventricles and an intraparenchymal haemorrhage beneath the burrhole, alongside the ventricular catheter (Fig. 1). It was concluded that in attempting to access the shunt, the right angled connector, situated over the burrhole, had been mistaken for the reservoir of a shunt system (Fig. 2). This right-angled connector was dome shaped and on palpation could easily have been mistaken for a burrhole type shunt valve. This had resulted in the haemorrhage which later, presumably due to the surrounding swelling visible on the scan or an unwitnessed or subclinical seizure, precipitated his depressed level of consciousness and the second observed seizure. The patient was managed conservatively and discharged after 4 days observation having

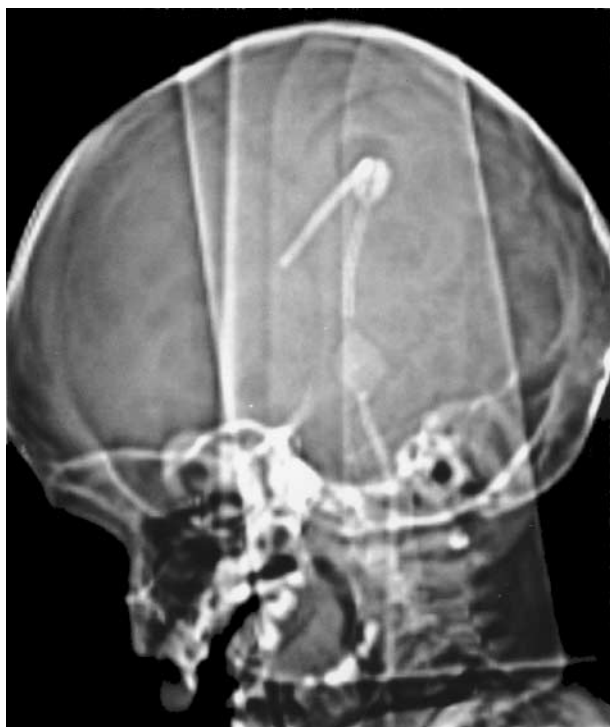

**Fig. 1.** An axial CT scan of the patient's brain illustrates the ventricular catheter of the shunt projecting into an effaced right lateral ventricle. Related to the entry point of the catheter is a hyperdense white lesion indicating a recent intracerebral haematoma with surrounding low density oedema.

completed his course antibiotics. He made a complete recovery with no further seizures.

## Discussion

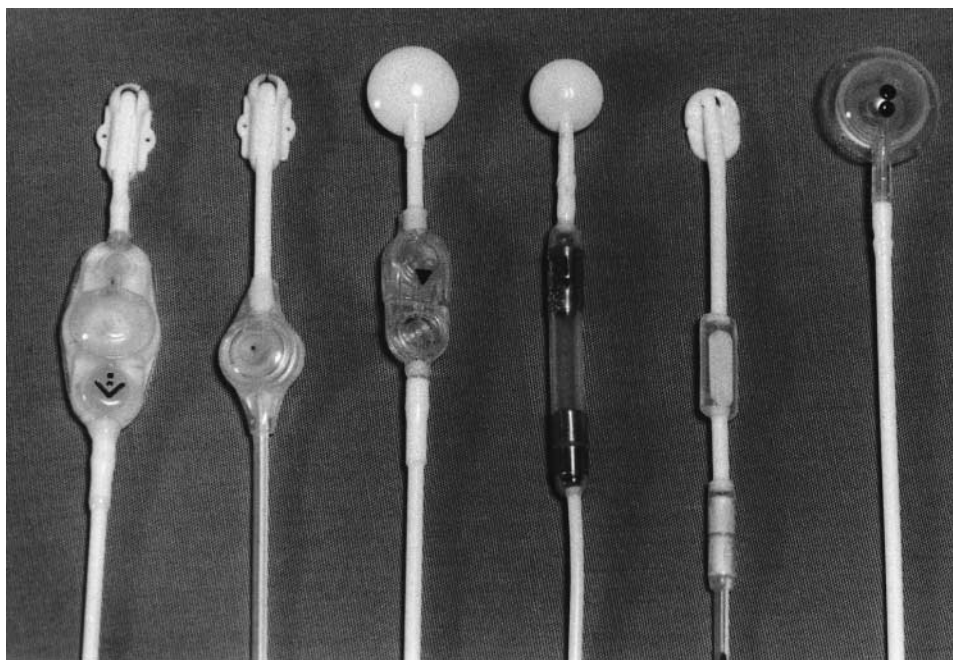
The number of shunts commercially available has proliferated in the last 30 years. Although the basic components remain the same, the design, layout and individual features may vary markedly (Fig. 3). All shunts consist of a proximal catheter which accesses the ventricular CSF, a valve and a distal catheter which normally drains into the abdomen or the central venous system. All catheters are made of silicon rubber, as this has the best combination of biocompatibility and flexibility, but their design and that of their introducers varies. The valves also differ in their design and pressure-flow characteristics. Many, but not all valve systems, incorporate silastic dome reservoirs. These reservoirs are sited subcutaneously and are usually located away from the entry point of the proximal catheter into the skull, although in a few designs the reservoir is located directly over the



**Fig. 2.** The lateral CT survey view of the patient's head demonstrates how easy it can be to mistake the right angled connector of the shunt, illustrated in Fig. 3, for the shunt alongside to the right, with a reservoir situated over the burrhole.

burrhole. They can be accessed by passing a 23G or 25G butterfly needle through the overlying skin and through the silastic dome, so that the bevel of the needle lies within the reservoir. Free flow of CSF indicates patency of the ventricular catheter. The tubing can then be connected to a manometer in order to measure the pressure within the ventricular system. If the reservoir is situated caudal to the valve, elevating the manometer above the shunt valve opening pressure should result in flow of CSF from the manometer back into the shunt system, indicating patency of the distal catheter. Abnormal findings in shunt fluid dynamics, with and without infusion studies can thus help in identifying the site of obstruction to which neurosurgical attention can then be directed at the time of revision.<sup>5,8</sup> An alternate method of assessing CSF dynamics and patency of the shunt system is to inject a contrast medium into the antechamber of the shunt system; X-rays of the skull, chest and abdomen taken 10 minutes after administration will demonstrate if the catheters are patent and if there is free CSF flow from the ventricles towards the peritoneal cavity. Meticulous aseptic technique is essential when performing these procedures and prophylactic antibiotics are sometimes administered.<sup>9</sup>

The most common complications affecting shunt systems are obstruction<sup>10</sup> and infection,<sup>11,12</sup> the



**Fig. 3.** The illustration demonstrates the diverse layout and design of different shunt systems, particularly with regard to the position of the reservoir. The shunt system used in this patient is shown second from left and has no access reservoir.

latter usually occurring within 6 months of implantation. Mechanical complications related to shunt valves, reservoirs, tubing and disconnection, are less common but well described.<sup>13</sup> Subdural haemorrhages are a significant problem in patients with large ventricles, atrophic brains or when the ventricular system is decompressed too quickly.<sup>14</sup> The experience of the neurosurgeon is a critical factor when considering all of these complications.<sup>15</sup>

As all CSF shunt systems are prone to blockage and infection, the early detection and treatment thereof is a cornerstone of the work of neurosurgical units. Although clinical examination, blood investigation and radiological imaging may yield important clues, diagnosis of mechanical failure or infection may frequently be equivocal.<sup>5</sup> Tapping the shunt system directly has a high diagnostic yield with few false positive or false negative results. It is a convenient, quick, safe and easy way of assessing shunt function and furthermore, has a higher yield than lumbar or ventricular puncture.<sup>15</sup> It also avoids implanting revised shunts into occultly infected CSF. Using shunt aspiration, Myers and Schoenbaum<sup>9</sup> obtained bacterial isolates from 42 of 59 cultures from infected shunts. The aetiological agent was identified in 96% of those patients not receiving antibiotics and 53% of those receiving antibiotics.<sup>1,6,12</sup>

A study by Noetzel and Baker<sup>16</sup> looked at the use of shunt fluid examination in the diagnosis of shunt complications. A total of 209 diagnostic aspirations were performed on 184 patients. The opening pressure was measured in each case and the fluid sent for Gram stain, protein and glucose analysis and culture. Abnormal fluid dynamics were observed in 97% of the cases with mechanical obstruction later confirmed at surgery. Normal fluid dynamics without evidence of infection had a 98% correlation with normal shunt function subsequently confirmed by the clinical course. In six cases it was possible to clear a distal obstruction by flushing the valve and distal catheter. No short-term or long-term complications of these procedures were recorded. The authors concluded that shunt fluid examination was a useful and safe procedure which could be performed in an emergency setting by properly trained physicians.<sup>7</sup>

Watkins *et al.*, in another study<sup>2</sup> looked prospectively at all patients referred to their unit with a provisional diagnosis of shunt blockage. Of 52 referrals only 19 led to the final diagnosis of shunt malfunction. They found that CT scanning, particularly in patients with large dysmorphic ventricles, did not reliably exclude the diagnosis of shunt blockage whereas percutaneous manometry (performed in 26 patients) was diagnostic in 21. The

five patients with equivocal findings were all found subsequently to have definite shunt blockage at surgery.

Needless to say, shunt tapping is potentially problematic. Recognized complications include bleeding or CSF leakage from the puncture site, introduction of infection, disruption of the valve mechanism or obstruction of the system with clots.

No one shunt type has been shown to be superior and most neurosurgical units use two or three types. Physicians usually become familiar with the shunts used by their regional neurosurgical units. Difficulties may occur when new shunt types are introduced, doctors rotate and when patients shunted in distant units, or many years ago, present with complications. If the physician is not certain about the type of shunt and location of the reservoir (if present), a skull X-ray should be performed. This will confirm its position and indicates whether the reservoir lies over the burrhole. Relying on palpation alone is inadequate and potentially misleading unless the physician is familiar with what specific shunt system was used. In any event, when considering tapping a shunt, this should first be discussed with the regional neurosurgery unit. In certain clinical settings it may be safer and more appropriate to obtain CSF via a lumbar puncture especially if this can be confirmed on CT image transfer systems. It is furthermore crucial that when patients are discharged after having shunts implanted that the shunt type and its pressure characteristics are clearly documented in the patients' notes, both at the neurosurgical centre and in the transfer/discharge letters to the local referring hospital.

## Conclusion

In this case report we have described an unusual but potentially serious complication of an unsuccessful attempt to aspirate a ventriculoperitoneal shunt. Our intention is not to dissuade physicians from tapping shunts, but rather to reinforce guidelines to ensure that the procedure is performed safely, namely:

- the procedure should first be discussed with a neurosurgeon;
- the design of the shunt and the location of the reservoir must be understood by the physician and if necessary confirmed radiologically;
- meticulous aseptic and atraumatic technique must be observed;

- if the physician is uncertain about the procedure it is better to transfer the patient to a centre where specialist care is available.

## References

- 1 Peacock WJ. Prevention and management of cerebrospinal fluid shunt complications. In: Villiers JC (ed) *Some Pitfalls and Problems in Neurosurgery*. Prog Neurol Surg. Basel: Karger, 1990, Vol. 13, pp. 114–130.
- 2 Watkins L, Hayward R, Andar U, Harkness W. The diagnosis of blocked cerebrospinal fluid shunts: a prospective study of referral to a paediatric neurosurgical unit. *Childs Nervous System* 1994; **10**: 87–90.
- 3 Richards HK, O’Kane C, Seeley H *et al.* United Kingdom Shunt Registry Progress Report (1 May 1995–30 April 1998).
- 4 Piatt JH Jr. Pumping the shunt revisited: A longitudinal study. *Pediatr Neurosurg* 1996; **25**: 73–77.
- 5 Martinez-Lage JF, Poza M, Estaban JA. Mechanical complications of the reservoirs and flushing devices in ventricular shunt systems. *Br J Neurosurg* 1992; **6**: 321–325.
- 6 Griebel R, Khan M, Tan L. CSF shunt complications: an analysis of contributory factors. *Childs Nerv Syst* 1985; **3**: 242–244.
- 7 Simon HK, Steele DW, Lewander WJ, Linakis JG. Are pediatric emergency medicine training programs meeting their goals and objectives? A self-assessment of individuals completing fellowship training in 1993. *Pediatr Emerg Care* 1994; **10**: 208–212.
- 8 Czosnyka M, Whitehouse H, Smielewski P, Simac S, Pickard JD. Testing of cerebrospinal compensatory reserve in shunted and non-shunted patients: a guide to interpretation based on an observational study. *J Neurol Neurosurg Psychiatr* 1996; **60**: 549–558.
- 9 Myers MG, Schoenbaum SC. Shunt fluid aspiration: an adjunct in the diagnosis of cerebrospinal fluid shunt infection. *Am J Dis Child* 1975; **129**: 220–222.
- 10 Sood S, Kim S, Ham SD, Canady AL, Greninger N. Useful components of the shunt tap test for evaluation of shunt malfunction. *Childs Nerv Syst* 1993; **9**: 157–161.
- 11 Drake JM, Sainte-Rose C. *The Shunt Book*. Oxford: Blackwell Science, 1995.
- 12 Depuyt F, Vervloesem R, Wilms G. Bilateral subdural haematoma secondary to surgery. *J Belg Radiol* 1993; **76**: 31.
- 13 Duong D, Nowzari F, Chadduck WM, Schiff SJ. Time related patterns of ventricular shunt failure. *Childs Nerv System* 1994; **10**: 524–528.
- 14 Choux M, Genitori L, Lang D, Lena G. Shunt implantation: reducing the incidence of shunt infection. *J Neurosurg* 1992; **77**: 875–880.
- 15 Schoenbaum SC, Gardner P, Shillito J. Infections of cerebrospinal fluid shunts: epidemiology, clinical manifestations and therapy. *J Infect Dis* 1975; **131**: 543–552.
- 16 Noetzel MJ, Baker RP. Shunt fluid examination: risks and benefits in the evaluation of shunt malfunction and infection. *J Neurosurg* 1984; **61**: 328–332.