

## Sudden hemiplegia after a motorcycle accident

A M-H Ho, J D Wells

Answers on p 442.

A 21 year old previously healthy man lost control of his motorcycle and tumbled down to the bottom of an embankment. He suffered a brief loss of consciousness, got up, and, with pain in his left arm, pushed the motorcycle up the embankment back onto the side of the road. At that point, he developed a sudden onset of dysphasia and dense right hemiplegia.

At the hospital, he was found to have normal vital signs, a closed fracture of the left humerus, right hemiplegia with no other neurological deficit, and normal computed tomography of the head. Digital subtraction left internal carotid arteriogram was immediately carried out.

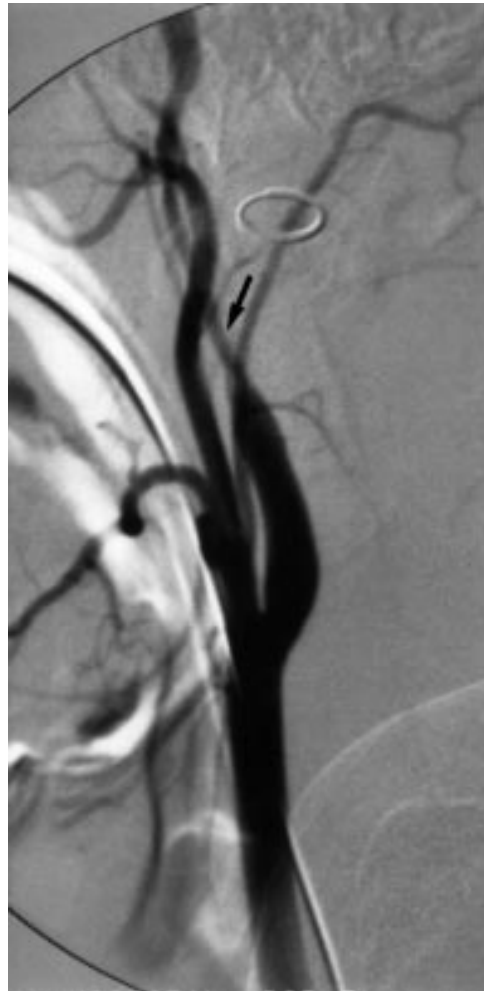

Figure 1 Lateral view of the patient's right internal carotid arteriogram using digital subtraction techniques shows a dissection.

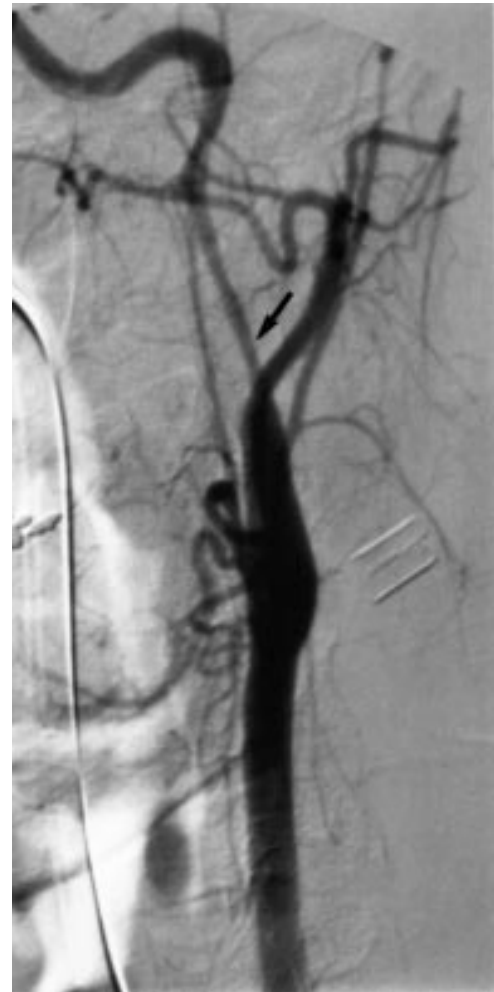

Figure 2 Oblique view of the patient's left internal carotid arteriogram shows a dissection.

Department of  
Anaesthesia and  
Intensive Care, Prince  
of Wales Hospital, The  
Chinese University of  
Hong Kong Faculty of  
Medicine, Hong Kong  
A M-H Ho

Division of  
Neurosurgery,  
Department of  
Surgery, Hamilton  
Health Sciences  
Corporation,  
McMaster University  
Faculty of Health  
Sciences, Hamilton,  
Ontario, Canada  
J D Wells

Correspondence to:  
Dr Anthony Ho, Department  
of Anaesthesia and Intensive  
Care, Prince of Wales  
Hospital, Shatin, NT, Hong  
Kong (e-mail:  
hoamh@hotmail.com)

Submitted 2 July 1999  
Accepted 13 August 1999

### Questions

- (1) What does the carotid arteriogram show (figs 1 and 2)?
- (2) What is the best way to manage this patient?
- (3) What is the differential diagnosis of acute neurological deficit after trauma?

## A young man with acute paraparesis

H M S Elasha, D Footitt, J Gibson, T J Wilkin

Answers on p 444.

A previously fit and well 32 year old man was admitted to the neurology ward in November 1998 with a 24 hour history of rapidly progressive leg weakness such that he was unable to stand. He felt tingling in his hands and lower legs, but no loss of sensation. Two weeks earlier he had noticed intermittent weakness in both legs. He reported no other neurological or constitutional symptoms. Twelve weeks earlier he had returned from a holiday in California.

His past medical history was unremarkable except for bronchial asthma controlled by salbutamol and beclomethasone inhalers. On further questioning, he admitted to unusually more colds than normal as well as mild fatigue and tiredness of six months' duration.

On examination, he was tanned with palmar crease and buccal pigmentation. His pulse was regular at 80 beats/min, blood pressure was 130/60 mm Hg (unable to stand to check postural drop), and his temperature was normal. The remaining general physical examination was normal. Higher mental function, cranial nerves, and speech were normal. His upper

limbs were stiff with a supinator catch but normal power, sensation, and coordination. The tone in his lower limbs was raised, with severe pyramidal distribution weakness. All the deep tendon reflexes were very brisk with flexor plantars. Pinprick sensation was subjectively diminished in both feet with no sensory level. Other sensory modalities were intact. Magnetic resonance imaging of the brain and spine were normal. Routine investigations revealed a normal full blood count, sodium concentration 116 mmol/l, potassium 8.9 mmol/l (confirmed on repeated sample), urea 17.2 mmol/l, creatinine 165 mmol/l, glucose 5.8 mmol/l, bicarbonate 15 mmol/l, chloride 86 mmol/l, and serum calcium was normal. Thyroid function was normal. An electrocardiogram is shown in fig 1.

### Questions

- (1) Describe the changes in the electrocardiogram
- (2) How would you explain the neurological symptoms and signs?
- (3) What is the final diagnosis and how would you confirm it?

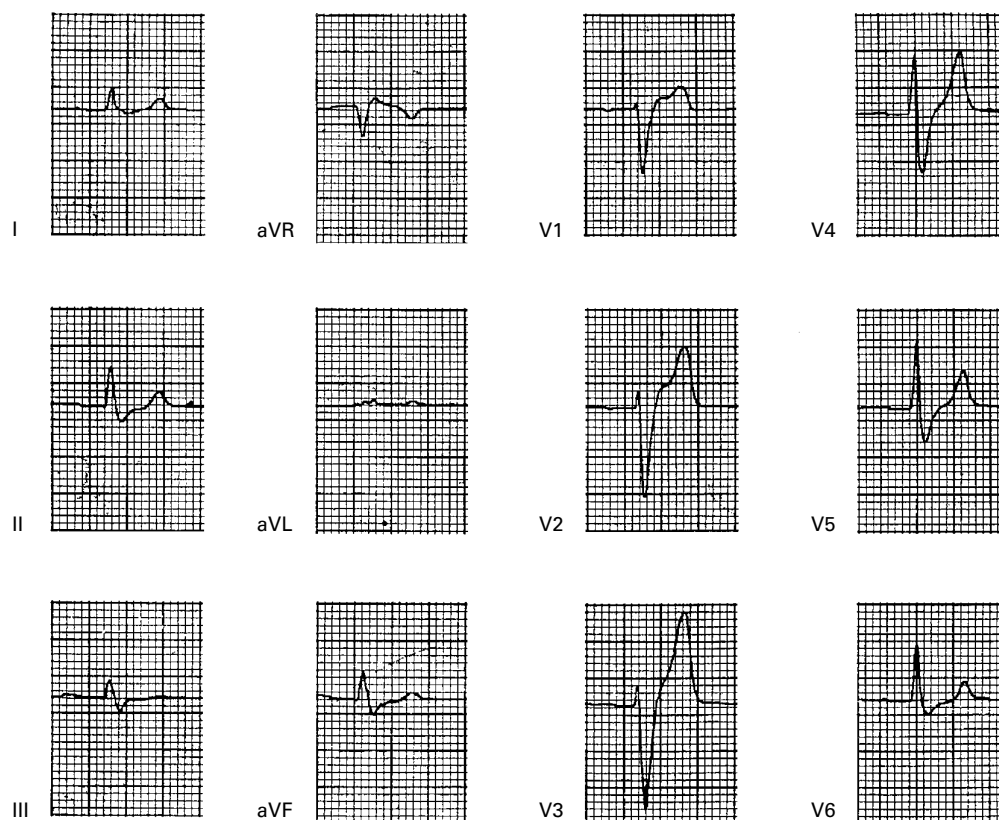


Figure 1 Electrocardiogram of patient.

**Derriford Hospital,  
Plymouth, UK:  
Department of  
Endocrinology**  
H M S Elasha  
T J Wilkin

**Department of  
Neurology**  
D Footitt  
J Gibson

Correspondence to:  
Dr H M S Elasha, Medical  
Department, West  
Cumberland Hospital,  
Hensingham, Whitehaven,  
Cumbria CA28 8JG, UK  
(e-mail:  
Hassanelasha@yahoo.com)

Submitted 24 May 1999  
Accepted 18 August 1999