

Extradural haematoma following temporomandibular joint arthrocentesis and lavage

T. A. CARROLL¹, K. SMITH² & J. JAKUBOWSKI¹

¹Department of Neurosurgery, The Royal Hallamshire Hospital, and ²Department of Oral and Maxillofacial surgery, The Charles Clifford Dental Hospital, Sheffield, UK

Abstract

We describe a case of a 59-year-old woman who remained drowsy and developed a left hemiparesis following right temporomandibular joint (TMJ) arthrocentesis and lavage for TMJ dysfunction. CT demonstrated an extradural haematoma. This is the first reported case of an extradural haematoma following TMJ arthrocentesis.

Key words: Extradural haematoma, temporomandibular joint, TMJ arthrocentesis.

Introduction

Temporomandibular joint (TMJ) arthrocentesis is frequently performed as a therapeutic procedure for TMJ dysfunction. TMJ dysfunction is a pain syndrome characterised by pain localised to the TMJ, on loading of the TMJ or on movement of the TMJ with mechanical interferences in TMJ function such as closed lock manifested by reduced maximal incisal opening.¹ TMJ arthroscopy and arthrocentesis have recently replaced open surgical procedures in patients with TMJ dysfunction failing conservative management.¹ TMJ arthroscopy was first described in 1975, TMJ arthrocentesis in 1991.^{2,3} Relief of symptoms is observed in 70% of patients undergoing arthrocentesis and 91% of patients undergoing arthroscopic lysis and lavage.⁴ The mechanism by which these minimally invasive procedures work is unclear, but it is postulated that fine intra-articular adhesions are broken down and intra-articular concentrations of inflammatory mediators may be reduced. The complication rate following TMJ arthroscopy is given as between 1.8 and 4.4%.^{2,5} Two intracranial complications resulting from TMJ arthroscopy have been described. One case involved transarticular perforation of the glenoid fossa and overlying dura with an 18FG spinal needle resulting in CSF leakage.⁶ A second case was of a chronic extradural haematoma diagnosed at 17 days post-TMJ arthroscopy.⁷ The complication rate for TMJ arthrocentesis has not yet been defined, but is considered to be less than that for TMJ arthroscopy. We describe the first reported case, to our knowledge, of a patient developing an extradural haematoma following arthrocentesis of the TMJ.

Case report

A 59-year-old woman was initially referred with right-sided facial pain made worse by eating. Clinically, she was noted to have right masseter tenderness, a palpable right TMJ click, and also to protrude and deviate the mandible to the left when talking. A diagnosis of TMJ dysfunction was made and she was subsequently electively admitted as a day patient for right TMJ injection. The joint cavity was irrigated with 60–80 ml of Ringer's lactate under general anaesthesia by an experienced surgeon using a lateral approach. No haemorrhage was noted from the joint. Postoperatively, because of drowsiness, she was kept overnight. She remained drowsy the following morning and had also developed a left hemiparesis and right third nerve palsy. CT of the head showed a right-sided extradural haematoma (Fig. 1). She underwent craniotomy and evacuation of the clot. The extradural haematoma was in part with a hemispheric component above and a subtemporal component below, separated by a thin margin of dura adherent to the inner surface of the skull, which had about half way along its length a bleeding point from one of the main divisions of the middle meningeal artery. There was no perforation of the dura, no obvious injury to the bony floor of the middle cranial fossa or other site of bleeding, e.g. from the foramen spinosum. Two weeks postsurgery, her third nerve palsy and left-sided weakness had resolved. Three months following the arthrocentesis, the patient reported that her TMJ had remained pain free.

Discussion

TMJ arthrocentesis with lavage has become established in the treatment of TMJ dysfunction and

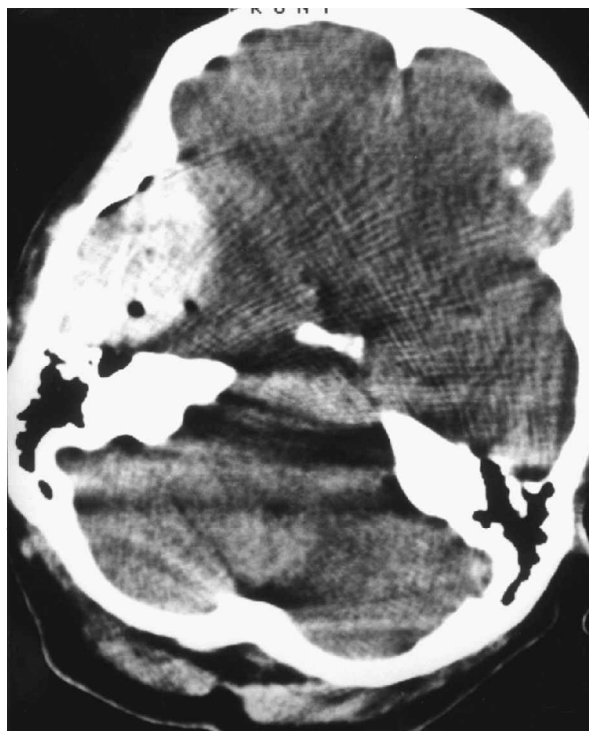


FIG. 1. CT showing the patient's left-sided extradural haematoma.

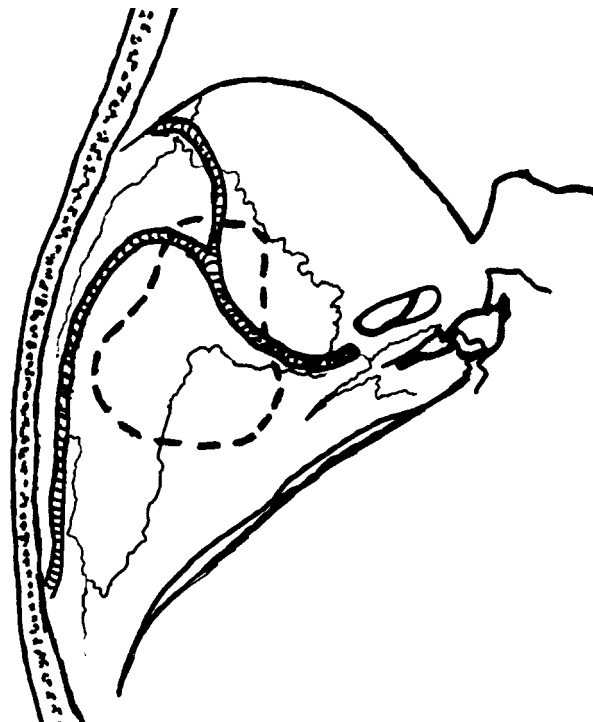


FIG. 2. Left temporal fossa showing the position of the temporomandibular joint (dashed line) relative to the intracranial portion of the middle meningeal artery.

is usually performed in an outpatient setting or as a day case procedure. Possible complications are considered to be minimal.

Complications described following puncture of the TMJ reflect the anatomy of the joint and its relations. The TMJ lies immediately anterior to the lateral part of the external acoustic meatus, and in particular just anterior and medial to the tragus, and adjacent to the tragohelicine fissure. The roof of the TMJ, consisting of the glenoid fossa behind and the temporomandibular eminence in front, forms part of the floor of the temporal fossa (Fig. 2). The articular surface of the articular eminence and glenoid fossa is separated from the articular surface of the condylar head of the mandible by the articular meniscus dividing the joint into superior and inferior compartments. The articular meniscus is attached about its circumference to the fibrous capsule and anteriorly, where the capsule is deficient, to the tendon of the lateral pterygoid. The superior attachment of the fibrous capsule is anteriorly the articular eminence, posteriorly the squamotympanic fissure and between the margins of the mandibular fossa. Below, it is attached to the upper one-third of the neck of the mandibular condyle. Superficial relationships include the superficial temporal vessels, and the temporal and zygomatic branches of the facial nerve. Deep relationships include the auriculotemporal nerve, the middle meningeal and accessory middle meningeal arteries, both branches of the adjacent maxillary artery, passing up to the foramen spinosum and foramen ovale, respectively, and emissary veins draining into the pterygoid venous plexus through the foramen spinosum, foramen of Vesalius and foramen lacerum.

TMJ arthrocentesis as first described involved percutaneous puncture of the superior compartment only.³ This is done percutaneously using a lateral approach.² Skin puncture is done along the canthus-tragus line with the most posterior puncture being no less than 10 mm anterior to the midportion of the tragus to avoid superficial temporal vessel and facial nerve injury. The joint is punctured at an approximate depth of 25 mm. The medial wall of the capsule is reached at a depth of 50 ± 5 mm.⁸ Puncture of the inferior compartment may be additionally performed using a posterior approach via the external acoustic meatus in the region of the tragohelicine incisure.⁹

The occurrence of complications following TMJ arthrocentesis has not been described, presumably because of the relative newness of the procedure in clinical practice. Extracranial complications following TMJ arthroscopy are well defined and include preauricular haematoma, superficial temporal artery aneurysm, arteriovenous fistulae, frontalis weakness, facial hypoaesthesia, middle ear injury, intra-articular instrument breakage and parapharyngeal swelling.^{2,5,8,10}

A chronic extradural haematoma detected 17 days post-TMJ arthroscopy has been previously described.⁷ We describe an acute extradural haematoma post-TMJ arthrocentesis. In both cases, the precise mechanism underlying the development of the extradural haematoma was unclear. Transarticular puncture of the thin temporal fossa floor has been described.⁶ This could either have caused direct dural vessel injury or resulted in irrigating fluid being injected into extradural space causing separation of dura from skull and

thus leading to a dural vessel tear. Alternatively, high pressure irrigation of the TMJ cavity might have caused some fluid to pass through fine channels in the bone again to enter the extradural space, strip dura from bone and lead to dural vessel injury. In our patient, considering the operative findings, and the absence of any subcutaneous or parapharyngeal swelling, an extracranial vascular injury involving, e.g. the middle meningeal artery as it enters the foramen spinosum or the pterygoid venous plexus, is unlikely to have occurred.

In summary, we describe the first reported case, to our knowledge, of a patient developing an extradural haematoma following injection of the TMJ. Although the majority of TMJ injections are uncomplicated, we suggest that if a patient is unwell with headaches or remains drowsy following the procedure, the possibility of an extradural haematoma should be considered.

References

- 1 Dolwick MF, Dimitroulis G. Is there a role for temporomandibular joint surgery? *Br J Oral Maxillofac Surg* 1994;32:307-13.
- 2 Carls FR, Engelke W, Locher MC, Sailer HF. Complications following arthroscopy of the temporomandibular joint: analysis covering a 10-year period (451 arthroscopies). *J Cranio-Maxillofac Surg* 1996;24:12-15.
- 3 Nizan DW, Dolwick MF, Martinez GA. Temporomandibular joint arthrocentesis: a simplified treatment for severe, limited mouth opening. *J Oral Maxillofac Surg* 1991;49:1163-67.
- 4 Murakami K, Hosaka H, Moriya Y, Segami N, Iizuka T. Short-term treatment outcome study for the management of temporomandibular joint closed lock. *Oral Surg Oral Med Oral Pathol Oral Radiol Endod* 1995;80:253-7.
- 5 McCain JP, Sanders B, Koslin MG, Quinn JD, Peters PB, Indresano AT. Temporomandibular joint arthroscopy: a 6-year multicenter retrospective study of 4,831 joints. *J Oral Maxillofac Surg* 1992;50:926-30.
- 6 McCain JP. Arthroscopy of the human temporomandibular joint. *J Oral Maxillofac Surg* 1988;46:648-55.
- 7 Murphy MA, Silvester KC, Chan TYK. Extradural hematoma after temporomandibular joint arthroscopy. A case report. *Int J Oral Maxillofac Surg* 1993;22:332-5.
- 8 McCain JP. Complications of TMJ arthroscopy. *J Oral Maxillofac Surg* 1988;46:256.
- 9 Zetz MR, Irby WB, Doles LR. A simplified method for injection or aspiration of the temporomandibular joint. *J Am Dent Ass* 1982;104:855-7.
- 10 McCain JP, de la Rua H. Foreign body retrieval: a complication of TMJ arthroscopy. *J Oral Maxillofac Surg* 1989;47:1221-5.

Symptomatic intraspinal air entrapment

K. UEMURA, R. BEHR & K. ROOSEN

Department of Neurosurgery, Julius-Maximilians-University, Würzburg, Germany

Abstract

A 59-year-old man who had undergone the removal of a lipoma of the thoracic spine presented with progressive weakness of the lower limbs when lumbar puncture followed drainage of a subcutaneous collection of cerebrospinal fluid. Computed tomography showed entrapped intraspinal air which compressed the spinal cord. This rare, but serious complication can occur in a patient with altered intrathecal pressure following spinal surgery.

Key words: *Computed tomography, intraspinal air, spinal cord compression, spinal surgery.*

Introduction

Air or gas in the spinal canal has been described in association with intervertebral disc,¹⁻⁷ intraspinal cyst,⁸⁻¹¹ epidural abscess,¹² metastatic tumour¹³ or trauma.¹⁴⁻¹⁷ Intraspinal air has also been reported as an incidental finding. Gordon *et al.*¹⁴ reported a patient with cervical intraspinal subarachnoid air after an open skull fracture. A similar radiological finding

was described by Mandiardi *et al.*¹⁶ as an 'intraspinal pneumocele'. Spinal cord compression was not apparent in these cases. We present a patient who developed lower limb as a result of entrapped weakness intraspinal air.

Case report

A 59-year-old man was referred with a lipoma at the level of thoracic vertebra T2-3. The patient had