
JUGULAR BULB DIVERTICULUM ASSOCIATED WITH LOWER CRANIAL NERVE PALSY AND MULTIPLE ANEURYSMS

Satoshi Kobanawa, M.D., Masamichi Atsuchi, M.D., Jun-ichi Tanaka, M.D., and Taku Shigeno, M.D., D.M.Sc.
Department of Neurosurgery, Kantou Rosai Hospital, Kawasaki, Japan

Kobanawa S, Atsuchi M, Tanaka J, Shigeno T. Jugular bulb diverticulum associated with lower cranial nerve palsy and multiple aneurysms. *Surg Neurol* 2000;53:559–62.

BACKGROUND

Jugular bulb diverticulum is a rare condition that has never been reported in association with lower cranial nerve palsy.

CASE DESCRIPTION

A 54-year-old woman developed acute swallowing disturbance and hoarseness. Neuroradiological examinations demonstrated a jugular bulb diverticulum as well as unruptured internal carotid and basilar tip aneurysms on the same side. Laboratory data for both serum and cerebrospinal fluid were normal. Steroids were given, and the cranial nerve palsy disappeared within 1 month. The aneurysms were successfully clipped. During the follow-up period of more than 1 year, the patient has done well and has no neurological deficit.

CONCLUSION

This is the first reported case of jugular bulb diverticulum associated with a lower cranial nerve palsy and multiple aneurysms. We recommend close observation of patients with this condition regardless of its clinical presentation. © 2000 by Elsevier Science Inc.

KEY WORDS

Jugular bulb diverticulum, lower cranial nerve palsy, cerebral aneurysm.

Jugular bulb diverticulum is an extremely rare condition. It is a protrusion on the jugular bulb that can lead to internal auditory dysfunction, resulting in symptoms such as hearing loss, tinnitus, and vertigo. We present the first case of a patient with a jugular bulb diverticulum who presented with a lower cranial nerve palsy.

CASE REPORT

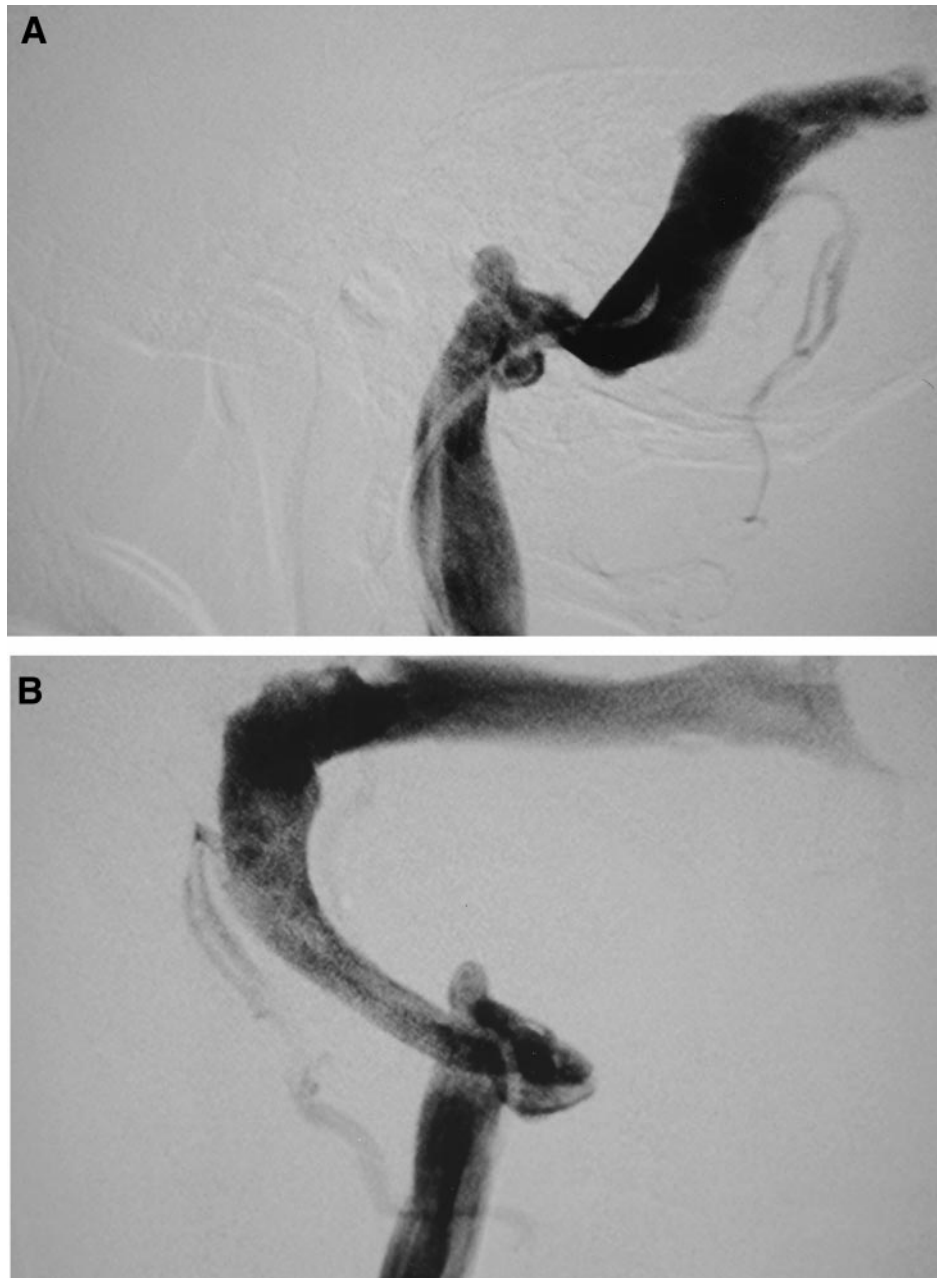
A 54-year-old woman noticed a swallowing disturbance at lunch, and her family pointed out that she had dysarthria and hoarseness. She had had a slight fever a few days before the onset of these symptoms. She presented to our hospital on the day after her symptoms appeared. Neurological examination revealed a curtain sign, vocal cord palsy, an absent gag reflex, and weakness of the sternocleidomastoid and trapezius muscles. Laboratory data for serum and cerebrospinal fluid (CSF) were all normal including the viral titer, although there was a slight elevation of CSF protein to 41 mg/dL. The jugular foramen seemed to be normal on both magnetic resonance imaging (MRI) and computed tomography (CT) scans. Cerebral angiography and retrograde jugular venography revealed a right jugular bulb diverticulum; multiple aneurysms were also noted on the right internal carotid and posterior communicating arteries and at the basilar tip.

The patient underwent steroid therapy (methylprednisolone 500 mg for 3 days) to treat the lower cranial nerve palsy. She responded well, and her signs and symptoms disappeared within several weeks, at which time the aneurysms were successfully clipped. Over a follow-up period of 18 months, the patient has done well, with no neurological deficit.

DISCUSSION

To the best of our knowledge, only nine cases of jugular bulb diverticulum have been reported in the literature [1,3,6–8,11]. The male-to-female ratio is 8:1; left-to-right side ratio is 5:3. Age at the time of diagnosis ranges from 35 to 74 years (mean 55.8

Address reprint requests to: Dr. Satoshi Kobanawa, 633-6-2 benbun honamitown, Kahodistrict, Fukuoka, Japan.
Received February 4, 2000; accepted February 29, 2000.



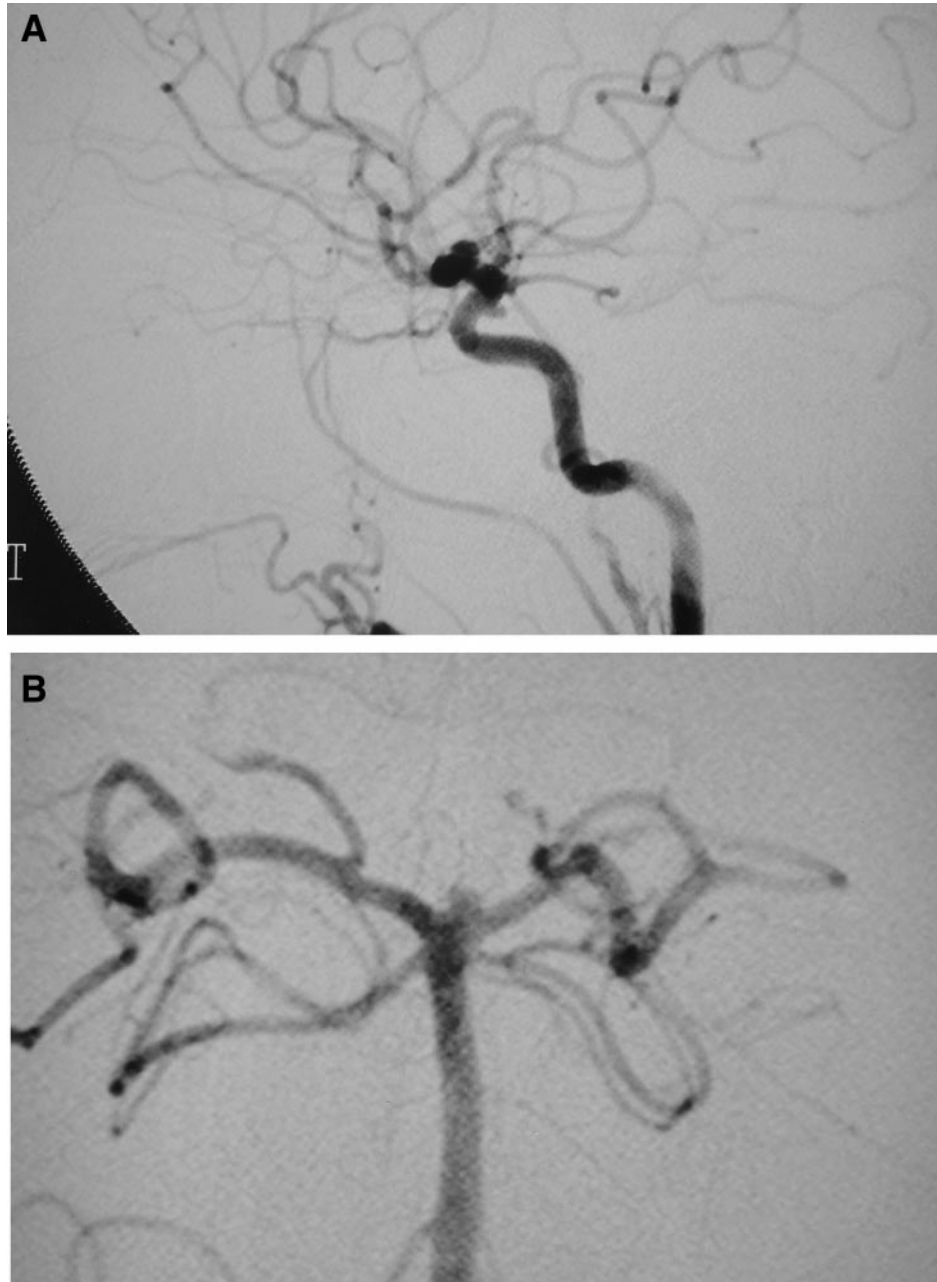
1 A & B. Retrograde jugulography showing a right jugular bulb diverticulum.

years). The most common clinical symptoms are hearing loss, tinnitus, and vertigo.

Stering et al reported that the cause of hearing loss was direct compression of the internal auditory meatus by the jugular bulb [11]. A “high” jugular bulb indicates that the position of the upper margin of the jugular fossa is above the level of the cochlea [12]. Jugular bulb diverticulum is usually located more medial and posterior to the petrous bone compared to a high jugular bulb.

Our patient’s symptoms were distinctly different

from those noted in previous cases; a lower cranial nerve palsy has never been reported in association with a jugular bulb diverticulum. However, it is unlikely that our patient’s symptoms were caused by the jugular bulb diverticulum, as they resolved with steroid pulse therapy. The fever that preceded the onset of her cranial nerve symptoms may indicate a viral infection that may have caused her symptoms, although there was no evidence of infection in serum or CSF studies. There has also been no previous report of a jugular bulb



2 A & B. Angiograms showing internal carotid and posterior communicating artery aneurysms and a basilar tip aneurysm.

diverticulum associated with multiple cerebral aneurysms.

Jugular bulb diverticulum can be seen clearly on jugular venography [2,5,9]. Although surgical intervention is not generally indicated in the treatment of jugular bulb diverticulum, Jahrsdoerfer et al sectioned the VIII nerve to successfully treat their patient's symptoms of vertigo and tinnitus [7]. Murakami et al reported that jugular bulb diverticulum is a congenital developmental anomaly that enlarges

with time, eventually reaching the internal auditory meatus and causing hearing loss, tinnitus, and vertigo [8]. Therefore, these patients must be observed carefully for the appearance of such symptoms.

CONCLUSION

Jugular bulb diverticulum associated with lower cranial nerve palsy and multiple cerebral aneu-

rysms has never before been reported. Close clinical observation is recommended in these cases regardless of presenting symptoms.

REFERENCES

1. Britton BH. Glomus tympanicum and glomus jugular tumors. *Radiol Clin North Am* 1974;12:543-51.
2. Cornell SH. Jugular venography. *Am J Roentgenol* 1969;106:303-7.
3. Dilenge D. The jugular notch. *J Can Assoc Radiol* 1977;28:274-7.
4. Farrel FW, Hantz O. Protruding jugular bulb presenting as a middle ear mass: case report and brief review. *Am J Roentgenol* 1977;128:685-7.
5. Gejrot T. Retrograde juglarography in the diagnosis of abnormalities of the superior bulb of the internal jugular vein. *Acta Otolaryngol* 1963;57:177-80.
6. Graham MD. The jugular bulb. Its anatomic and clinical consideration in contemporary otology. *Arch Otolaryngol* 1975;101:560-4.
7. Jahrsdoerfer RA, Cail WS, Cantrell RW. Endolymphatic duct obstruction from a jugular bulb diverticulum. *Ann Otol Rhinol Laryngol* 1981;90:619-23.
8. Murakami Y, Nomura Y. High jugular bulb with jugular bulb diverticulum. *JJCO* 1988;4:525-34.
9. Murao M, Kojima H, Takemura N, Tuchida T. High jugular bulb: clinical feature, radiographical finding and differential diagnosis, a case report. *Neurol Surg* 1996;24:755-8.
10. Pappas DG Jr., Hoffman RA, Cohen NL, Holliday RA, Pappas DG Sr. Petrous jugular malposition. *Otolaryngol-Head Neck Surg* 1993;109:847-52.
11. Stern J, Goldenberg M. Jugular bulb diverticula in medial petrous bone. *A J R* 1980;134:959-61.
12. Wadin K, Wilbrand H. The jugular bulb diverticulum: a radioanatomic investigation. *Acta Radiol Diag* 1986;27:395-401.

The only thing you should try to be is the best you can be. You should compete with yourself, not others.

No operation was ever improved by swearing or throwing instruments.

An operation is like a military campaign. The surgeon is the general. He should have the qualities to head his troops into battle. Leaders will be respected if they conduct themselves as leaders and not as tyrants. There is only one purpose to the operation and that is to win and decisively defeat the enemy disease. You must rehearse and prepare for the battle in order to win. Anything less than that, and the patient loses.