

Case Report

A Case of Churg–Strauss Syndrome Presenting with Cortical Blindness

A. Dinç¹, M. Soy¹, S. Pay¹, I. Simsek², H. Erdem¹ and G. Sobaci³

¹Division of Rheumatology, ²Department of Internal Medicine and ³Department of Ophthalmology, Gülhane School of Medicine, Ankara, Turkey

Abstract: A 46-year-old woman with a sudden sight loss due to infarction of the occipital lobes is reported. The association of pulmonary disease, digital ischaemia, polyneuropathy and peripheral eosinophilia led to a diagnosis of Churg–Strauss syndrome. Her vision partially improved by a treatment with steroids and monthly i.v. cyclophosphamide. To our knowledge, this is the first case of CSS with a sudden loss of vision due to bilateral occipital infarction.

Keywords: Churg–Strauss syndrome; Cortical blindness

Introduction

Churg–Strauss syndrome (CSS) is a disorder characterised by hypereosinophilia and systemic vasculitis occurring in individuals with recently developed atopic features [1]. Loss of vision is relatively uncommon. The cause of blindness in all reported cases has been associated with retina or optic nerve involvement [2–6]. We here describe a patient with CSS who developed acute bilateral blindness owing to infarction of the occipital lobes.

Case Report

A 46-year-old woman was referred for sudden loss of vision and ischaemic changes in the distal parts of two fingers. Her medical history consisted of bronchial asthma diagnosed 6 years earlier. Over the preceding 4 months fever, fatigue, increasing dyspnoea and a 10-kg

weight loss had developed. One month prior to admission patchy pulmonary infiltrates had been detected on chest X-ray. An infectious disease screen including tuberculosis (TB), had been found to be negative, and differential cell count of bronchoalveolar lavage fluid showed 45% neutrophils, 54% macrophages and 1% lymphocytes, which had led to a diagnosis of alveolitis; the patient had subsequently been started on 60 mg prednisolone daily. Despite this therapy her illness had not improved and muscle weakness, digital ischaemia and sudden-onset bilateral blindness had ensued.

On admission the patient appeared critically ill, with respiratory distress. Her blood pressure was 110/80 mmHg and her temperature was 37.5 °C. She had widespread crackles on chest auscultation and multiple palpable purpuric lesions on both palms.

The distal parts of the left thumb and the right index finger were cold and pale, but radial and ulnar pulses were palpable on both sides. Neuromuscular examination revealed bilateral decreased sensation with abolished deep tendon reflexes and proximal muscle weakness (a strength of 2/5) at the lower extremities. Although she denied light perception in both eyes, the direct and indirect pupillary light reflexes were intact (known as Anton's syndrome). Fundoscopic examination and fluorescein angiography were also normal. Flash visually evoked potentials (FVEP) were not recorded.

Westergren sedimentation rate was 110 mm/h. A haemogram showed a haematocrit of 25% and a WBC count of 10 200 mm³ with 16% eosinophils. C-reactive protein was 48 mg/l (normal = <6 mg/l). Urea, electrolytes, liver function tests, LDH and glucose were in normal ranges. Autoantibodies, including anti-nuclear antibodies, anticardiolipins, p-ANCA and c-ANCA, were negative. High-resolution CT of the thorax disclosed bilateral multiple patchy interstitial and

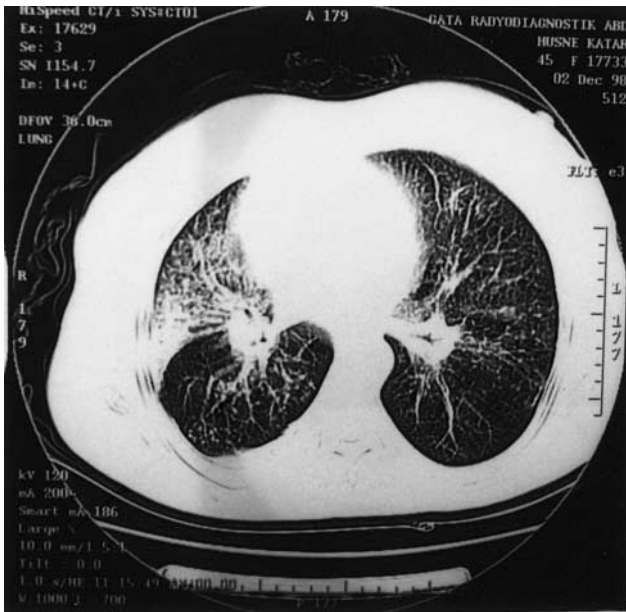
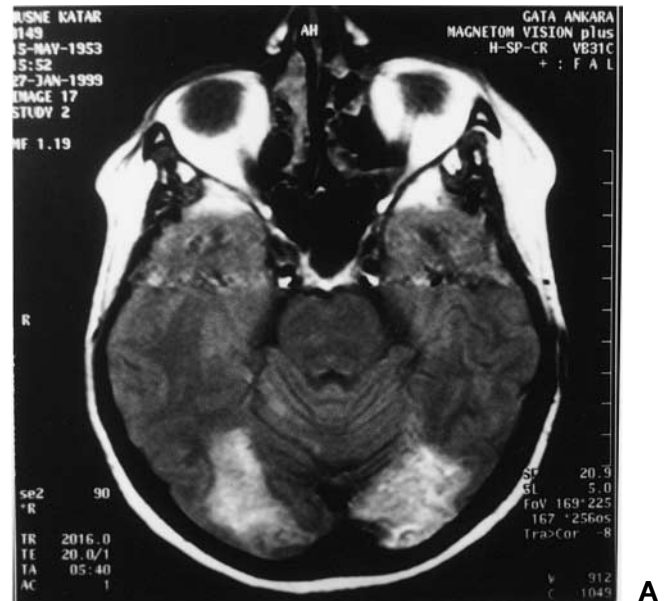


Fig. 1. High-resolution CT of the thorax shows interstitial and alveolar infiltrates.

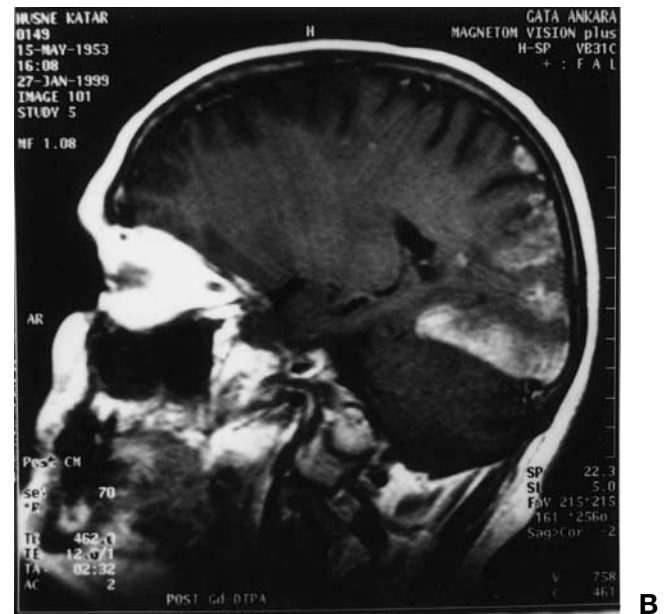
alveolar infiltrates without cavitation, and pleural calcifications (Fig. 1). Pulmonary function testing was consistent with an obstructive pattern and diffusion capacity (DL_{CO}) was decreased to 57%.

Contrast-enhanced MRI showed haemorrhagic infarctions extensively involving both occipital lobes. Scattered infarct areas in the frontal, sagittal and temporal lobes and the cerebellum were also detected. These lesions were hyperintense on both T_1 and T_2 sequences, and were enhanced by contrast. The optic nerves appeared normal and the mucosa of maxillary sinuses was thickened (Fig. 2). Even though electroneuromyography disclosed sensorimotor neuropathy at the lower extremities, sural nerve and adjacent muscle biopsies were unremarkable. Doppler ultrasound including the upper extremities and the carotid and vertebral arteries, was uneventful. Transthoracic and transoesophageal echocardiograms were also normal.

Although histological proof of vasculitis was not available, the presence of pulmonary infiltrates, eosinophilia, polyneuropathy and ischaemic changes to the fingers with antecedent bronchial asthma led us to consider possible CSS in this patient. Pulsed prednisolone (PRD) 1 g/day for 3 consecutive days followed by oral PRD 2 mg/kg/day, monthly intravenous pulse cyclophosphamide (1 g) and low molecular weight heparin were therefore started. The ischaemic digital changes, visual acuity, muscle strength and constitutional symptoms gradually improved. Over the ensuing week, acid-fast bacilli (AFB) became positive on the sputum examinations, which had been undertaken serially because of the existence of pleural calcification. Antituberculous treatment was added. Lumbar puncture revealed clear, acellular fluid with a glucose of 70 mg/dl and a protein of 40 mg/dl, and culture of cerebrospinal



A



B

Fig. 2A,B. T_2 -weighed and contrast-enhanced MRI showing haemorrhagic infarctions involving both occipital lobes. Scattered infarct areas in the sagittal lobe and cerebellum are also present in A.

fluid and polymerase chain reaction (PCR) analysis of DNA for *Mycobacterium tuberculosis* was negative, so we excluded CNS tuberculosis.

Two months later the visual acuities of the left and right eyes were 0.4 and 0.5, respectively, but the MRI findings were not changed. Visual field examination by confrontation and automated perimeter revealed right upper homonymous quadrantanopsia. The proximal muscle strength of the lower extremities improved (strength of 4/5). ESR was 32 mm/h, haematocrit was 35% and eosinophil count was 6%. The examinations for TB were also negative.

The patient has remained asymptomatic except for mild pulmonary and visual complaints over the succeeding 10 months, with the treatment regimen consisting of oral PRD, 1 mg/kg/day monthly intravenous pulse cyclophosphamide (1 g) and low molecular weight heparin.

Discussion

Although peripheral neuropathy is a common feature of CSS [7–9], the central nervous system is rarely affected. In large series, CNS involvement is present in only 6.4%–8.3% of cases [7,8]. It usually manifests as cerebral infarctions, cerebral haemorrhages, cranial neuropathies, cognitive disturbances, epilepsies and coma [10]. Ocular involvement or blindness in CSS is extremely rare. Reported cases with loss of vision have been attributed to vasculitis in the vessels of retina or optic nerves [2–6].

Cerebral infarctions in CSS have been ascribed to cerebral vasculitis. In our case it is probable that vasculitic involvement of the posterior and middle cerebral arteries may have been responsible for cerebral and cerebellar infarctions. Sural nerve biopsy of our patient was normal, as it was in 46% of CSS patients with peripheral neuropathy [9].

Although loss of vision due to occipital lobe involvement may occur in patients with giant cell arteritis or Wegener's granulomatosis [11–13], there is no report of cortical blindness in CSS. As in our patient, cortical blindness may show no abnormality on ophthalmologic examination, including pupillary reflexes; the sudden loss of vision may be misinterpreted as a psychiatric symptom.

Because our patient also had pulmonary tuberculosis (probably reactivated) we excluded tuberculous meningitis, which may also cause blindness or cerebral infarctions [14,15].

In this case, despite the lack of histological proof, the history of bronchial asthma, pulmonary infiltrates, eosinophilia, fever, weight loss, peripheral neuropathies, digital ischaemic changes and CNS infarcts was

consistent with a diagnosis of CSS. To our knowledge, this is the first case of CSS with a sudden loss of vision due to bilateral occipital infarction.

References

1. Gay RM Jr, Ball GV. Vasculitis. In: Koopman WJ, ed. Arthritis and allied conditions. 13th edn. Baltimore: Williams Wilkins, USA, 1997:1491–517.
2. Dagi LR, Currie J. Branch retinal artery occlusion in the Churg–Strauss syndrome. *J Clin Neuro-ophthalmol* 1985;5:229–37.
3. Kattah JC, Chrousos GA, Katz PA, McCasland B, Kolsky MP. Anterior ischemic optic neuropathy in Churg–Strauss syndrome. *Neurology* 1994; 44:2200–2.
4. Alberts AR, Lasonde R, Ackerman KR, Chartash EK, Susin M, Furie RA. Reversible monocular blindness complicating Churg–Strauss syndrome. *J Rheumatol* 1994;21:363–5.
5. Acheson JF, Cockerell OC, Bentley CR, Sanders MD. Churg–Strauss vasculitis presenting with severe visual loss due to bilateral sequential optic neuropathy. *Br J Ophthalmol* 1993;77:118–19.
6. Sutcliffe N, Morris V, Gomperts B, Brazier DJ, Isenberg DA, Cambridge G. Relationship between the development of blindness in Churg–Strauss syndrome and anti-myeloperoxidase antibodies. *Br J Rheumatol* 1997;36:273–5.
7. Guillevin L, Cohen P, Gayraud M, Lhote F, Jarrousse B, Casassus P. Churg–Strauss syndrome: clinical study and long-term follow-up of 96 patients. *Medicine (Baltimore)* 1999;78:26–37.
8. Sehgal M, Swanson JW, DeRemee R, Colby TV. Neurologic manifestations of Churg–Strauss syndrome. *Mayo Clin Proc* 1995;70:337–41.
9. Hattori N, Ichimura M, et al. Clinicopathological features of Churg–Strauss syndrome-associated neuropathy. *Brain* 1999;122:427–39.
10. Cottin V, Cordier JF. Churg–Strauss syndrome. *Allergy* 1999;54: 535–51.
11. Chisholm IH. Cortical blindness in cranial arteritis. *Br J Ophthalmol* 1975;59:332–3.
12. Thystrup J, Knudsen GM, Mogensen AM, Fledelius HC. Atypical visual loss in giant cell arteritis. *Acta Ophthalmol (Copenhagen)*. 1994;72:759–64.
13. Payton CD, Jones JM. Cortical blindness complicating Wegener's granulomatosis. *Br Med J (Clin Res Ed)* 1985;290:676.
14. Silverman IE, BA, Liu GT, Bilaniuk LT, Volpe NJ, Galta SL. Tuberculosis meningitis with blindness and perichiasmatic involvement on MRI. *Ped Neurol* 1995;12:65–67.
15. Leiguarda R, Berthier M, Starkstein S, Noguez M, Lylyk P. Ischemic infarction in 25 children with tuberculous meningitis. *Stroke* 1988;19:200–4.

*Received for publication 3 November 1999
Accepted in revised form 10 February 2000*