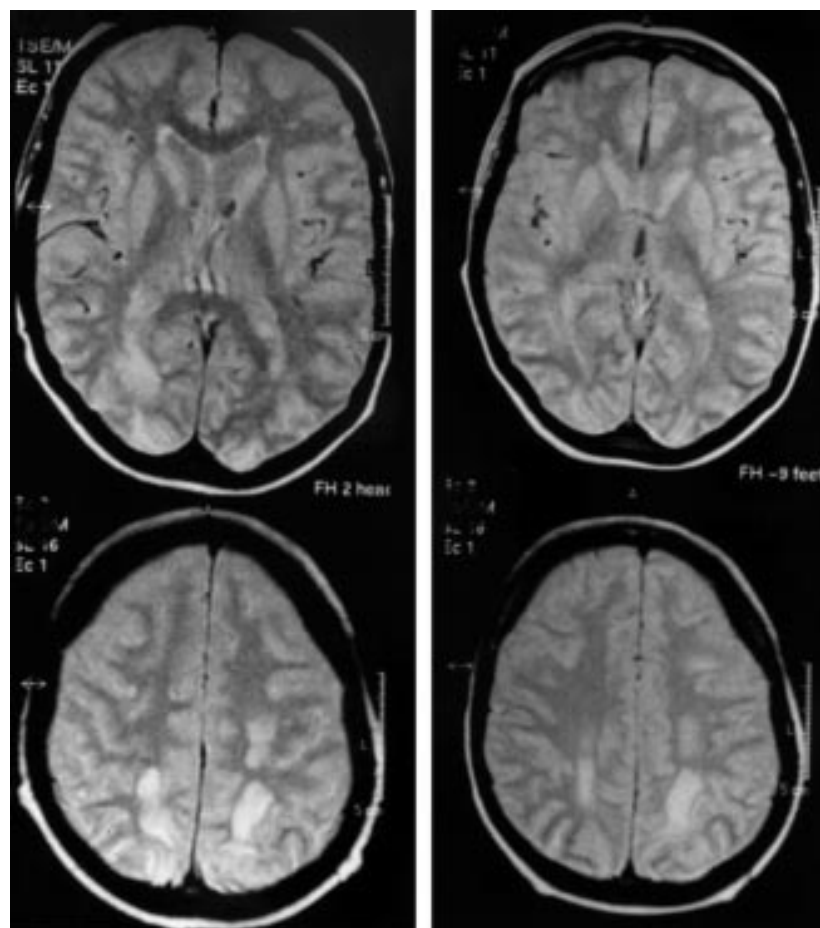

Left: bilateral PD hyperintensities in the parietal and occipital regions at the onset of symptoms. Right: bilateral PD hyperintensities in marked resolution 7 days later.

activity, sharp waves, and spike wave complexes; status could be terminated with 1 mg intravenous clonazepam.

Lumbar puncture and ultrasonography of the vertebral and basilar arteries did not show any abnormalities. Transoesophageal echocardiography showed normal left ventricular function. Routine biochemistry including electrolytes, creatinine, and blood urea nitrogen were normal throughout except increased C reactive protein (due to tumour). Haematological values showed pancytopenia. There was no evidence for viral and bacterial infection. A pleural effusion on the left side had developed before chemotherapy. A chest radiograph was now normal. Blood pressure was normal throughout.

As no other diagnosis could be ascertained, a causal relation with filgrastim, her sole new medication, was discussed. The patient was treated with a diuretic (furosemid), a neuroleptic (haloperidol), and anticonvulsants (phenytoin and clonazepam intravenously). The syndrome gradually remitted after 1 week without residue. The patient was well thereafter. Control MRI 7 days after the onset of symptoms showed hyperintensities in the parietal and occipital regions involving white matter in marked resolution on proton density images (figure).

This case demonstrates that the granulocyte stimulating factor filgrastim can have marked neurotoxic side effects in the form of a typical posterior leukencephalopathy syndrome in the absence of severe hypertension. The pathogenesis of posterior leukencephalopathy syndrome has remained illusive. It

probably reflects the increased vulnerability of posterior regions of the brain to different vascular, toxic, or metabolic disturbances. It has been suggested that the predelection for the posterior circulation is a consequence of poorer control of local cerebral autoregulation due to the relatively poorer sympathetic innervation. It cannot be stated whether in this case filgrastim neurotoxicity was due to direct toxic or transient vascular damage, by analogy with CNS toxicity reported after interleukin-2 therapy.<sup>4,5</sup> Both mechanisms seem possible.

T LENIGER  
O KASTRUP  
HC DIENER

Department of Neurology, University of Essen,  
Hufelandstrasse 55, 45122 Essen, Germany

Correspondence to: Dr Tobias Leniger  
tobias.leniger@uni-essen.de

- 1 Hinchey J, Chaves C, Appignani B, *et al.* A reversible posterior leukencephalopathy syndrome. *N Engl J Med* 1996;334:494-500.
- 2 Ay H, Buonanno FS, Schaefer PW, *et al.* Posterior leukencephalopathy without severe hypertension. Utility of diffusion-weighted MRI. *Neurology* 1998;51:1369-76.
- 3 Kastrup O, Diener HC. Granulocyte-stimulating factor filgrastim and molgrastim induced recurring encephalopathy and focal status. *J Neurol* 1997;244:274-5.
- 4 Formann AD. Neurological complications of cytokine therapy. *Oncology* 1994;8:105-10.
- 5 Illowsky Karp B, Jang JC, *et al.* Multiple cerebral lesions complicating therapy with interleukin-2. *Neurology* 1996;47:417-24.

# Acute adverse reaction to fentanyl in a 55 year old man

We report an acute drug induced adverse reaction to fentanyl that was not immediately recognised as such. A 55 year old police officer was given a small dose of diazepam (5 mg) and fentanyl (0.05 mg) for the treatment of left chest pain. Immediately after receiving the medication, the patient developed acute confusion, intermittent somnolence, and stupor, and fluctuating tetraparesis. Before the onset of symptoms, no relevant hypoxia or hypoglycaemia were found. Pre-existing medication consisted of 20 mg amitriptyline and 1000 mg metformin a day. On initial examination, the most obvious symptoms included profuse sweating, bilateral miosis (pinpoint pupils), and severe generalised myoclonus predominantly affecting the face. Babinski's sign was negative on both sides. The patient showed severe fluctuating tetraparesis. Investigation of the cranial nerves showed no abnormalities. On admission in our institution, the patient immediately underwent intubation and artificial ventilation for suspected pulmonary aspiration. Thiamin was started at 100 mg thrice daily. Myocardial infarction and dissection of the aorta were ruled out. The previously given dosage of fentanyl and diazepam did not seem to explain the current neurological condition of the patient. The symptoms of disturbance of consciousness, hemiparesis, generalised myoclonus, and pinpoint pupils pointed to brainstem injury. To rule out basilar artery thrombosis, CT angiography was performed. There were no pathological findings in the brainstem or the basilar artery.

Transcranial Doppler ultrasound and sensory evoked potentials were normal. The EEG under sedation with midazolam and fentanyl showed intermittent bilateral synchronised frontal delta rhythms. Systolic blood pressure was slightly increased, between 140 and 180 mm Hg. Due to the patient's development of pneumonia, artificial ventilation was continued, and further sedation was given with fentanyl/midazolam. Sedation was continued for 72 hours, with an infusion of fentanyl (0.157 mg/h) and midazolam (3.3 mg/h) for ventilation therapy. After sedation was stopped, the distinctive neurological symptoms abruptly improved. Within a few hours the patient was extubated. He then seemed normal, except for slight disorientation and agitation. Twelve hours after cessation of sedation, the patient was normal. To clarify and confirm the diagnosis of an adverse reaction to fentanyl, we carried out a provocation test after obtaining full informed consent. A dose of 0.1 mg fentanyl intravenously was enough to induce agitation, generalised myoclonus, and paroxysmal dystonic movements and rigor that particularly affected the legs. No cognitive disturbances were apparent. The fentanyl dose was then increased to a total of 0.2 mg. At this point, a 6 mg dose of diazepam was given but did not improve the agitation of the patient. In fact the patient reported increased agitation. Administration of a morphine antagonist, naloxone (0.8 mg intravenously) dramatically improved his condition, completely normalising the myoclonus, rigor, and paroxysmal movements. No further improvement occurred on administration of the benzodiazepine antagonist flumazenil (0.25 mg intravenously). As the effect of the naloxone wore off, there was a

reappearance of the dystonic movements. Under these conditions, the patient presented with distinct bilateral miosis, but no other disturbances.

Through this provocation test, the diagnosis was confirmed. As a result of an adverse reaction to fentanyl, the patient experienced an acute and unusual neurological syndrome. The clinical symptoms were agitation, generalised myoclonus, intermittent disturbances of consciousness, fluctuating bilateral hemiparesis, and pinpoint pupils. The diagnosis remained obscure for 72 hours due to the continuing ventilation, sedation, and analgesic treatment with fentanyl; indeed, it was the continuing administration of fentanyl that was maintaining the symptoms. Both the improvement after cessation of fentanyl, and the controlled provocation test confirmed the diagnosis.

In recent years, various central side effects of opioids have been described. These include generalised myoclonus, hyperalgesia, grand mal seizures, and agitation.<sup>1-4</sup> Although some reports have shown unexpected cerebral side effects after low doses of fentanyl,<sup>5</sup> in most cases this type of effect developed in patients receiving high doses of opiates for prolonged periods.<sup>1-3</sup>

Opiate induced myoclonus is often generalised and is either periodic or associated with rigidity, often occurs in the context of underlying medical conditions, and usually responds to either naloxone or benzodiazepines.<sup>4</sup> The mechanisms responsible for these adverse effects are not exactly known, but opiate, serotonergic, dopaminergic, and other mechanisms are considered.<sup>4</sup> The interesting feature of this particular case was the possibility of confusion of an acute fentanyl induced adverse syndrome with basilar artery thrombosis.

HANS JOERG STUERENBURG  
JAN CLAASSEN  
CHRISTIAN EGGERS  
HANS CHRISTIAN HANSEN  
Neurological Department, University Hospital  
Hamburg-Eppendorf, Martinistrasse 52, 20246  
Hamburg, Germany

Correspondence to: Dr HJ Stuerenburg  
stuerenburg@uke.uni-hamburg.de

- 1 Sjogren P, Erikson J. Opioid toxicity. *Curr Opin Anesthesiol* 1994;7:465-9.
- 2 De Stoutz ND, Bruera E, Suarez-Almazor M. Opioid rotation (OR) for toxicity reduction in terminal cancer patients. *J Pain Symptom Manage* 1995;10:378-84.
- 3 Bruera E, Pereira J. Acute neuropsychiatric findings in a patient receiving fentanyl for cancer pain. *Pain* 1977;69:199-201.
- 4 Lauterbach EC. Hiccup and apparent myoclonus after hydrocodone: review of the opiate-related hiccup and myoclonus literature. *Clin Neuropharmacol* 1999;22:8-92.
- 5 Henderson GL. Fentanyl-related deaths: demographics, circumstances and toxicology of 112 patients. *J Forensic Sci* 1991;36:422-33.

### Relapsing alternating ptosis in two siblings

In this *Journal*, Peatfield described the recurrence of cluster headaches presenting with a virtually painless Horner's syndrome in a 56 year old man.<sup>1</sup> This publication caused controversy on the dissociation between autonomic dysfunction and pain during cluster headache.<sup>2</sup> We add to this discussion our report on relapsing alternating ptosis in two siblings:

A 46 year old woman had intermittent episodes of alternating ptosis for more than 8 years. Her 47 year old sister was affected

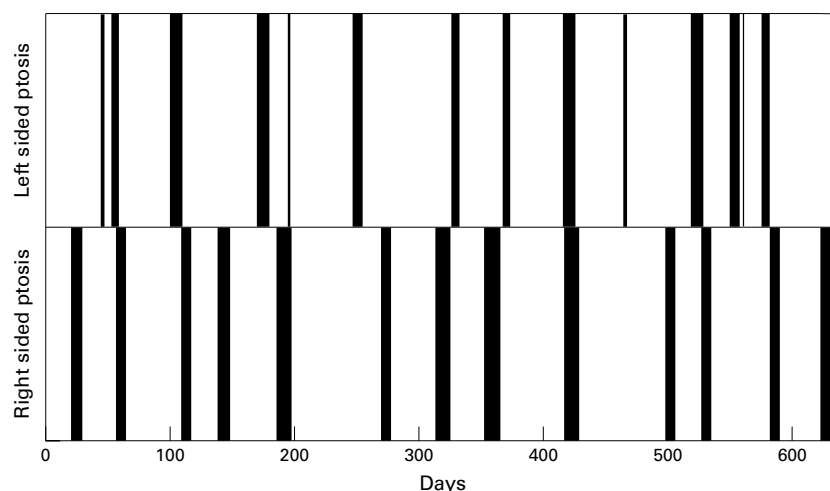


Figure 1 Occurrence of ptosis over a period of 21 months (protocol of the 46 year old patient). One eye after the other was affected intermittently (filled bars=presence of ptosis).

similarly. As shown in figure 1, attacks occurred more often than once a month with a mean duration of the episodes of 8 days (range 3-14 days). Intrinsic oculomotor muscles and the bulbar muscles were spared (fig 2). She never complained about double vision. Elevating and maintaining the ptotic eyelid in a fixed position during sustained upward gaze did not result in a drop of the opposite eyelid.<sup>3</sup> Signs of autonomic dysfunction and miosis were absent. The ptosis was never accompanied by miosis. There was no history of migraine or cluster headache. However, during the episodes they experienced some mild aching at the frontal region of the affected side. On the serotonin antagonist pizotifen, the younger sister felt improved due to slightly prolonged symptom free intervals. However, 60 mg prednisone every day for 6 weeks did not change the occurrence of ptosis.

On repeated neurological examination, there was no abnormality apart from the fluctuating ptosis. Magnetic resonance imaging of the brain, the orbital region, and the cervicothoracic spinal cord segments were normal. Laboratory studies showed no abnormality. Westergren sedimentation rate and serum creatine kinase activity were normal. Repeated tests for antiacetylcholine receptor antibodies were negative. Low rate repetitive nerve stimulation did not result in pathological decremental responses. Thyroid hormones and antibodies were in the normal range and absent, respectively. In the symptom free interval, pupillary responses to various pharmacological agents did not indicate a sympathetic dysfunction.

Relapsing alternating ptosis in two sisters is unique. In some aspects, our observation resembles Bielschowsky's relapsing alternating ophthalmoplegia.<sup>4</sup> Distinctive clinical features of this rare syndrome are the intermittent evolution of external ophthalmoplegias, the alternate involvement of one eye after the other, the constant sparing of the intrinsic oculomotor muscles, and the absence of pain.

We think that our finding of relapsing alternating ptosis is related to intermittent sympathetic dysfunction. Interestingly, in a subgroup of patients with cluster headache a "partial" Horner's syndrome may develop during each attack and disappear as the attack subsides. The term "partial" Horner's syndrome indicates that in patients with cluster headache one or two components of the

typical Horner's syndrome are present—that is, miosis or ptosis, whereas a third characteristic, anhidrosis, is lacking or even replaced by hyperhidrosis.<sup>5</sup> Some of the patients with cluster headache even show a permanent Horner-like syndrome on the symptomatic side.<sup>6</sup> Several studies on the pupil responsiveness in patients with cluster headache

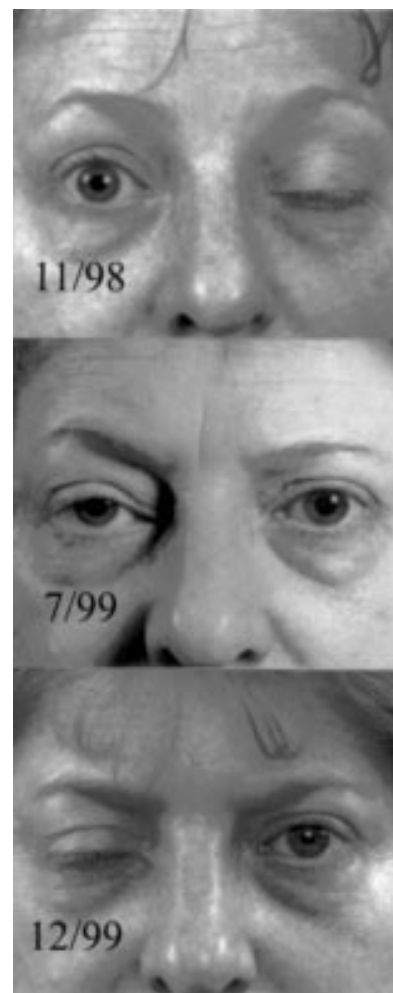

Figure 2 Alternating ptosis: representative findings between November 1998 (11/98) and December 1999 (12/99). Note the absence of miosis. The ptosis resolved completely each time.