

Loss of Left-Sided Volitional Movements Caused by a Combined Lesion of the Corpus callosum and Right Hemisphere: 'Initiation Pseudohemiparesis'

Kazumasa Yokoyama^a Chihiro Hasegawa^b Misumi Kameyama^c

^aNeurology Service, ^bClinical Psychology Section and ^cDepartment of Rehabilitation, Hyogo Rehabilitation Center, Kobe, Japan

Key Words

Loss of left unilateral volitional movements · Interhemispheric disconnection · Disturbances of movement initiation

Abstract

We report a right-handed patient who showed a marked loss of unilateral volitional movements of the left limbs after the onset of a cerebral infarction in the combined territories of the right anterior and middle cerebral arteries. The same limbs retained their mobility in acts requiring bilateral sides of the body. This left-sided abnormal behavior resembled motor neglect resulting from lateralized brain damage. Behavioral and neuroradiological findings presented by this patient, however, suggested that callosal disconnection was definitely involved in this symptomatology. We postulate that in this patient, the diseased right hemisphere could no longer initiate movements of the left limbs despite its potential ability to realize them, and that the injured corpus callosum prevented the intact left hemisphere from initiating unilateral voluntary movements of the left limbs. We suggest that this so far undescribed symptomatology be called 'initiation pseudohemiparesis' in order to be distinguished from other rare forms of unilateral voluntary movements like motor neglect, extinction or directional hypokinesia.

Copyright © 2000 S. Karger AG, Basel

Introduction

Loss of volitional motion of unilateral limb or limbs most commonly manifests itself as hemiplegia in cases of pyramidal tract disorders and as hemiparesis in cases of extrapyramidal system impairments. Other rare symptomatology includes motor neglect [1–5], motor extinction [6] and directional hypokinesia [7]. Yet another intriguing symptom is the motor initiation difficulty attributed to a contralateral medial frontal lesion [8]. In these abnormal states, the limb or limbs which cannot be moved voluntarily under certain conditions may demonstrate their movability under other conditions. In this paper, we report a right-handed patient who showed a total lack of unilateral voluntary movements of the left limbs contrasted with their retained bilateral movements after a cerebral infarction. We hypothesized that interhemispheric disconnection was the most plausible cause of this peculiar and so far undescribed syndrome.

Case Report

A 56-year-old right-handed male was admitted to a nearby hospital because of the acute onset of left motor weakness, and underwent a medical treatment with the diagnosis of cerebral infarction following a workup including CTs of the brain. He was transferred to our rehabilitation center because of his persistent left-sided motor distur-

KARGER

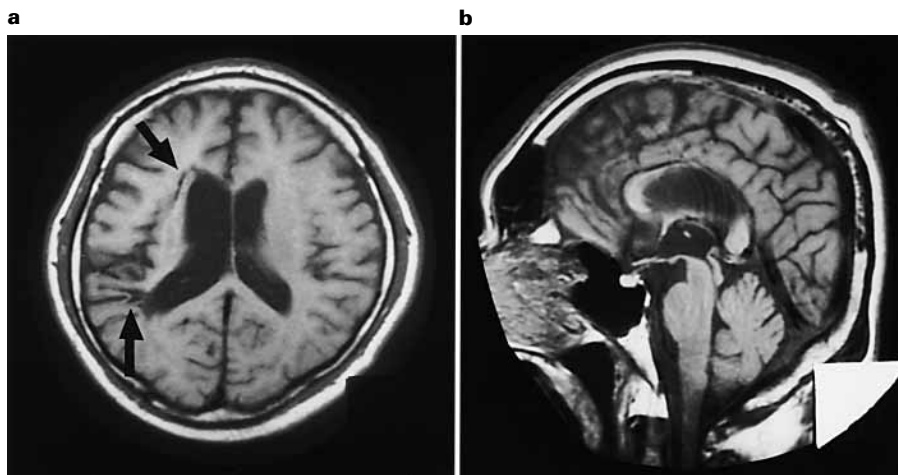
Fax + 41 61 306 12 34
E-Mail karger@karger.ch
www.karger.com

© 2000 S. Karger AG, Basel
0014–3022/00/0442–0086\$17.50/0

Accessible online at:
www.karger.com/journals/ene

Kazumasa Yokoyama, MD
Neurology Service, Hyogo Rehabilitation Center
1070 Akebonocho, Nishi-ku
Kobe 651-2181 (Japan)
Tel. +81 78 927 2727, Fax +81 78 925 9203

Fig. 1. MRI performed 3 months after onset. **a** Axial T₁-weighted images, showed two infarcts in the right hemisphere (arrows) and the enlarged right lateral ventricle, suggesting diffuse ischemic injury to the right hemisphere. **b** Sagittal T₁-weighted images demonstrated complete destruction of the trunk of the corpus callosum.



bances and neuropsychological deficits 2 months after onset. On examination at admission, motor function of his right limbs did not show any abnormality, but the left limbs stayed immobile and were dealt with by the patient as if they were completely paralyzed. As he was asked to move his left upper limb, he held the left arm with the right hand, and said 'My left hand is weak and does not work'. When he was requested to kick a ball in front of him with the left foot, he had the right foot thrust the motionless left foot at the ball, uttering the same difficulty. Despite the volitionally motionless left limbs, the left hand manifested a marked pathological grasp phenomenon and groped for tools or the examiner's hand as they came near it. The alien hand sign was also observed. For example, as the right hand was scratching his head, the left hand gradually reached up to the left ear without the patient's intention, and the right hand grabbed the left upper limb and tried to bring it back to its original position. As another example, when the right hand picked up a pencil and started writing, the left hand disturbed the right hand's performance by moving toward the pencil to grasp it. The patient said to his left hand, 'Mind your business'. Don't disturb me in writing'. The neurological examination also showed intact muscle tone on the right side and mild paratonic rigidity on the left upper limb, and slight hypertonicity on the left lower limb. Reflexes were normal. Superficial sensation was normal. Strong nociceptive stimuli applied to the left extremities did not elicit any withdrawal movements, although he reported pain at the exact locations. Position sense was preserved, except for the left hand and wrist where his verbal answers to directions of joint movements were inaccurate, and his right upper limb failed to non-verbally indicate in which direction they had been moved. Two-point discrimination was preserved within any part of the body, but he often failed to detect two simultaneous tactile stimuli applied to different distal parts of the left side of the body. For example, he only reported the stimulus on the face when he was touched both on the face and the hand. The total lack of voluntary movements prevented us from testing stereognostic sensation on the left side in detail. He was unable to recognize skin-writing on the left side. Mild visual and tactile extinctions were noted. The cranial nerves were unremarkable except for a slight left facial paresis. The patient was well oriented to time and place. His fluent spontaneous speech with good articulation showed no signs suggestive of aphasia. He scored 22 points on the MMS with errors on 4 of the 7 serial subtractions, all 3 items for

recall and figure copying. He scored 11 on the Raven Colored Progressive Matrices. Slight left-sided spatial neglect was noted on drawing of daisy, line bisection and three-dimensional block constructions. Marked motor imperistence was observed. He could only keep his eyes closed for 2 s, his tongue protruded with eyes open for 13 s or his gaze fixed for 1 s. His digit span score was 7 forward. MRI showed diffuse enlargement of the right lateral ventricle, and two infarcts in the right hemisphere with another lesion destroying the entire trunk of the corpus callosum (fig. 1). Generalized hypoperfusion in the right anterior and middle cerebral artery territories was shown on SPECT scan with ^{99m}Tc.

Conventional physical and occupational therapy given after admission brought no improvement in unilateral voluntary motor function of his left limbs. But as the alien hand sign gradually disappeared within the first month of hospital stay, the left limbs came to move in cooperation with the right side in volitional activities requiring both sides of the body such as getting dressed or walking despite continued unsuccessful attempts at unilateral voluntary movements of the left side. Actions initiated by the right side of the body under the patient's control often led the left side to move in quite a cooperative and purposeful fashion instead of its autonomous and sometimes conflictive movements, as had been seen before. For instance, as the patient was asked to put on a jacket, the action of the right hand to help the left hand into the left sleeve led the left upper limb to move efficiently above shoulder, to go through the left sleeve and out at its end. Gait was another example illustrating the good performance of the left limbs in bilateral movements. The left lower limb remained immobile on any attempts at unilateral voluntary acts, but as soon as he was requested to walk and was helped to stand up, he started walking in quite a normal fashion with a T cane in his right hand. His gait was accompanied by good left arm swing with neither spasticity nor circumduction on the left lower limb. Stepping on stairs showed good dorsiflexion of the left foot.

The motor problems of the left side showed no practical change during the rest of his 3-month hospital stay and at a follow-up examination 2 years after discharge. The overall clinical picture is summarized in table 1.

Table 1. Clinical and MRI findings characterizing this patient

Behavioral characteristics of the left limbs	Other major findings
1 Loss of volitional unilateral movements with no amelioration following commands to use them	1 Mild left cortical sensory loss
2 Preserved acts requiring bilateral sides of the body	2 Mild left visual and tactile extinction
3 Transient alien hand sign	3 Mild left unilateral spatial neglect
4 Pathological grasp phenomenon	4 Motor impersistence
	5 Destruction of the entire trunk of the callosum and diffuse injury in the right hemisphere on MRI

Comment

The conspicuous lack of voluntary unilateral movements of this patient's left limbs was certainly not due to hemiparalysis secondary to corticospinal tract lesions. He had no obvious weakness or spasticity. Hemiakinesia from hemiparkinsonism could not explain the syndrome either, because there was no true rigidity in the affected limbs. Unilateral motor neglect [1–5] is characterized by spontaneous underutilization of one side of the body which can demonstrate near normal motility when attention is fully directed to that side. Any efforts to concentrate attention to the left side failed to move the left limb of the present case, making this explanation unlikely. We believe that the most plausible explanation for this selective loss of the unilateral voluntary movements is the failure of the right hemispheric motor area to be put into action in response to a volition to move. The lesions in the right hemisphere must have prevented this hemisphere from starting motions on its own. All the commands to start a motion must have arisen unilaterally in the left hemisphere and been transmitted to the right hemisphere via the corpus callosum. The lesion of the corpus callosum in the present case must have obstructed this informational flow. Two facts support our hypothesis. First, the initial presence of left alien hand sign has been explained by a callosal disconnection [9, 10]. Second, situations that require bilateral coordination succeeded in putting the left limbs into normal action. The phenomenon also has been observed in cases of callosal disconnection [11]. It has been assumed that ipsilateral motor innervation from the left hemisphere can mobilize the proximal muscles for successful coordinated actions. Fukui et al. [8] reported a patient with intermittent movement initiation difficulty, associated with ideomotor apraxia of the left hand and diagnostic apraxia due to injury to the anterior half of the callosum and the right medial frontal lobe. Their case favors our hypothesis by suggesting that the initiation of

unilateral movements could be disturbed on account of interhemispheric disconnection. 'Initiation pseudo-hemiakinesia', which we assume properly expresses this so far undescribed symptomatology of our patient, should be distinguished from other rare forms of unilateral voluntary movements like motor neglect, extinction or directional hypokinesia.

Denny-Brown et al. [12] reported a female patient with a right hemisphere stroke who showed unawareness and defective control of her left side which they postulated had resulted from an extreme degree of sensory extinction and imperception of the cortical origin. Although our patient showed a modest degree of impaired left-sided sensation and perception, cortical sensory loss of the type they designated as amorphosynthesis is insufficient to explain his behavioral abnormalities, considering that the patient of Denny-Brown et al. [12] could get her left limb back under control when her attention was directed to her left limb, in contrast to our patient who was encouraged to use the left limbs in vain.

Acknowledgment

We are grateful to Prof. Atsushi Yamadori for critical review of an earlier draft of the manuscript.

References

- 1 Castaigne P, Laplane D, Degos JD: Trois cas de négligence motrice par lésion rétro-rolandique. *Rev Neurol (Paris)* 1970;122:233–242.
- 2 Castaigne P, Laplane D, Degos JD: Trois cas de négligence motrice par lésion frontale pré-rolandique. *Rev Neurol (Paris)* 1972;126:5–15.
- 3 Schott B, Laurent B, Mauguière F, Chazot G: Négligence motrice par hématorne thalamique droit. *Rev Neurol (Paris)* 1981;137:447–455.
- 4 Laplane D, Escourolle R, Degos JD, Sauron B, Massiou H: La négligence motrice d'origine thalamique. A propos de deux cas. *Rev Neurol (Paris)* 1982;138:201–211.
- 5 Laplane D, Degos JD: Motor neglect. *J Neurol Neurosurg Psychiatry* 1983;46:152–158.
- 6 Valenstein E, Heilman KM: Unilateral hypokinesia and motor extinction. *Neurology* 1981; 31:445–448.
- 7 Coslett HB, Bowers D, Fitzpatrick E, Haws B, Heilman KM: Directional hypokinesia and hemispatial inattention in neglect. *Brain* 1990; 113:475–486.
- 8 Fukui T, Endou K, Sugishita M, Tsukakoshi H: A case of callosal damage accompanied with ideomotor apraxia without agraphia, diagnostic apraxia and intermittent initiation difficulty of left hand. *Clin Neurol (Tokyo)* 1987;27: 1073–1080.
- 9 Della Sala S, Marchetti C, Spinnler H: Right-sided anarchic (alien) hand: A longitudinal study. *Neuropsychologia* 1991;29:1113–1127.
- 10 Feinberg TE, Schindler RJ, Flanagan NG, Laurence DH: Two alien hand syndromes. *Neurology* 1992;42:19–24.
- 11 Geschwind N, Kaplan E: A human cerebral disconnection syndrome: A preliminary report. *Neurology* 1962;12:675–685.
- 12 Denny-Brown D, Meyer JS, Horenstein S: The significance of perceptual rivalry resulting from parietal lesion. *Brain* 1952;75:433–471.

Copyright: S. Karger AG, Basel 2000. Reproduced with the permission of S. Karger AG, Basel. Further reproduction or distribution (electronic or otherwise) is prohibited without permission from the copyright holder.

Copyright: S. Karger AG, Basel 2000. Reproduced with the permission of S. Karger AG, Basel. Further reproduction or distribution (electronic or otherwise) is prohibited without permission from the copyright holder.