

Epileptic Seizures Attributed to Cerebral Hyperperfusion after Percutaneous Transluminal Angioplasty and Stenting of the Internal Carotid Artery

David Sai Wah Ho^a Yan Wang^a Michele Chui^a Shu Leong Ho^b
Raymond Tak Fai Cheung^b

Divisions of ^aCardiology and ^bNeurology, Department of Medicine, University of Hong Kong, Queen Mary Hospital, Hong Kong, PRC

Key Words

Cerebral hyperperfusion injury · Carotid artery stenosis · Angioplasty · Stenting

Abstract

Cerebral hyperperfusion syndrome as a complication of carotid endarterectomy (CEA) has been widely reported in the surgical literature. It may occur within hours to 3 weeks after CEA and is characterized by symptoms ranging from headaches, fits, confusion, focal neurological signs to intracerebral hemorrhage. Although percutaneous transluminal angioplasty (PTA) and stenting are increasingly performed as an alternative to CEA in the treatment of carotid artery stenosis, few cases of cerebral hyperperfusion injury following carotid stenting have been reported. We describe 2 cases of cerebral hyperperfusion syndrome following PTA and stenting for high-grade internal carotid artery (ICA) stenosis. Both cases involved a lesion of 95% in severity. The first case was a 73-year-old man who developed generalized convulsion 7 h following stenting to the left ICA. The second case was an 80-year-old woman who developed recurrent right periorbital headache and confusion 16 h after

stenting to the right ICA, followed by left upper limb seizure 14 days later. Both patients fully recovered without any intracerebral hemorrhage or infarction. To our knowledge, this is the first report of cerebral hyperperfusion injury after carotid stenting without associated intracranial hemorrhage and with full recovery. In the patient with neurological symptoms following carotid stenting, it is important to consider cerebral hyperperfusion syndrome as a differential diagnosis to embolic or hemorrhagic stroke since early recognition and meticulous control of blood pressure may prevent progression to cerebral hemorrhage and death.

Copyright © 2000 S. Karger AG, Basel

Cerebral hyperperfusion syndrome has been widely reported in the surgical literature as a complication of carotid endarterectomy (CEA) and is associated with significant morbidity and mortality [1, 2]. The syndrome is characterized by symptoms ranging from unilateral headache, confusion, seizures, focal neurological deficit to intracranial hemorrhage [3]. Typically, this syndrome is found in patients with chronic severe cerebral ischemia and occurs within hours to 3 weeks after correction of a

high-grade carotid stenosis [1, 4, 5]. Its pathophysiology is related to preoperative loss of cerebral autoregulatory mechanisms [6].

Percutaneous transluminal angioplasty (PTA) and stenting of the carotid arteries is increasingly performed as an alternative to CEA in the treatment of carotid stenosis. While hyperperfusion syndrome as a complication of CEA has been widely reported, few cases of such complications have been reported in association with carotid PTA.

From our series of 36 patients treated with PTA and stenting to their extracranial carotid arteries from 1996 to 1999, we report 2 patients with severe internal carotid artery stenosis who developed cerebral hyperperfusion syndrome. In both cases, a typical clinical hyperperfusion syndrome occurred in the absence of intracerebral hemorrhage or infarction.

Case Reports

Case 1

A 73-year-old right-handed man presented with a 2-year history of recurrent right upper limb weakness and amaurosis fugax involving the left eye, with each episode lasting 1–2 min. Despite maximal medical therapy, his attacks recurred every second day. The patient was a heavy smoker with a history of hypertension, hypercholesterolemia and double-vessel coronary artery disease. The patient scored 1 in the baseline National Institute of Health Stroke Scale (NIHSS) due to his mild right-sided facial weakness. A carotid duplex scan showed severe stenosis in the left internal carotid artery (ICA). A Diamox SPECT brain scan showed reduced flow reserve to the left middle cerebral artery territory but a computed tomographic (CT) brain scan showed no cerebral infarction.

A cerebral angiogram confirmed a 95% stenosis in the left ICA and an 80% stenosis in the left vertebral artery. PTA and stenting of the left ICA were performed. Following balloon angioplasty and the deployment of a self-expanding stent (Wallstent® 8 × 20 mm; Boston Scientific, Watertown, Mass., USA), an excellent angiographic result was achieved with no residual stenosis (fig. 1). The patient was neurologically stable until 7 h after the procedure when he developed recurrent and almost incessant generalized tonic-clonic seizures. Blood pressure (BP) at the time was 170/95 mm Hg. The patient was intubated and ventilated. His convulsions resolved with intravenous diazepam and phenytoin, and when his blood pressure was brought down to 115/60 mm Hg. A CT brain scan showed no remarkable changes from the pre-procedure state. EEG showed postictal changes. The patient was extubated 24 h later with an NIHSS of 3. By day 6, his NIHSS had returned to 1. A further CT scan on day 9 remained unchanged from the 2 previous CT scans. The patient was discharged with no neurological deficit. Magnetic resonance imaging (MRI) of the brain 3 months after the procedure showed no remarkable changes compared to baseline. Angiographic follow-up at 6 months after carotid PTA showed a widely patent left ICA. To date, at 2 years of follow-up, the patient has remained well and has had no further neurological events.

Case 2

An 80-year-old woman with a history of diabetes mellitus, hypertension, hyperlipidemia, coronary artery disease and peripheral vascular disease presented with transient left arm weakness. A carotid duplex scan showed bilateral carotid stenosis. A cerebral angiogram showed a high-grade 95% stenosis in the right ICA and 80% stenosis in the left ICA. Carotid PTA was performed to the right ICA and the stenosis was reduced to 0% residual following the deployment of a self-expanding stent (Wallstent 6 × 17 mm; Boston Scientific, fig. 2). Overnight, the patient developed mild confusion and complained of right eye discomfort. An ophthalmologist was consulted but no definitive diagnosis was made. Simple analgesics were prescribed and the patient was discharged on day 2 with an NIHSS score of 0. Following discharge, the patient continued to experience a right periorbital headache. On day 14, while squatting down scrubbing her bathroom, the patient developed spasm of the left arm. She called out for help and lost consciousness shortly afterwards. On admission, her BP was 220/110 mm Hg. There was recurrent focal seizures of the left upper limb. The patient was intubated and ventilated. Her convulsions settled with intravenous diazepam and phenytoin, and when her BP was brought down to 130/50 mm Hg. A CT brain scan showed no remarkable change. The patient rapidly regained consciousness and was extubated the next day. She was discharged a week later with an NIHSS score of 0. MRI of the brain at 35 days after PTA did not show any abnormality. A 6-month angiographic follow-up showed a widely patent right ICA with no restenosis. To date, at 18 months of follow-up, the patient has remained well with no neurological events.

Discussion

The cerebral hyperperfusion syndrome has been widely reported in the surgical literature as a complication of CEA [1, 2]. Preoperatively, cerebral oligemia in the hypoperfused area causes maximal vasodilatation of vessels distal to the stenosis. Because these maximally vasodilated vessels cannot readily constrict, sudden reopening of the stenosed vessels may result in relative hyperperfusion and potential endothelial damage, vessel disruption, edema and hemorrhage.

PTA and stenting is increasingly performed as an alternative to CEA in the treatment of carotid stenosis in certain patient subgroups, including those with high cervical lesions, patients with multiple comorbidities, restenosis following CEA and stenosis following radiotherapy or radical neck dissection. There are few reports of cerebral hyperperfusion syndrome following carotid stenting procedures. Both our patients had high-grade stenosis in the ICA with the ipsilateral anterior cerebral artery (ACA) filling poorly from the contralateral ICA. In the second patient, the contralateral ICA also had an 80% stenosis. Carotid stenting in both patients restored full patency to their diseased ICA, resulting in the filling of ACA from the ipsilateral ICA and resolution of previous oligemia in

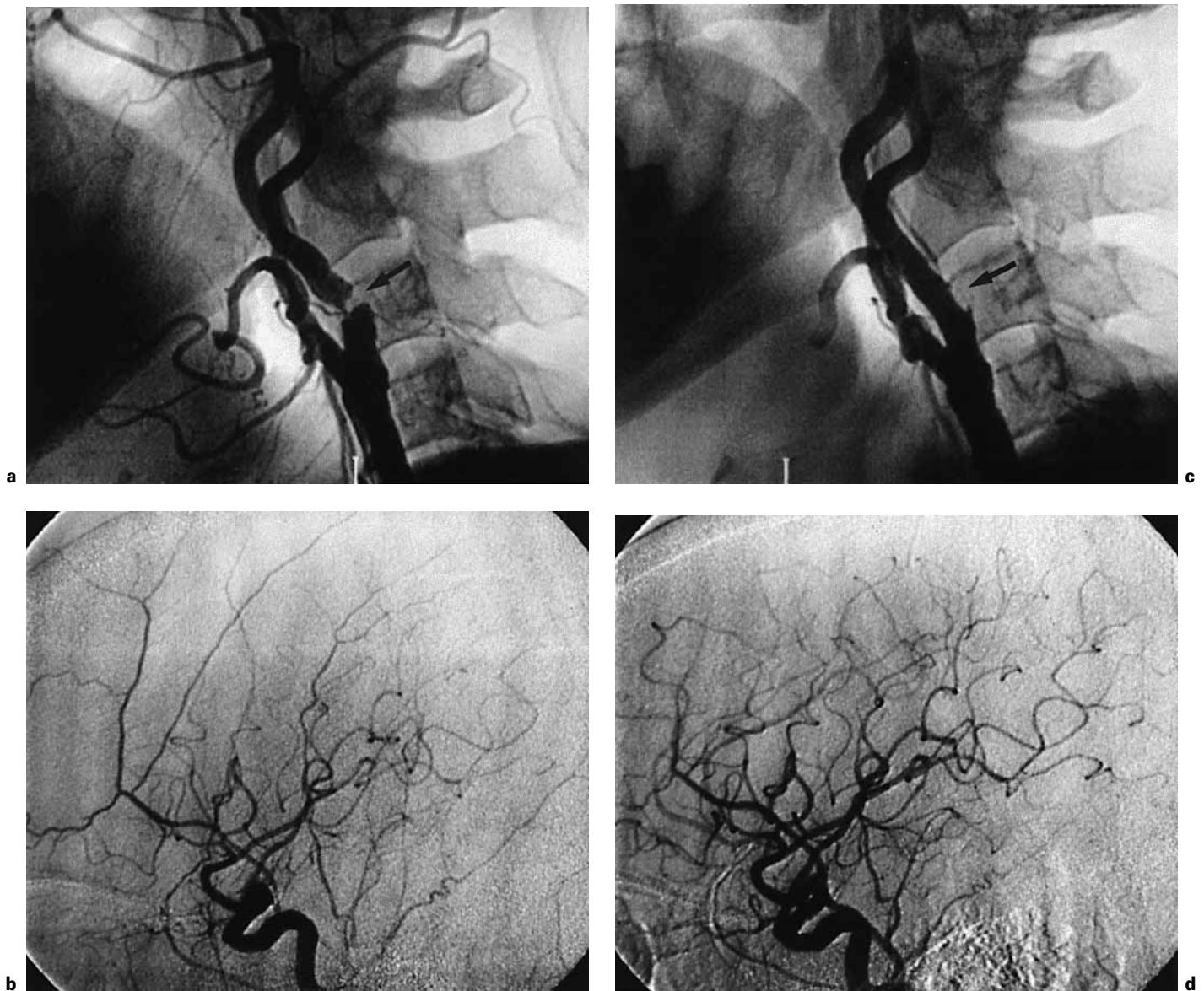


Fig. 1. **a** Lateral projection showing 95% stenosis (arrow) in the left ICA before angioplasty. **b** Digital subtraction angiogram in lateral projection showing oligemia in the left middle cerebral artery and anterior cerebral artery territories. **c** Following angioplasty and stenting, the left ICA became widely patent (arrow). **d** A digital subtraction angiogram now shows brisk blood flow to the left anterior and middle cerebral artery territories.

the respective middle cerebral artery region. Both developed a typical hyperperfusion syndrome with headache, seizures and focal neurological deficits. Following prompt antihypertensive and anticonvulsant therapies, both our patients recovered fully without any neurological deficits and without any progression to cerebral hemorrhage. To our knowledge, this is the first report of such a phenomenon following carotid PTA in the absence of intracerebral

hemorrhage and with full recovery. Our findings suggest that cerebral hyperperfusion syndrome similar to that described as a post-CEA complication may occur after PTA and stenting to high-grade carotid stenosis. In the only other report of 2 cases of cerebral hyperperfusion injury associated with carotid PTA, both cases reported had intracranial hemorrhage followed by stroke and death, respectively [4].

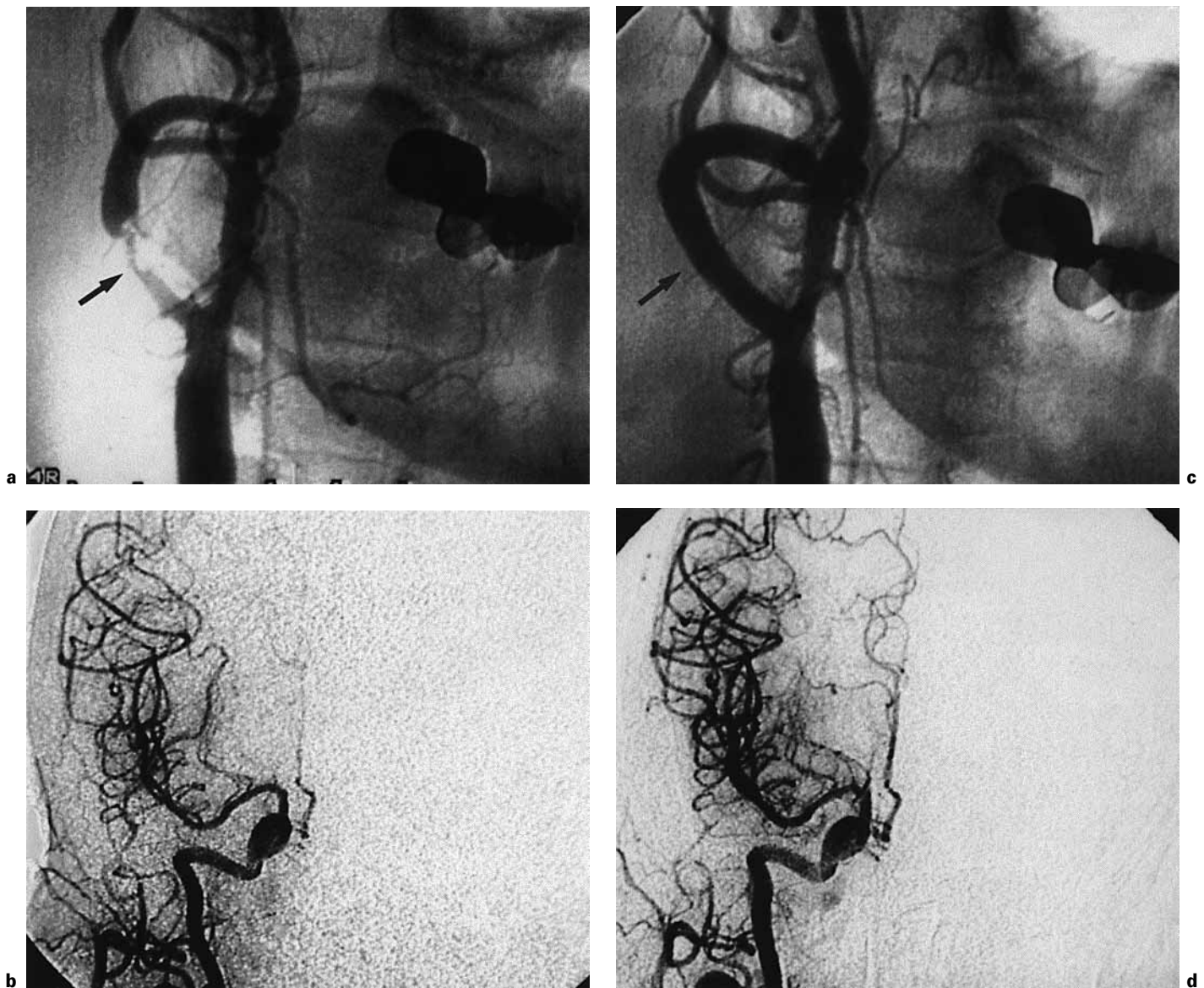


Fig. 2. **a** Right anterior oblique projection showing 95% stenosis (arrow) in the right ICA before angioplasty. **b** Digital subtraction angiogram in anteroposterior projection showing oligemia in the right middle cerebral artery and anterior cerebral artery territories. **c** Following angioplasty and stenting, the right ICA became widely patent (arrow). **d** Digital subtraction angiography now shows brisk blood flow to the right middle and anterior cerebral artery territories.

Cerebral hyperperfusion syndrome may be more common than previously assumed. Its reported incidence following CEA is between 0.3 and 1.2% [1, 7–10], and that of intracerebral hemorrhage following CEA with hyperperfusion syndrome being a major cause is 0.6–2.0% [10–13]. However, most CEA series have included asymptomatic patients and not all patients had high-grade lesions. Indeed, hyperperfusion syndrome may present as seizures

in 3% of patients following CEA [3] and has been documented by transcranial Doppler ultrasonography (TCD) to occur in 6% of patients following CEA [14]. The incidence is even higher in patients with >90% stenosis and in those with hypertension [2]. Around 40% of patients with seizures progress to develop cerebral hemorrhage [1, 15] with a mortality of >50% [5]. Risk factors include: high-grade stenosis (>90%) with limited hemispheric col-

lateral flow; a large pressure gradient across the stenosis; contralateral carotid occlusion; evidence of chronic ipsilateral hypoperfusion; pre- and postoperative hypertension; perioperative anticoagulation or antiplatelet therapy and angioplasties of multiple extracranial cerebral vessels in one sitting [1, 7–11, 16, 17]. Management is largely based on prevention, early recognition and meticulous blood pressure control. The use of prophylactic anticonvulsants remains controversial. There may be a role for TCD in the perioperative monitoring of patients with high-grade carotid stenosis. Those with marked low perfusion and poor perfusion reserve before the revascularization procedure should be monitored carefully during the postprocedural period. Postprocedure TCD can offer early detection of elevated cerebral blood flow to 2–4 times over baseline levels. While CT scanning is important to document the presence or absence of cerebral hemorrhage, white-matter edema may be overlooked or misinterpreted as infarction [18]. Diffusion-weighted MRI can document white-matter edema and is useful in differentiating between the cytotoxic edema of cerebral ischemia and the interstitial edema of hyperperfusion syndrome [18].

Early symptoms of cerebral hyperperfusion include ipsilateral frontotemporal or periorbital headaches, seizures, confusion and transient focal neurological signs [3]. These symptoms may progress to intracerebral hemorrhage with permanent neurological deficits or death [1, 3]. In fact, some cases presenting with early symptoms have been thought to represent microembolization and have been treated with heparin, sometimes with subsequent intracerebral hemorrhage [19–21]. Since these symptoms overlap with the neurological complications of carotid PTA, including those caused by embolic events from

endovascular manipulation, hemodynamic compromise during balloon inflation, arterial spasm or dissection, intracranial hemorrhage secondary to prophylactic anticoagulation or antiplatelet therapy, and early restenosis or occlusion, it is important for the physicians to recognize and differentiate cerebral hyperperfusion from such complications.

Limitations

While we were aware of the cerebral hyperperfusion syndrome in association with CEA, this syndrome was low on our list of differential diagnoses at the time. Our immediate concern was to rule out any hemorrhagic or major ischemic stroke by CT scan. Since the patient was managed in the Intensive-Care Unit and we did not have a portable TCD machine, TCD or diffusion-weighted MRI was not performed. Nevertheless, our treatment was focused on control of hypertension and ventilatory support. Although our patients' symptoms could have resulted from cerebral ischemia, subsequent full recovery with no new lesions on CT scan and MRI does not support this differential diagnosis. In our second case, the classic warning symptom of ipsilateral periorbital headache was present to suggest hyperperfusion. Although contrast medium has been reported to cause convulsions, the reported cases were confined to cranial CT scans in patients with a history of seizure or structural cranial abnormalities such as brain metastases [22, 23]. Our patients did not have these conditions. The delayed presentation of our patients also makes contrast-induced seizure unlikely.

References

- 1 Reigel MM, Hollier LH, Sundt TM Jr, Piepgras DG, Sharbrough FW, Cherry KJ: Cerebral hyperperfusion syndrome: A cause of neurologic dysfunction after carotid endarterectomy. *J Vasc Surg* 1987;5:628–634.
- 2 Sbarigia E, Speciale F, Giannoni MF, Colonna M, Panico MA, Fiorani P: Post-carotid endarterectomy hyperperfusion syndrome: Preliminary observations for identifying at risk patients by transcranial Doppler sonography and the acetazolamide test. *Eur J Vasc Surg* 1993;7: 252–256.
- 3 Penn AA, Schomer DR, Steinberg GK: Imaging studies of cerebral hyperperfusion after carotid endarterectomy: Case report. *J Neurosurg* 1995;83:133–137.
- 4 Schoser BG, Heesen C, Eckert B, Thie A: Cerebral hyperperfusion injury after percutaneous transluminal angioplasty of extracranial arteries. *J Neurol* 1997;244:101–104.
- 5 Mansoor GA, White WB, Grunnet M, Ruby ST: Intracerebral hemorrhage after carotid endarterectomy associated with ipsilateral fibrinoid necrosis: A consequence of the hyperperfusion syndrome? *J Vasc Surg* 1996;23:147–151.
- 6 Sundt TM Jr, Sharbrough FW, Piepgras DG, Kearns TP, Messick JM, O'Fallon WM: Correlation of cerebral blood flow and electroencephalographic changes during carotid endarterectomy. *Mayo Clin Proc* 1981;56:533–543.
- 7 Sundt TM Jr, Sharbrough FW, Piepgras DG, Kearns TP, Messick JM, O'Fallon WM: Correlation of cerebral blood flow and electroencephalographic changes during carotid endarterectomy. *Mayo Clin Proc* 1981;56:175–181.
- 8 Solomon RA, Lofus CM, Quest DO, Correll JW: Incidence and etiology of intracerebral hemorrhage following carotid endarterectomy. *J Neurosurg* 1986;64:29–34.

- 9 Hafner DH, Smith RB III, King OW, Perdue GD, Stewart MT, Rosenthal D, Jordan WD: Massive intracerebral hemorrhage following carotid endarterectomy. *Arch Surg* 1987;122:305–307.
- 10 Schroeder T, Sillesen H, Boesen J, Laursen H, Sorensen PS: Intracerebral hemorrhage after carotid endarterectomy. *Eur J Vasc Surg* 1987;1:51–60.
- 11 Schoser BG, Heesen C, Eckert B, Thie A: Cerebral hyperperfusion injury after percutaneous transluminal angioplasty of extracranial arteries. *J Neurol* 1997;244:101–104.
- 12 Jensen C, Sprengers AM, Moll FL, Vermeulen FE, Hamerlijnck R, Van Gijn J, Ackerstaff RG: Prediction of intracerebral hemorrhage after carotid endarterectomy by clinical criteria and intraoperative transcranial Doppler monitoring. *Eur J Vasc Surg* 1994;8:303–308.
- 13 Reith HB, Edelman M, Reith C: Spontaneous intracerebral hemorrhage following carotid endarterectomy: Experience of 328 operations from 1983–1988. *Int Surg* 1992;77:224–225.
- 14 Gossetti B, Martinelli O, Guericchio R, Irace L, Benedetti-Valentini F: Transcranial Doppler in 178 patients before, during, and after carotid endarterectomy. *J Neuroimaging* 1997;7:213–216.
- 15 Kiebertz K, Ricotta JJ, Moxley RT: Seizures following carotid endarterectomy. *Arch Neurol* 1990;47:568–570.
- 16 Andrews BT, Levy ML, Dillon W, Weinstein PR: Unilateral normal perfusion pressure breakthrough after carotid endarterectomy: Case report. *Neurosurgery* 1987;21:568–571.
- 17 Schroeder T, Sillesen H, Sorensen O, Engell HC: Cerebral hyperperfusion following carotid endarterectomy. *J Neurosurg* 1987;6:824–829.
- 18 Baptista MV, Maeder P, Dewarrat A, Bogoslavsky J: Conflicting images: Case reports. *Lancet* 1998;351:414.
- 19 Wells CE: Cerebral embolism. *Arch Neurol Psychiatr* 1959;81:667–677.
- 20 Mohr JP, Caplan LR, Melski JW, Goldstein RJ, Duncan GW, Kistler J, Pessin MS, Bleich HL: The Harvard Co-Operative Stroke Registry: A perspective registry. *Neurology* 1978;28:754–862.
- 21 Cocito L, Favale E, Reni L: Epileptic seizures in cerebral arterial occlusive disease. *Stroke* 1982;13:189–195.
- 22 Nelson M, Bartlett RJ, Lamb JT: Seizures after intravenous contrast media for cranial computed tomography. *J Neurol Neurosurg Psychiatry* 1989;52:1170–1175.
- 23 Fischer HW: Occurrence of seizure during cranial computed tomography. *Radiology* 1980;137:563–564.