

Giant Aneurysm of the Azygos Anterior Cerebral Artery

—Case Report—

Yukihide KANEMOTO, Yoshihiro TANAKA, Masahiro NONAKA,
and Yasuo HIRONAKA

Department of Neurosurgery, Nara Prefectural Gojo Hospital, Gojo, Nara

Abstract

A 77-year-old female presented with a giant aneurysm of the azygos anterior cerebral artery (ACA) manifesting as acute onset of akinetic mutism caused by enlargement of the aneurysm resulting from rapid thrombus formation within the aneurysmal sac. Thrombus removal to obtain decompression of the aneurysmal bulk and tension was performed before parent artery occlusion to prevent thromboembolic events. The aneurysmal neck was completely clipped with preservation of the parent artery and all branches. This strategy for direct neck clipping of a giant thrombosed distal ACA aneurysm can reduce the possibility of ischemic sequelae.

Key words: giant aneurysm, azygos artery, distal anterior cerebral artery, neck clipping

Introduction

Giant aneurysms of the distal anterior cerebral artery (ACA) are extremely rare, with only 10 cases reported.^{1,2,4,5,8-12)} The clinical symptoms at onset vary, in contrast to small aneurysms of the distal ACA which usually manifest as intracranial hemorrhage.⁷⁾ Giant aneurysm of the distal ACA is likely to be misdiagnosed as a space-occupying lesion because of the rarity, radiological findings, and the clinical presentation.^{2,8,10)} Treatment by direct neck clipping may be challenging because of the size, the broad neck, and frequent association with thrombosis of the aneurysmal sac. Neck clipping has been performed in only three cases,^{1,2,4)} but the strategy and detailed technical aspects were not described. Here, we describe direct neck clipping of a giant thrombosed distal ACA aneurysm to reduce ischemic sequelae, and discuss the clinical presentation.

Case Report

A 77-year-old female began to behave bizarrely, and became careless in matters of daily life according to her family 7 days before admission. The patient was rushed to our hospital after suffering acute onset of

consciousness disturbance with urinary incontinence.

The patient exhibited akinetic mutism on admission. Neurological examination 2 days after admission found that the patient could obey simple commands and move all extremities symmetrically following infusion of glycerol, but detailed neurological examination could not be performed because of the patient's akinetic rigidity. Computed tomography (CT) demonstrated a well-demarcated, 5-cm diameter mixed density lesion with slight rim-like enhancement in the frontal interhemispheric fissure, and surrounded by severe edema (Fig. 1). Magnetic resonance (MR) imaging showed a large globoid lesion consisting of two parts (Fig. 2). The dorsal part was hyperintense on both T₁- and T₂-weighted images, which suggested hematoma containing free methemoglobin, whereas the ventral part was inhomogeneously hyperintense on T₁- and inhomogeneously hypointense on T₂-weighted images, which suggested old thrombus containing hemosiderin and flow void signal. Left carotid angiography revealed partial filling of the giant aneurysm, which arose at the point where the azygos artery branched into two pericallosal arteries displaced laterally and posteriorly (Fig. 3).

A bifrontal craniotomy was performed. The dura was opened bilaterally and both the sagittal sinus and falx were incised at the most anterior part. The

Received February 17, 2000; Accepted June 9, 2000

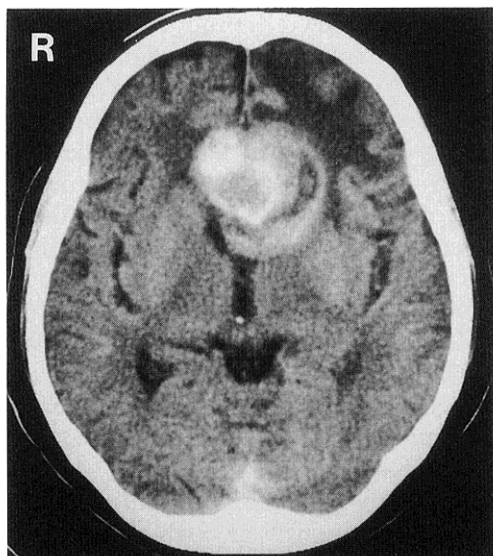


Fig. 1 Computed tomography scan with contrast medium demonstrating a well-demarcated, 5-cm diameters mixed density lesion with slight rim-like enhancement in the frontal interhemispheric fissure, and surrounded by severe edema.

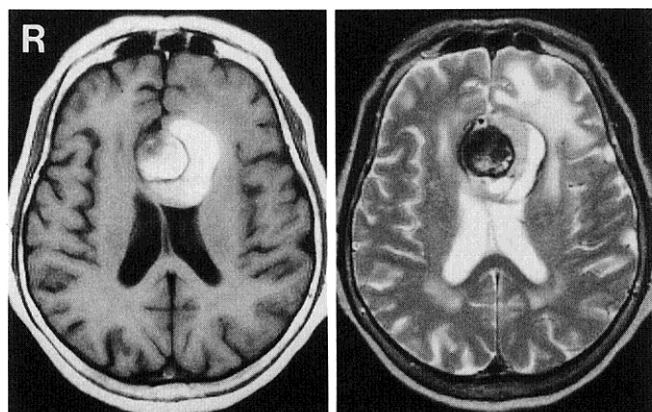


Fig. 2 Magnetic resonance images showing a large globoid lesion consisting of two parts. The lower part was hyperintense on both T_1 - (left) and T_2 -weighted (right) images, which suggested a hematoma containing free methemoglobin, whereas the upper part was inhomogeneously hyperintense on T_1 - and inhomogeneously hypointense on T_2 -weighted images, which suggested old thrombus containing hemosiderin and flow void signal.

interhemispheric fissure was exposed widely. After the azygos artery and bilateral pericallosal arteries were identified, the aneurysmal wall was exposed.

Neurol Med Chir (Tokyo) 40, September, 2000

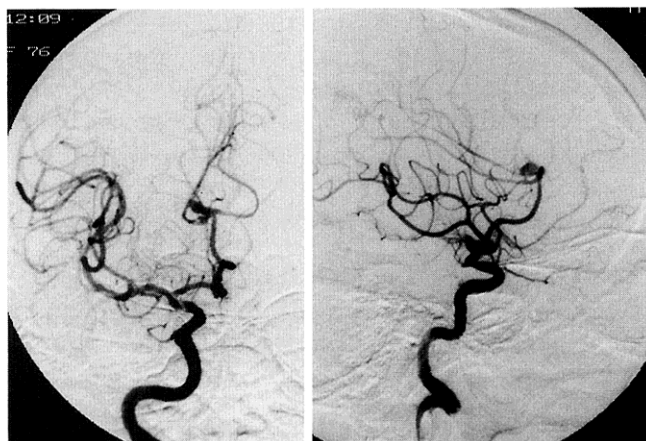

Fig. 3 Left anteroposterior (left) and lateral (right) carotid angiograms revealing partial filling of the giant aneurysm, which arose at the point where the azygos artery branched into two pericallosal arteries displaced laterally and posteriorly.

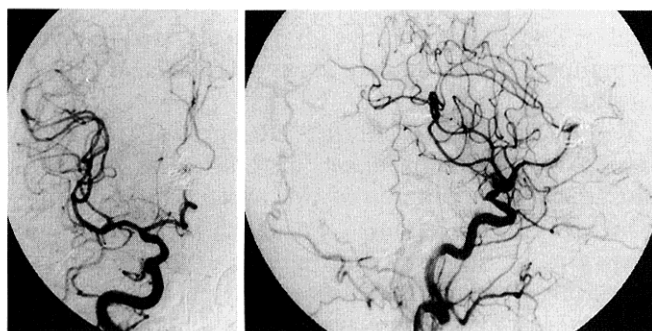


Fig. 4 Postoperative left anteroposterior (left) and lateral (right) carotid angiograms showing complete disappearance of the aneurysm with preservation of all branches.

The aneurysmal sac was opened. At first, only old thrombus far from the patent region of the aneurysm was removed to obtain shrinkage of the sac without temporary occlusion of the parent artery. Temporary occlusion of the parent artery was performed after bleeding occurred. Thrombus near the aneurysmal neck was then completely removed to obtain space for neck clipping. The aneurysmal neck was completely clipped with four types of clips. The aneurysmal sac was subtotally extirpated. The period of temporary occlusion of the parent artery was 10 minutes.

After surgery, the preoperative mutism resolved. Neurological examination 10 days after surgery showed no abnormal findings. Postoperative CT

demonstrated resolution of the frontal edema on both sides. Postoperative carotid angiography showed complete disappearance of the aneurysm with preservation of all branches (Fig. 4). The patient was discharged in excellent condition.

Discussion

The clinical presentation of cerebral giant aneurysms is usually the manifestation of either hemorrhage or chronic mass signs, or rarely thromboembolic ischemia.^{1,3,8)} However, in the 11 reported cases of giant aneurysms of the distal ACA, including our case, clinical symptoms at onset varied, including hemorrhage in three cases,^{1,9,12)} chronic mass signs in two,^{4,8)} thromboembolism from thrombi within the sac in one,⁴⁾ and acute deterioration of mass signs due to a thrombotic event within the aneurysmal sac in five.^{2,5,10,11)} Small aneurysms of the distal ACA usually cause intracranial hemorrhage.⁷⁾ In our case, fresh clot formation continuing from the patent region of the aneurysm was confirmed on MR imaging and during surgery. In particular, MR imaging 4 days after onset indicated clot formation in the subacute stage associated with old thrombus.

The characteristic clinical presentation of these aneurysms is acute onset of clinical symptoms caused by enlargement of the aneurysm resulting from rapid thrombus formation within the aneurysm, which was seen in five of the 11 cases, including our case. This onset pattern lead to misdiagnosis of a giant aneurysm of the distal ACA as a tumor associated with hemorrhage, especially in the case of a completely thrombosed aneurysm.^{2,8,10)}

Direct neck clipping of a giant aneurysm involves two significant problems besides actual clip application: Hemodynamic ischemia during temporary occlusion of the parent artery, because direct neck clipping is usually impossible without decompression of the aneurysmal bulk and tension; and thromboembolic ischemia, because all giant aneurysms of the distal ACA were partially or completely thrombosed. Hemodynamic ischemia can be reduced by shortening the period of temporary occlusion of the parent artery, using various brain protective drugs, induced hypertension, and inherent collateral circulation. In particular, the period of temporary occlusion of the parent artery should be reduced.

Our procedure for direct neck clipping of the thrombosed giant aneurysm was intended to prevent both hemodynamic and thromboembolic ischemia. The temporary clip was applied after the bleeding occurred to shorten the temporary occlusion time.

Moreover, temporary clipping of the parent artery prevented thromboembolic ischemia caused by thrombi within the sac, and allowed assessment of the degree of collateral circulation by retrograde flow via the distal arteries. Tentative clipping of the aneurysmal sac before complete removal of the thrombus near the neck should be avoided to prevent thromboembolic ischemia, even if the parent artery is temporarily occluded.

The tolerance time for temporary occlusion of the distal ACA is obscure, particularly for the azygos artery. The tolerance time for the ACA might be similar to that of the middle cerebral artery (MCA), because flow rates in the distal ACA (120 ml/min) are comparable to those of the MCA.⁶⁾ No new neurological deficits appeared after 45 minutes of occlusion in one patient¹²⁾ or with permanent occlusion of the feeding vessel for giant aneurysms of the distal ACA in three patients (not including cases involving the azygos artery).⁹⁻¹¹⁾ Ten new infarcts, involving perforator territories in seven cases, occurred among 30 cases of direct neck clipping of giant aneurysms of the anterior circulation using temporary clipping of the parent artery.³⁾ However, there was no correlation between infarct and the duration of temporary clipping. We consider that hemodynamic ischemia may be avoided, despite the azygos artery, and may be less important than thromboembolic ischemia if the temporary occlusion time is limited to a reasonable period.

References

- 1) Drake CG: Giant intracranial aneurysms: Experience with surgical treatment in 174 patients. *Clin Neurosurg* 26: 12-95, 1979
- 2) Farias JP, Trindade AM: Giant distal anterior cerebral artery aneurysm not visualized on angiography: case report. *Surg Neurol* 48: 348-351, 1997
- 3) Gewirtz RJ, Awad IA: Giant aneurysms of the anterior circle of Willis: Management outcome of open microsurgical treatment. *Surg Neurol* 45: 409-421, 1996
- 4) Hayashi M, Kobayashi H, Kawano H, Handa Y, Kabuto M: Giant aneurysm of an azygos anterior cerebral artery: Report of two cases and review of the literature. *Neurosurgery* 17: 341-344, 1985
- 5) Maiuri F, Corriero G, D'Amico L, Simonetti L: Giant aneurysm of the pericallosal artery. *Neurosurgery* 26: 703-706, 1990
- 6) Nornes H, Wikeby P: Cerebral arterial blood flow and aneurysm surgery. Part 1: Local arterial flow dynamics. *J Neurosurg* 47: 810-818, 1977
- 7) Ohno K, Monma S, Suzuki R, Masaoka H, Matsushima Y, Hirakawa K: Saccular aneurysms of the distal anterior cerebral artery. *Neurosurgery* 27: 907-913, 1990

- 8) O'Neill M, Hope T, Thomson G: Giant intracranial aneurysms: diagnosis with special reference to computerized tomography. *Clin Radiol* 31: 27-39, 1980
- 9) Pia HW, Zierski J: Giant cerebral aneurysms: Problem in treatment, in Pia HW, Langmaid C, Zierski J (eds): *Cerebral Aneurysms. Advances in Diagnosis and Therapy*. Berlin, Heidelberg, New York, Springer-Verlag, 1979, pp 336-342
- 10) Pozzati E, Nuzzo G, Gaist G: Giant aneurysm of the pericallosal artery. Case report. *J Neurosurg* 57: 566-569, 1982
- 11) Preul M, Tampieri D, Leblanc R: Giant aneurysm of the distal anterior cerebral artery: Associated with an anterior communicating artery aneurysm and a dural arteriovenous fistula. *Surg Neurol* 38: 347-352, 1992
- 12) Smith RR, Parent AD: End-to-end anastomosis of the anterior cerebral artery after excision of a giant aneurysm. Case report. *J Neurosurg* 56: 577-580, 1982

Address reprint requests to: Y. Kanemoto, M.D., Department of Neurosurgery, Nara Prefectural Gojo Hospital, 197 Nohara-cho, Gojo, Nara 637-0034, Japan.