



CASE REPORT

Systemic lupus erythematosus associated with moyamoya syndrome

KM El Ramahi^{1*} and HM Al Rayes¹

¹Department of Medicine, King Faisal Specialist Hospital and Research Centre, Riyadh, Kingdom of Saudi Arabia

Moyamoya disease is an uncommon clinical entity, characterized by bilateral occlusion of the internal carotid artery and the development of collateral arteries. An 18-year-old Saudi male with systemic lupus erythematosus (SLE) presented with mild right hemiparesis, followed by recurrent ischemic stroke. Cerebral angiography showed bilateral internal carotid artery stenosis associated with the development of collateral circulation (moyamoya vessels). There was no evidence of active SLE or other risk factors for cerebral occlusion, such as antiphospholipid antibody syndrome. Medical and surgical interventions did not influence the poor outcome of the recurrent ischemic insults. *Lupus* (2000) 9, 632–636.

Keywords: moyamoya syndrome; systemic lupus erythematosus; ischemic stroke; angiography; papular mucinosis

Introduction

Moyamoya disease is a clinical entity of unknown etiology, characterized primarily by typical angiographic finding of bilateral occlusion of the internal carotid artery, and extensive formation of a collateral vascular network (moyamoya vessels). This disease was first detected in Japanese patients, when Takenchi and Shimizu reported the first angiographic finding of this disease in 1959. Moyamoya syndrome is a term applied to typical moyamoya vessels in the presence of underlying causes like vasculitis, fibromuscular dysplasia, sickle cell disease or others. Transient ischemic attacks (TIAs) or ischemic strokes are the usual presentations in the juvenile group (less than 20 years old), while intracerebral hemorrhage is the usual presentation in adults.

In this paper, we present a young Saudi male patient with systemic lupus erythematosus (SLE) and papular mucinosis who suffered an ischemic stroke. Angiographic studies revealed a typical moyamoya phenomenon.

Case Report

An 18-year-old Saudi male was diagnosed with SLE in May 1998, based on typical malar rash, photosensitivity, symmetrical peripheral arthritis, a positive ANA, high titer anti-ds-DNA, false-positive VDRL, and IgG anticardiolipin antibodies (aCLs) of 30 GPL u/mL (N:0–15). Papulo-macular scattered skin rash was diagnosed as papular mucinosis by skin biopsy. He responded to oral prednisone (10 mg/d) and Plaquenil (200 mg/d) and has done fairly well, with complete recovery of the skin rash and arthritis.

In May 1999, the patient was admitted to our hospital with a one-day history of right side weakness and dysarthria. He had no history of headache, vomiting, seizure, recent memory loss or personality changes, and no history of previous transient ischemic attack or deep vein thrombosis (DVT). History was not suggestive of Sjögren's syndrome or active SLE. He was afebrile with normal blood pressure of 120/70, and a regular pulse of 80/min. There were no carotid bruits, no new skin rash, or livedo reticularis rash.

Examination revealed mild right hemiparesis, with a power of 4/5 in the upper and lower extremities, and brisk reflexes with normal cranial nerves. Systemic examination was otherwise unremarkable.

*Correspondence: K El Ramahi, Consultant Rheumatologist, Department of Medicine (MBC-46), King Faisal Specialist Hospital and Research Centre, P.O. Box 3354, Riyadh 11211, Kingdom of Saudi Arabia.
Tel: (+966) 1 442 7771; Fax: (+966) 1 442 7499.

Laboratory data revealed leukocyte count of $11.9 \times 10^3/\text{mm}^3$, hemoglobin 11.6 gm/dL with hypochromasia and microcytosis, and platelet count of $224 \times 10^3/\text{mm}^3$. Erythrocyte sedimentation rate was 15 mm in 1 h. Renal and hepatic profiles were normal. Antinuclear antibody (ANA) was positive with a titer of 1/320 (speckled pattern), its anti-double stranded DNA (ds-DNA) 437 by ELISA (N:0–28), and SSA titer greater than 2000. Anticardiolipin antibody IgG was 11 GPL U/mL, IgM 6 MPL/U/mL, IgA 5 APL U/mL, and anti-neutrophil cytoplasmic antibodies were within normal limits. Complement C3 0.87 g/L (N:0.8–1.80), C4 0.11 g/L (N:0.2–0.4), CH50 290 u/mL (N:345–485), and circulating immune complexes (CIC) were increased at 28 U by RAJI cell assay (N:0–15). Anti-thrombin III levels, prothrombin time (PT) and activated partial thromboplastin time (PTT) were normal. Lupus anticoagulant and the repeated VDRL were negative. Sickling test was also negative. A chest roentgenogram, electrocardiogram, and echocardiogram revealed no abnormal findings.

Magnetic resonance imaging (MRI) of the brain demonstrated a well-defined abnormality on T1 and T2-weighted images, with a high signal intensity lesion in the cortical location in the left premotor area. The long TR images showed multiple small-scattered white matter lesions within the cerebral hemispheres. There were also dilated transmedullary veins within the periventricular centrum semiovale. Doppler ultrasound of the carotid arteries showed bilateral minimal

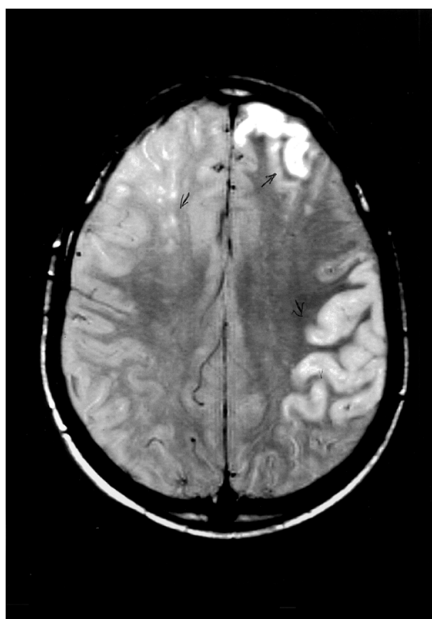


Figure 1 T2-weighted MRI scan shows multiple bilateral cerebral infarcts.

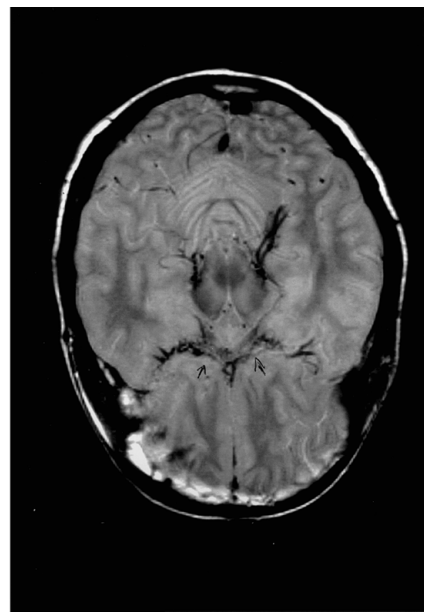


Figure 2 Axial (T2 WI) MRI scan of the brain at the level of circle of Willis shows extensive leptomenigeal vessels (arrow) acting as collateral circulation.

thickening in the upper common carotid artery (CCA), and in the proximal right internal carotid artery. Both vertebral arteries were patent.

A provisional diagnosis of central nervous system (CNS) vasculitis secondary to SLE was made, and treatment with intravenous pulses of methyl prednisolone as well as heparin were given. However, the patient's condition did not improve and in the first 3 days of hospitalization, he further developed upper motor neuron (UMN) lesions with progression of his right-side weakness, mainly the lower extremity, as well as multiple cranial nerve involvement (5th, 6th, 11th and 12th).

MRI study revealed further progression with new lesions in the left posterior, frontal and parietal regions (Figure 1), and a few small punctuate lesions bilaterally within the centrum semiovale. The MRI findings indicated an anterior and middle cerebral artery territory involvement (Figure 2); however, there was no involvement of the brain stem.

Because of the unexplained recurrent ischemic stroke, an angiogram of the carotid arteries was done and showed bilateral severe narrowing of the internal carotid artery at the intracranial portion above the origin of the ophthalmic artery, with prominent leptomenigeal circulation from the posterior circle of Willis. There was also evidence of the development of numerous perforators in the anterior aspect of the circle of Willis, which was compatible with the diagnosis of moyamoya disease (Figure 3).

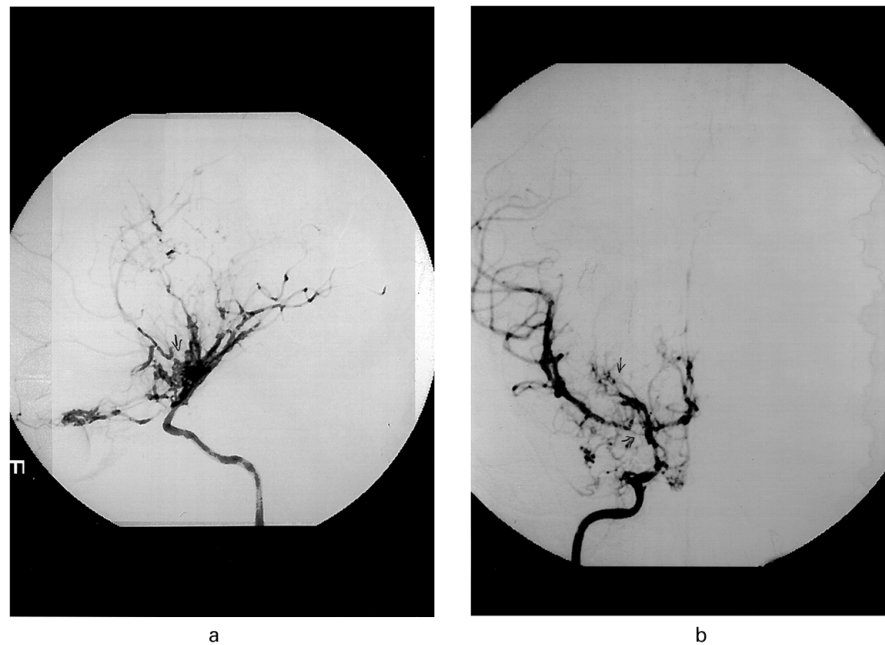


Figure 3 Right internal carotid artery angiogram (anterioposterior and lateral) shows prominent leptomenigeal (moyamoya) vessels with severe narrowing of the internal carotid artery above the ophthalmic artery origin and at bifurcation.

In view of the previous diagnosis of SLE, moderately high IgG aCLs and false-positive VDRL one year before and the presence of the cerebral infarction, the above findings were thought to represent a moyamoya syndrome secondary to anti-phospholipid syndrome, or to SLE vasculopathy rather than a moyamoya disease.

He was treated with anticoagulant, oral prednisone 60 mg/d, and received a 1 g pulse of IV cyclophosphamide. This approach was taken as there were no previously reported cases available in the literature which documented the experience and outcome of surgical treatment in a moyamoya syndrome with SLE. Three weeks after the first cyclophosphamide pulse therapy, the patient was readmitted with a new neurological insult in the form of anomia and alexia. MRI of the brain showed a new infarction. A prophylactic surgery (encephaloarteriosynangiosis) was done on the left side. Postoperatively, the patient was maintained on prednisone 60 mg/d and warfarin. Three weeks later, he was readmitted with acute extradural hematoma at the site of surgery, for which warfarin was held, and the hematoma improved. One week later, right encephaloarteriosynangiosis was done. On the second day postoperatively, he developed a new ischemic stroke which resulted in bilateral hemiplegia with multiple cranial nerve palsies and global aphasia; also, he developed active gastric ulcer for which warfarine was discontinued. He was

discharged home three weeks later on aspirin and tapering dose of prednisone: no further events occurred during a 9-month follow-up.

Discussion

The incidence of cerebrovascular accidents in SLE is about 15%, with most of these strokes occurring within the first five years of illness.¹ Symptomatic large cerebral vessel occlusive disease in SLE usually occurs several years after the initial presentation of SLE and during the active phase of the disease. Poor outcome results in 40% of the cases, while the recurrent stroke rate is 13%.² However, CNS involvement in SLE may occur without evidence of disease activity elsewhere in about 50% of the cases.

Moyamoya disease is an uncommon clinical entity of a chronic non-inflammatory occlusive vasculopathy of internal carotid arteries of unknown etiology.⁴ Moyamoya is a Japanese word that means 'something hazy like a puff of cigarette smoke drifting in the air.' Suzuki⁵ coined this term in 1969 for the peculiar angiographic pattern of an abnormal wispy-like network of vessels at the base of the brain seen in patients with the disorder.

Angiographic criteria for a definite case are: stenosis or occlusion at the terminal portion of the internal carotid artery and at the proximal portion of

the anterior and middle cerebral arteries, abnormal vascular network seen in the arterial phase in the vicinity of the arterial occlusion, and bilateral involvement.⁶

Our patient had moderately elevated IgG aCLs and false-positive VDRL during his initial presentation, but no features of antiphospholipid antibody clinical syndrome including livido reticularis. At the time of infarction, he had normal levels of anticardiolipin antibodies and negative VDRL, and in view of the fact that antibodies aCL may have been consumed during the thrombotic events, therefore moyamoya vasculopathy secondary to antiphospholipid syndrome would not be ruled out. Alternatively the elevated aCLs may represent a hyperimmune reaction during active SLE. The typical angiographic features of moyamoya in this setting favors the diagnosis of moyamoya syndrome secondary to SLE.

Review of the literature revealed case reports of associated moyamoya syndrome with other autoimmune diseases.⁷ The etiology of moyamoya disease has not yet been fully elucidated. Fujiwara *et al*⁸ reported a case of recurrent TIA and unilateral moyamoya vessels in the presence of lupus anticoagulant. Matsuki *et al*⁹ reported the first case of SLE and Sjögren's syndrome associated with unilateral moyamoya vessels in cerebral arteries, in the absence of antiphospholipid syndrome, but the angiographic features were unilateral in that report. To the best of our knowledge, our patient represents the first typical case of bilateral moyamoya vessels in a patient with an established diagnosis of SLE. Furthermore, our patient had another unusual skin manifestation, namely papular mucinosis at his initial presentation.

A high incidence of positive ANA and/or anti-DNA has been recognized in patients with moyamoya disease compared to normal controls.¹⁰ Anti-Ro/SSA antibodies in the serum and cerebrospinal fluid were reported in association with a diffuse cerebral vasculopathy compatible with moyamoya disease, but without any clinical evidence of SLE or Sjögren's syndrome. Interestingly, high titers of anti-Ro/SSA antibodies were detected on two occasions in our patient without any clinical evidence of Sjögren's syndrome. Four other patients with SLE and Sjögren's syndrome who were positive for anti-Ro/SSA antibodies were identified through a literature search.^{11,12} They developed vasculitis involving medium to large-sized arteries.

Revascularization surgery for moyamoya patients is believed to prevent cerebral ischemic attacks by improving cerebral blood flow.¹³ The choice of surgical procedure in our patient was a prophylactic encephaloarteriosynangiosis in which the tempoalis muscle along with its blood supply was placed on the

exposed cerebral cortex to increase cerebral vascularization. A five-year follow-up study of 628 patients by Yonekawa¹⁴ showed that, although the outcome seemed more favorable in the surgically treated patients compared with the conservatively treated patients, it did not reach statistical significance. This suggests that there is a need to define the criteria for patient selection for surgical treatment in moyamoya disease, especially if an underlying condition is suspected.

In conclusion, we present an unusual association of SLE with a typical moyamoya syndrome in a young patient who developed recurrent ischemic attacks and who failed to respond to medical and surgical intervention. Moyamoya syndrome in association with SLE should be considered in the differential diagnosis of cerebrovascular events in patients with systemic lupus erythematosus.

Acknowledgements

The authors would like to thank Dr Jehad Al Watban, neuroradiologist, for his valuable assistance in performing and in the interpretation of the angiographic studies, and Miss Evelyn C Dinio for typing this manuscript.

References

- 1 Futrell N, Millikan C. Frequency, etiology, and prevention of stroke in patients with systemic lupus erythematosus. *Stroke* 1989; **20**: 583–591.
- 2 Mitsias P, Levine SR. Large cerebral vessel occlusive disease in SLE. *Neurology* 1994; **44**: 385–393.
- 3 Toubi E, Khamashta M, Panarra A, Hughes G. Association of antiphospholipid antibodies with central nervous system disease in SLE. *Am J Med* 1995; **99**: 397–401.
- 4 Garg BP, Bruno A, and Biller J. Moyamoya disease and cerebral ischemia. In: Batjer HH (ed). *Cerebrovascular Disease*. Lippincott-Raven: Philadelphia, 1997, pp 489–499.
- 5 Suzuki J, Takaku A. Cerebrovascular moyamoya disease showing abnormal netlike vessels in base of brain. *Arch Neurol* 1969; **20**: 288–299.
- 6 Kitamura K, Fukui M, Oka K. Moyamoya disease. In: Toole JF. *Vascular Diseases*. In: Vinken PJ, Bruyn GW, Klawans HL, (ed). *Handbook of Clinical Neurology*, vol 11. Elsevier: New York, 1989, pp 293–306.
- 7 Fukui M. Diagnostic guidelines for spontaneous occlusion of the Circle of Willis ('Moyamoya' disease). In: Fukui M, (ed). *Annual Report (1995) of the Research Committee on Spontaneous Occlusion of the Circle of Willis ('Moyamoya' Disease) of the Ministry of Health and Welfare, Japan* (in Japanese), 1996, pp 143–166.
- 8 Fujiwara S, Miyazono M, Tsuda H, Fukui M. Intraventricular hemorrhage and cerebral ischemic attacks in the presence of lupus anticoagulant mimicking moyamoya disease. *J Neurosurg Sci* 1993; **37**: 161–164.
- 9 Matsuki Y, Kawakami M, Ishizuka T *et al*. SLE and Sjögren's syndrome associated with unilateral moyamoya vessels in cerebral arteries. *Scand J Rheumatol* 1997; **26**: 392–394.
- 10 Wanifuchi H, Kagawa M, Takeshita M *et al*. Auto-immune antibody in moyamoya disease (in Japanese). *Neurosurgery* 1986; **14**: 31–35.

- 11 Provost TT, Moses H, Morris EL *et al.* Cerebral vasculopathy associated with collateralization resembling moyamoya phenomenon and with anti-Ro/SSA and anti-La/SSB antibodies. *Arthritis Rheum* 1991; **34**: 1052–1055.
- 12 Alexander EL, Craft C, Provost TT *et al.* Necrotizing arteritis and spinal sub-arachnoid hemorrhage in Sjögren's syndrome. *Ann Neurol* 1982; **11**: 632–635.
- 13 Yoshida Y, Yoshimoto T, Shirane R, Sakurai Y. Clinical course, surgical management, and long-term of moyamoya patients with rebleeding after an episode of intracerebral hemorrhage: an extensive follow-up study. *Stroke* 1999; **30**: 2272–2276.
- 14 Yonekawa Y. Summary report of the research committee on spontaneous occlusion of the circle of willis (moyamoya disease) (1988–1992). In: Yonekawa Y, (ed). *1992 Annual Report of the Research Committee on Spontaneous Occlusion of the Circle of Willis (Moyamoya Disease)*. Japanese Ministry of Health and Welfare: Tokyo, 1992, pp 1–11.