

Acute Hemiplegia Associated With Herpes Zoster Infection in Children: Report of One Case

Pei-Yin Hung, MD, Wang-Tso Lee, MD, and Yu-Zen Shen, MD

Herpes zoster infection has been rarely reported to cause angiitis of the central nervous system in children. We describe a 4-year, 8-month-old female with acute hemiplegia and central facial palsy 6 weeks after she had had zoster ophthalmicus. The findings of magnetic resonance angiography, the clinical picture, and a preceding history of herpes zoster ophthalmicus suggested zoster vasculitis. Herpes zoster vasculitis is thus another consideration when examining a child with acute hemiplegia and a recent herpes zoster infection.
© 2000 by Elsevier Science Inc. All rights reserved.

Hung P-Y, Lee W-T, Shen Y-Z. Acute hemiplegia associated with herpes zoster infection in children: Report of one case. *Pediatr Neurol* 2000;23:345-348.

Introduction

Strokes in children may be associated with hemorrhage, thromboembolism, cardiac disease, infection, and vasculitis [1-3]. Among these, infection has been underreported as an important and treatable cause of stroke. Strokes in children have been described in infectious cerebral vasculitis associated with mycoplasma pneumonia, coxsackievirus A9, rubella, measles, enterovirus, and human immunodeficiency virus infection [1-3]. In addition, acute hemiplegia secondary to central nervous system (CNS) angiitis has also been reported in herpes simplex virus or

varicella zoster virus (VZV) infection [3-5]. In strokes associated with VZV infection, the neurologic deficits may develop several weeks after the infection, or, rarely, they may occur days or weeks after herpes zoster ophthalmicus as a result of virus reactivation [3-8]. However, VZV-associated cerebral vasculitis has rarely been reported in children [4-8].

We describe a 4-year, 8-month-old female who presented with acute hemiplegia and central facial palsy 6 weeks after she had had zoster ophthalmicus. The hemiplegia improved gradually without special treatment.

Case Report

A previously healthy 4-year, 8-month-old female was admitted to our hospital because of progressive right-sided weakness of 3 days' duration. Six weeks before admission, she had experienced headache, vesicles over the left side of the face, and swelling over her left eye to such an extent that she could not open her eye. Herpes zoster of the ophthalmic branch of the left trigeminal nerve was diagnosed, and she received oral and topical medication from the local dermatology and ophthalmology clinics. The lesions slowly regressed before admission to our hospital, at which time only pigmented scarring of her supraorbital area remained. Three days before admission, she was observed to have mouth angle deviation to the left side and frequent drooling. A mild fever up to 38.5°C, lethargy, and poor activity developed later. Because of her right-hand weakness, right-foot dragging, diminished speaking, and frequent hiccups on the morning of admission, she was brought to our hospital for additional evaluation.

On admission, the child was alert with slightly slurred speech. The physical examination revealed some pigmented scars in the ophthalmic division of the left trigeminal nerve. Her neck was supple. Her heartbeat was regular without murmur. Her abdomen was soft, with the liver and spleen normal in size. The neurologic examination disclosed isocoric pupils with a normal light reflex. Her eye movements were full and free without nystagmus. A flattening of the right nasolabial fold and deviation of mouth angle to the left when laughing suggested right-sided central-type facial palsy. Her other cranial nerves were grossly intact. Her muscle power was diminished in the right-side extremities. Babinski's sign was positive over the right lower extremity. No truncal ataxia or tremor was evident. However, a circumduction gait was prominent when she walked. Routine laboratory and coagulation studies, including prothrombin time, activated partial thromboplastin time, antithrombin III, protein C, and protein S, were normal. Cardiac echography revealed no vegetation or thrombosis. Lumbar puncture exhibited crystal clear fluid with a cell count of 12 lymphocytes and three neutrophils and normal protein and glucose levels. Cerebrospinal fluid (CSF) cultures for bacteria and virus were negative. The serologic examination demonstrated equivocal anti-VZV IgM. However, the anti-VZV IgG was positive in the serum, with a titer of 1:128; it was negative in the CSF. Electroencephalography revealed diffuse cerebral dysfunction over the left hemisphere. Cranial computed tomography demonstrated several hypodense lesions over the

From the Department of Pediatrics; National Taiwan University Hospital; Taipei, Taiwan.

Communications should be addressed to:
Dr. Lee; Department of Pediatrics; National Taiwan University Hospital; 7, Chung-Shan South Road, Taipei, Taiwan.
Received January 24, 2000; accepted June 14, 2000.

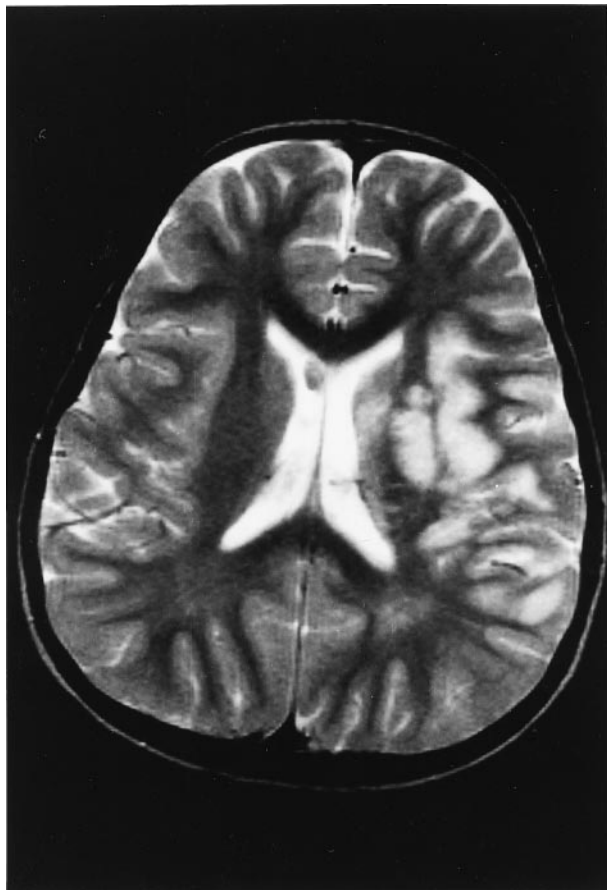


Figure 1. Magnetic resonance image (T_2 -weighted image, TE = 90 ms, TR = 3,506 ms) demonstrating increased signal intensity over the left putamen, left globus pallidus, left insular region, left frontal lobe, and the parietal area.

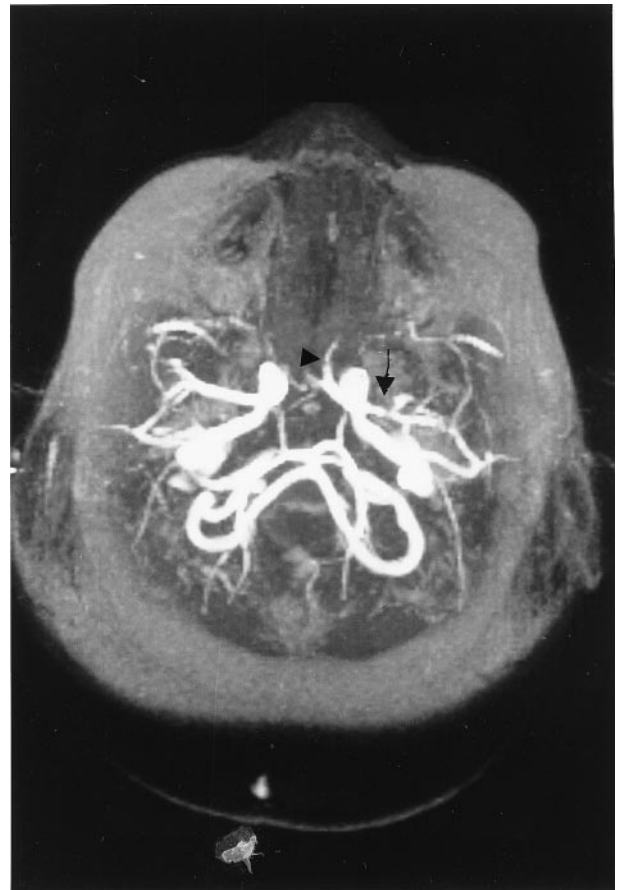

Figure 2. Magnetic resonance angiography revealing an irregularly narrow flow signal in the left proximal middle cerebral artery (arrow) with a compensatory increased flow signal in the left anterior cerebral artery (arrowhead).

left basal ganglion and peripheral areas of the left parietal lobe. Magnetic resonance imaging exhibited T_2 -weighted prolongation at the left putamen, left globus pallidus, left insular region, left frontal, and the parietal areas (Fig 1). Magnetic resonance angiography (MRA) revealed an irregularly narrow flow signal in the left proximal middle cerebral artery, indicating cerebral vasculitis (Fig 2). A transcranial Doppler study of the intracranial vessels yielded decreased blood flow in the left middle cerebral artery, compatible with segmental stenosis of the proximal middle cerebral artery.

The patient was administered low-dose aspirin to prevent stroke recurrence during her hospital stay. A rehabilitation program was arranged. The hemiparesis improved considerably during the next 10 days, but impaired fine motor function of the right hand, a dropped right shoulder, and slurred speech persisted.

Discussion

This patient is a young female child with a clinical picture and MRA findings consistent with herpes zoster-associated CNS vasculitis. Although the titer of anti-VZV antibodies in the CSF was not significantly raised, a preceding history of contralateral herpes zoster ophthal-

micus and typical findings on MRA suggested zoster vasculitis.

VZV infection, either chickenpox or zoster, has been proved to cause CNS vasculitis [4-15]. Although herpes zoster-associated vasculitis has not been uncommon in the past, most patients have had systemic malignancies or are otherwise elderly or immunocompromised [5,9]. The occurrence of cerebral vasculitis after zoster infection in previously healthy children has rarely been reported (Table 1) [6-8]. As in the present patient, the typical clinical history in most patients with herpes zoster-associated cerebral vasculitis is a gradual resolution of cutaneous herpes zoster ophthalmicus followed by the acute onset of contralateral hemiparesis, hemisensory disturbance, or aphasia [5,9,11]. The latent periods may last from days to months, but usually last for 3-4 weeks. The most common finding in the CSF is a mononuclear pleocytosis, which is related to the timing of the sampling. Although the titer was not elevated in the present patient, a raised CSF VZV antibody titer may aid in the diagnosis of CNS involvement [4,5,8]. Conventional cerebral angiography or MRA in patients with herpes zoster vasculitis mainly reveals

Table 1. Varicella zoster virus-associated strokes in children

Reference	Age/Sex	Latency after HZO	CNS Signs	Cranial Imaging	Arteriography	Treatment
Walker et al. [6]	7 yr/male	6 mo	Right hemiplegia, dysphagia	Tc99m brain scan: a triangular-shaped area of increased activity in the L frontoparietal area	Stasis and segmental narrowing of MCA and ACA	Not mentioned
Leis et al. [7]	1 yr, 5 mo/male	4 wk	Right hemiplegia, central facial palsy	Cranial CT: Multiple infarcts in the left internal capsule, caudate nucleus, and frontoparietal areas	Decrease in the number of lenticulostriate arteries from the proximal left MCA	Acyclovir
Francois et al. [8]	4 yr, 6 mo/female	9 wk	Right hemiplegia, aphasia, and decreased consciousness level	Cranial CT: Infarcts in the left internal capsule	Not mentioned	Acyclovir, prednisolone
Present case	4 yr, 8 mo/female	6 wk	Right hemiplegia, central facial palsy, and slurred speech	Cranial MRI: Infarcts in the left putamen, globus pallidus, and frontoparietal areas	Irregular narrowing of left MCA	Low-dose aspirin

Abbreviations:
ACA = Anterior cerebral artery
CNS = Central nervous system
CT = Computed tomography
HZO = Herpes zoster ophthalmicus
MCA = Middle cerebral artery
MRI = Magnetic resonance imaging

segmental narrowing of the proximal middle or anterior (or both) cerebral arteries (Fig 2). The internal carotid artery, basilar artery, posterior cerebral arteries, and small distal vessels are less involved [6,12]. Mackenzie et al. [12] proposed a characteristic angiographic appearance of herpes zoster vasculitis as single or multiple smooth-tapered segmental narrowings of the vessels in the ipsilateral side of cutaneous lesions, as demonstrated in the present patient. However, the opposite side and the extracranial carotid artery are not involved [12].

Several possible explanations for the cerebral vasculopathy associated with herpes zoster infection have been suggested [6,9,10,13-15]. Direct passage of the virus along the intracranial branches of the trigeminal nerve may lead to cerebral vascular thrombosis with neurologic deficits [9,15]. A direct local spread of the virus from the trigeminal ganglion into the corticospinal tract is another possibility [13]. Moreover, the inflammatory process might spread from the gasserian ganglion through the ipsilateral subarachnoid spaces, leading to cerebral vasculitis [6]. Although the pathways are different, virus-like particles and viral antigens have been demonstrated in the arterial wall in previous studies [9,14,15]. Therefore, direct viral invasion into the arterial wall, rather than hematogenous dissemination, may be one possible mechanism of cerebral vasculitis.

VZV-associated vasculitis has been treated with acyclovir, corticosteroid, aspirin, or immunosuppression agents. However, treatment with these medications does not noticeably alter the clinical course, and their effect is still controversial [5,9,11,12]. Cerebral vasculopathy caused by VZV infection has a low mortality rate unless in an immunocompromised host [5,9]. The motor deficits in our patient gradually improved after rehabilitation without acyclovir treatment. Varicella zoster-associated vasculitis seems to be another consideration when examining a child with acute hemiplegia and recent herpes zoster infection. An early diagnosis can avoid unnecessary investigations and treatment and will be helpful in the prediction of outcome in children with stroke.

References

- [1] Michael J, Joseph J. Strokes in children. *Pediatr Rev* 1996;17:265-78.
- [2] Peter C, Carrol B, Holly S. Etiology of pediatric ischemic strokes. *Am J Emerg Med* 1997;15:671-9.
- [3] Gold AP, Carter S. Acute hemiplegia in infancy and childhood. *Pediatr Clin North Am* 1976;23:413-33.
- [4] Yilmaz K, Caliskan M, Akdeniz C, Aydinli N, Karabocuoglu M, Uzel N. Acute childhood hemiplegia associated with chickenpox. *Pediatr Neurol* 1998;18:256-61.
- [5] Hilt DC, Buchholz D, Krumholz A, Weiss H, Wolinsky JS. Herpes zoster ophthalmicus and delayed contralateral hemiparesis caused by cerebral angiitis: Diagnosis and management approaches. *Ann Neurol* 1983;14:543-53.
- [6] Walker RJ, Gammal TE, Allen MB. Cranial arteritis associated with herpes zoster: Case report with angiographic findings. *Radiology* 1973;107:109-10.
- [7] Leis AA, Butler IJ. Infantile herpes zoster ophthalmicus and

acute hemiparesis following intrauterine chickenpox. *Neurology* 1987; 37:1537-8.

[8] **Francois P**, Bost C, Pavese P, Bost M. Herpes zoster ophthalmicus with delayed contralateral hemiplegia. *Pediatr Infect Dis* 1996;15: 471-2.

[9] **Gray F**, Belec L, Lescs MC, Chretien F, Ciordi A, Hassine D, Flament-Saillour M, de Truchis P. Varicella-zoster virus infection of the central nervous system in the acquired immune deficiency syndrome. *Brain* 1994;117:987-97.

[10] **Acer TE**: Herpes zoster ophthalmicus with contralateral hemiplegia. *Arch Ophthalmol* 1964;71:371-6.

[11] **Bourdette DN**, Rosenberg NL, Yatsu FM. Herpes zoster

ophthalmicus and delayed ipsilateral cerebral infarction. *Neurology* 1983;33:1428-32.

[12] **Mackenzie RA**, Forbes GS, Karnes WE. Angiographic findings in herpes zoster arteritis. *Ann Neurol* 1981;10:458-64.

[13] **Cope S**, Jones AT. Hemiplegia complicating ophthalmic herpes zoster. *Lancet* 1954;2:898-9.

[14] **Linneman CC**, Alvira MM. Pathogenesis of varicella-zoster angiitis in the CNS. *Arch Neurol* 1980;37:239-40.

[15] **Eidelberg D**, Sotrel A, Horoapain DS, Neumann PE, Pumarola-Sune T, Price RW. Thrombotic cerebral vasculopathy associated with herpes zoster. *Ann Neurol* 1986;19:7-14.