

tions have a widespread geographic distribution and can result in various phenotypes. These characteristics seem to contrast with those of other coding mutations of tau.

### Acknowledgment

The authors thank Miyuki Obana for excellent technical assistance.

### References

1. Goedert M, Crowther RA, Spillantini MG. Tau mutations cause frontotemporal dementias. *Neuron* 1998;21:955–958.
2. Hong M, Zhukareva V, Vogelsberg-Ragaglia V, et al. Mutation-specific functional impairments in distinct tau isoforms of hereditary FTDP-17. *Science* 1998;282:1914–1917.
3. D'Souza I, Poorkaj P, Hong M, et al. Missense and silent tau gene mutations cause frontotemporal dementia with parkinsonism-chromosome 17 type, by affecting multiple alternative RNA splicing regulatory elements. *Proc Natl Acad Sci USA* 1999;96:5598–5603.
4. Yasuda M, Kawamata T, Komure O, et al. A mutation in the microtubule-associated protein tau in pallido-nigro-luysian degeneration. *Neurology* 1999;53:864–868.
5. Mirra SS, Murrell JR, Gearing M, et al. Tau pathology in a family with dementia and a P301L mutation in tau. *J Neuro-pathol Exp Neurol* 1999;58:335–345.
6. Bugiani O, Murrell JR, Giaccone G, et al. Frontotemporal dementia and corticobasal degeneration in a family with a P301S mutation in tau. *J Neuropathol Exp Neurol* 1999;58:667–677.
7. Poorkaj P, Bird TD, Wijsman E, et al. Tau is a candidate gene for chromosome 17 frontotemporal dementia. *Ann Neurol* 1998;43:815–825.
8. Wszolek ZK, Pfeiffer RF, Bhatt MH, et al. Rapidly progressive autosomal dominant parkinsonism and dementia with pallido-ponto-nigral degeneration. *Ann Neurol* 1992;32:312–320.
9. Sperfeld AD, Collatz MB, Baier H, et al. FTDP-17: an early-onset phenotype with parkinsonism and epileptic seizures caused by a novel mutation. *Ann Neurol* 1999;46:708–715.
10. Nasreddine ZS, Loginov M, Clark LN, et al. From genotype to phenotype: a clinical pathological, and biochemical investigation of frontotemporal dementia and parkinsonism (FTDP-17) caused by the P301L tau mutation. *Ann Neurol* 1999;45:704–715.

---

## Cortical reafferentation following left subcortical hemorrhage: A serial functional MR study

**Article abstract**—A 48-year-old patient who had aphasia due to a left subcortical hemorrhage underwent three follow-up examinations to assess MR signal changes accompanying recovery. A word classification task was applied. During the 6-month follow-up period, we observed a dynamic change from negative toward positive blood oxygenation level-dependent MR signals, i.e., task-related reafferentation of eloquent cortices occurred. Clinical improvement from aphasia paralleled the MR signal changes.

NEUROLOGY 2000;55:1227–1230

M. Hund-Georgiadis, MD; U. Lex; D.G. Norris, PhD; and D.Y. von Cramon, MD, PhD

---

Numerous approaches have been used to study the functional patterns underlying recovery of language function in patients with aphasia.<sup>1,2</sup> The functional transfer to the usually subdominant right hemisphere and adjacent left hemispheric cortices during the recovery period is still under debate.<sup>2</sup> So far, mainly PET and functional MRI (fMRI) have been used to deliver functional maps of speech (re)organization during language tasks in aphasic patients, which can readily be considered as “snapshots” taken at a certain time after stroke onset. However, these snapshots reveal little about the dynamics and the time window of reorganization, and little about the relationship between clinical improvement from aphasia and accompanying changes in functional patterns. The current fMRI study investigated regional blood oxygenation level-dependent (BOLD) signal changes accompanying recovery from stroke

in a 48-year-old patient. During a time interval of 6 months, the patient was examined three times to deliver a functional follow-up of speech reorganization post acute stroke and to study the role of non-dominant cortices in the process of recovery.

**Patient and methods.** *Case report.* A 48-year-old right-handed patient had transcortical sensory aphasia and right spastic hemiparesis due to left hemispheric hypertensive hemorrhage. T1-weighted MRI 2 months after hemorrhage onset revealed complete necrosis involving the posterior putamen, the subinsular white matter, the posterior limb of the internal capsule, the posterolateral thalamus, and the posterior corona radiata. No relevant brain edema, midline shift, or compression of surrounding structures were present. A severely decreased regional cerebral blood flow (rCBF) of the entire left hemisphere was evident on ECD-SPECT, 2 months after onset. The patient gave his informed consent to participate in the follow-up fMRI study. Examinations included three sessions as well as behavioral examinations (see below) 2, 5, and 8 months after stroke onset.

*Behavioral testing.* Aphasia was formally assessed and classified using the Aachen Aphasia Test (AAT).<sup>3</sup> Handedness was assessed based on the Edinburgh Handedness

---

From the Max-Planck-Institute of Cognitive Neuroscience, Leipzig, Germany. Received March 6, 2000. Accepted in final form June 21, 2000.

Address correspondence and reprint requests to Dr. Margret Hund-Georgiadis, Max-Planck-Institute of Cognitive Neuroscience, Stephanstr. 1, 04103 Leipzig, Germany; e-mail: hund@cns.mpg.de

**Table** Results on the Aachen Aphasia Test (AAT) during recovery from stroke between 2 and 8 months after disease onset

Duration*	Spontaneous speech rating scales						Subtests (normative test scores)				
	COM	ART	AUT	SEM	PHO	SYN	TT	REP	WRIT	NAME	COMP
2	2	4	3	2	2	3	27 (0–2)	148 (148–150)	62 (87–90)	45 (112–120)	62 (110–120)
5	3	3	3	3	4	4	15†	149	71	68†	92†
8	3	4	4	4	4	3	10†	147	81†	92†	94†

The AAT consists of six six-point spontaneous speech rating scales (COM = communicative behavior; ART = articulation and prosody; AUT = automatized language; SEM = semantic structure; PHO = phonologic structure; SYN = syntactic structure) and five subtests (TT = token test; REP = repetition; WRIT = written language; NAME = confrontation naming; COMP = comprehension), in which different units (phonemes, monosyllabic and polysyllabic nouns, sentences) and linguistic rules are incorporated. The patient's results and the normative test scores are shown.

\* Interval (mo) between disease onset and time of aphasia testing.

†  $p < 0.05$ , Student's  $t$ -test for paired samples; comparisons refer to the first AAT, which was performed 2 months postonset.

Inventory (88% right-handedness/range  $\pm 100\%$ ; positive values indicate right-handedness, negative ones left-handedness).

**Functional MRI.** A semantic encoding task was employed during the fMRI studies. This was established in a normal control study of 14 age-matched right-handed subjects within our own laboratory and in previous fMRI research.<sup>4</sup> The studies reported activation of the inferior frontal gyrus (IFG) (the pars triangularis and pars orbitalis) and neighboring orbital cortex corresponding to portions of Brodmann areas 45, 46, and 47 associated with this paradigm. Common German words composed of two syllables (four to seven letters long) were visually presented every 2 seconds. The words were either abstract or concrete. The subject had to judge whether a presented word was abstract or concrete and respond by pressing a button. Reaction times and the number of errors were recorded on line. During the baseline condition the patient had to fixate the center of a dark desktop. Prior to each functional session a training test determined the patient's ability to solve the task in the MR scanner. fMRI recording was performed on a 3-T whole body system (Medspec 300/100, Bruker, Ettlingen, Germany) using echoplanar imaging (seven axial slices, 7-mm slice thickness; echo time [TE], 30 msec; repetition time [TR], 2 seconds; matrix, 128  $\times$  64; field of view, 25 cm). fMRI data were analyzed with in-house brain image analysis (BRIAN) software.<sup>5</sup> Preprocessing included movement correction in two dimensions and baseline correction. Small body movements were corrected by registering images in the time series using two translational and one rotational parameter.

Functional images were created by generating statistical  $z$  maps with  $z$  values  $>5$  on a single pixel level. For better visualization, the functional patient and normal control data were transferred onto the individual three-dimensional datasets. To coregister the fMRI slices, so-called registration matrices were computed for every data set. These matrices contain rotational and translational parameters that can be used for coregistration. The registration matrices were normalized, i.e., transformed by a linear scaling to a standard size, and applied to the fMRI slices. The output data sets were geometrically aligned with a three-dimensional reference T1 data set using trilinear interpolation.<sup>6</sup> For statistical comparisons in between sessions, Student's  $t$ -test for paired samples was used.

**Results. Behavioral tests.** During the time course of recovery the patient achieved a significant improvement in all AAT subtests that had initially shown impairment. The table summarizes the results of the AAT. An initially severe transcortical sensory aphasia was classified as amnesic in the last AAT control.

**Functional MRI.** Semantic encoding in the normal control group was associated with activation, i.e., task-related positive BOLD MR signal changes in the left inferior and middle frontal gyrus (Talairach coordinates:  $-42$  11 27) and the anterior insula (Talairach coordinates:  $-37$  20 6). Other eloquent cortical areas such as the superior temporal gyrus were not significantly activated. However, a negative BOLD MR signal change occurred in the pars triangularis and the posterior part of the superior temporal gyrus (Wernicke's area) of the subdominant right hemisphere (figure, A). Analysis of performance during the MR session showed mean reaction times of  $713 \pm 85$  msec, with an error rate of 17%.

Interesting functional patterns were found in the serial patient study. fMRI data analysis of the first session showed an extended task-related negative BOLD MR signal change in the left hemispheric frontolateral IFG (pars triangularis and pars orbitalis) during semantic encoding. At the same time, a task-related positive BOLD effect was present in the superior temporal gyrus of the right hemisphere and less extensive in the right IFG, indicating a transfer of task-related activation to the right hemisphere. In the second follow-up, the negative BOLD signal change of the left eloquent cortices was decreased and occurred in the superior and middle temporal gyrus of the right hemisphere instead. However, a positive BOLD effect was present in the left superior temporal gyrus extending to Wernicke's area and in the right pars triangularis (Broca's area). In the last functional session, the negative BOLD response had further decreased. The activation patterns now resembled those of the normal control subjects. Activation was present in the left and right pars triangularis. However, in addition to the control results, activation was found in the left superior temporal gyrus as well. The figure shows the blood flow-related MR signal changes occurring in the three follow-up examinations. The following performance data were assessed during the MR sessions. Mean latencies of  $1100 \pm 313$  msec and an error rate of 38% indicated severe problems with solving the task

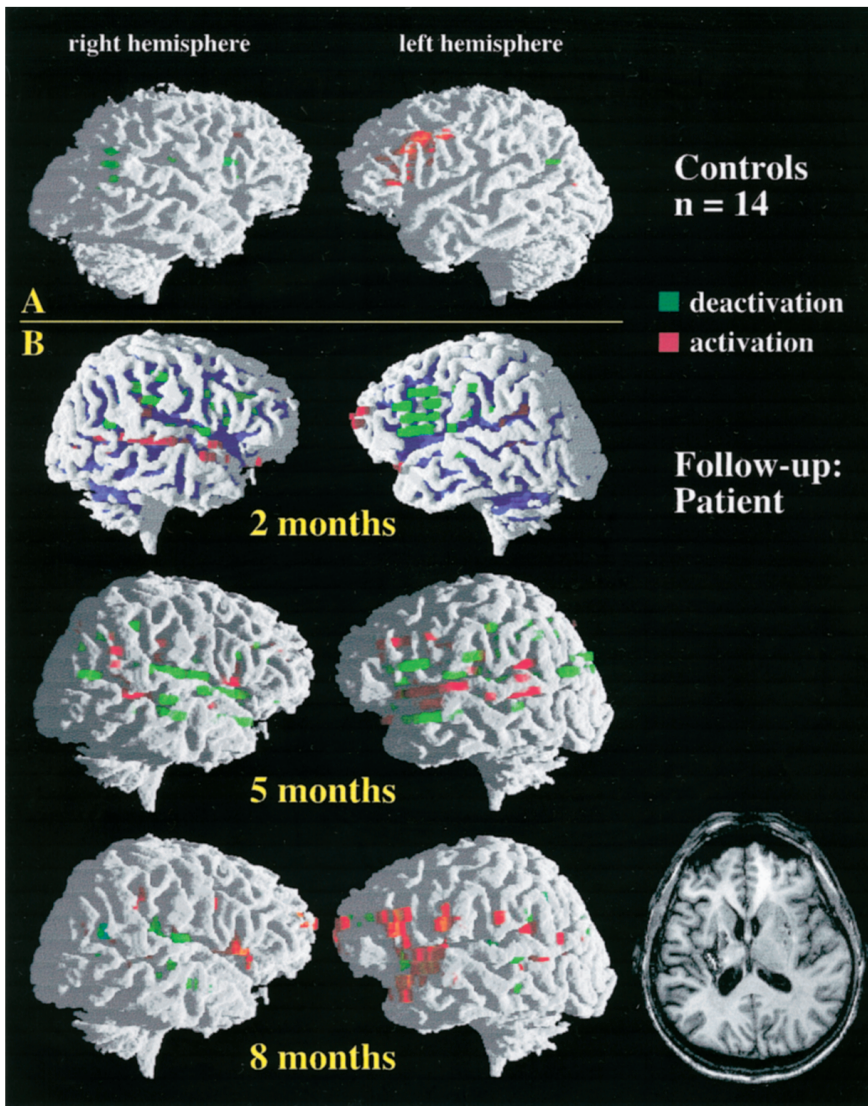


Figure. (A) Functional activation patterns of 14 right-handed control subjects during semantic encoding. Functional images were created by generating statistical z maps with z values  $>5$  on a single pixel level. Group data were normalized, averaged, and displayed on a reference three-dimensional dataset. (B) Follow-up of a 48-year-old patient who had hemorrhage in the left putamen and claustrum. T1-weighted MRI (axial plane) shows the subcortical left hemispheric lesion (natural convention) 2 months after hemorrhage onset. No relevant brain edema, midline shift, or compression of surrounding structures were present. Functional MRI recordings were performed 2, 5, and 8 months after onset. The data of each session are displayed onto the patient's three-dimensional dataset. A decrease of the MR blood oxygenation level-dependent (BOLD) signal (green) and its re-increase (red) in the left inferior frontal gyrus were the main functional patterns during recovery, accompanied by additional activation of the left superior temporal gyrus.

during the initial session. However, statistical analysis of behavioral data guaranteed a performance beyond chance level ( $p < 0.005$ ,  $\chi^2$  test). An improvement occurred during the follow-up:  $977 \pm 201$  msec latency and 32% error rate in the second session and  $811 \pm 188$  msec latency and 21% error rate in the third session. A significant difference (Student's *t*-test for paired samples) was assessed between the first and the last session. Moreover, the patient's performance during the last session did not significantly differ from the control subjects.

**Discussion.** There is evidence<sup>7</sup> that aphasia following subcortical stroke is associated with decreased blood flow in the territory of the middle cerebral artery as well as decreased cortical rCBF, both of which may indicate an alteration of cortical function. To our knowledge, we provide the first description of a task-related negative BOLD response related to a subcortical hemorrhagic stroke. Interestingly, the structure of the associated left hemispheric cortices was preserved. In general, paradigms employed in MR mapping studies are supposed to map increased brain activation from a lower degree of

neuronal activity to a higher degree, modulated by an elevation of the hemodynamic response in terms of increased blood flow. This close correspondence between neural activity and CBF—referred to as *neurovascular coupling*<sup>8</sup>—was presumably disrupted during the first session.

The ECD-SPECT results, performed in the same time window, argue for this assumption. Because of a reduced capacity to increase CBF, the elevation of oxygen consumption caused by activation resulted in a local increase in venous deoxyhemoglobin concentration, rather than the decrease that occurs in healthy tissue due to rising perfusion. Thus, we had evidence of activation in the eloquent cortices in the presence of clinically manifest aphasia. We attribute this finding to a temporary, functional deafferentation of these cortical areas. The follow-up MR sessions with the return to a positive BOLD signal and an improvement from aphasia further support our explanation. Hence, recovery of neurovascular coupling accompanied clinical improvement from aphasia. A possible explanation for the dynamic change of

the MR BOLD signal is offered by the concept of "diaschisis,"<sup>9</sup> which states that cells involved in language processing are in a temporary state of reduced activity due to deprivation from afferent, i.e., subcortical, inputs due to a stroke event. In accordance with the diaschisis concept, the dynamic BOLD changes in our study were a transient phenomenon and its reversal paralleled recovery of function.

It has been suggested<sup>7</sup> that aphasia following striatocapsular infarction due to ischemia in the territory of the middle cerebral artery is most likely due to a selective neuronal loss or incomplete infarction of the corresponding cerebral cortex with preservation of the structural shape. In this view, recovery demands reorganization initiated by spared cortical neurons that might additionally recruit neighboring neurons to restore language functions. In contrast, our results suggest that recovery following subcortical hypertensive hemorrhage is accompanied by a repair of neurovascular coupling in the corresponding eloquent cortices. We did not find any evidence of incomplete infarction on structural MR during the follow-up period. The changes in our follow-up occurred within or close to the original field and extended to the perisylvian cortex. In particular, engagement of superior temporal cortices was associated with semantic encoding and paralleled clinical recovery from aphasia in our patient. In other subjects, pure word processing did not involve the superior temporal cortices, which are activated when encoding of more complex (i.e., sentential) stimuli is required.<sup>10</sup> Hence, the temporal cortex involvement in our patient study may reflect a more strenuous processing; the performance data further argue for

this assumption. Previous research<sup>1</sup> also reported a functional transfer to the right hemisphere following left hemispheric lesion. Our results suggest that this left-to-right shift is only transient in nature and does not compensate for the clinical deficit in subcortical lesions.

### Acknowledgment

The authors thank Barbara Engell for performing and analyzing the Aachen Aphasia Test.

### References

1. Weiller C, Isensee C, Rijntjes M, et al. Recovery from Wernicke's aphasia: a positron emission tomographic study. *Ann Neurol* 1995;37:723-732.
2. Heiss WD, Kessler J, Thiel A, et al. Differential capacity of left and right hemispheric areas for compensation of post-stroke aphasia. *Ann Neurol* 1999;45:430-438.
3. Huber W, Poeck K, Weniger D, Willmes K. *Aachener Aphasia Test*. Göttingen: Verlag Psychologie Hogrefe; 1983.
4. Binder J, Swanson S, Hammeke T, et al. Determination of language dominance using functional MRI: a comparison with the Wada Test. *Neurology* 1996;46:978-984.
5. Kruggel F, Lohmann G. BRIAN (Brain Image Analysis): a toolkit for the analysis of multimodal brain datasets. In: *Computer assisted radiology*. Amsterdam: Elsevier, 1996:323-328.
6. Talairach J, Tournoux P. *Co-planar stereotactic atlas of the human brain*. Stuttgart: Thieme Verlag; 1993.
7. Weiller C, Willmes K, Reiche W, et al. The case of aphasia or neglect after striatocapsular infarction. *Brain* 1993;116:1509-1525.
8. Buxton RB, Frank LR. Dynamics of blood flow and oxygenation changes during brain activation: the balloon model. *Magn Reson Med* 1998;39:855-64.
9. Monakow C. *Die Lokalisation im Grosshirn und der Abbau der Funktion durch Kortikale Herde*. Wiesbaden: Bergmann; 1917.
10. Müller RA, Rothermel ME, Behen O, et al. Receptive and expressive language activations for sentences: a PET study. *Neuroreport* 1997;8:3767-3770.

# Neurology®

## Cortical reafferentation following left subcortical hemorrhage: A serial functional MR study

M. Hund-Georgiadis, U. Lex, D.G. Norris, et al.  
*Neurology* 2000;55;1227-1231  
DOI 10.1212/WNL.55.8.1227

This information is current as of October 24, 2000

<b>Updated Information &amp; Services</b>	including high resolution figures, can be found at: <a href="http://www.neurology.org/content/55/8/1227.full.html">http://www.neurology.org/content/55/8/1227.full.html</a>
<b>References</b>	This article cites 6 articles, 2 of which you can access for free at: <a href="http://www.neurology.org/content/55/8/1227.full.html##ref-list-1">http://www.neurology.org/content/55/8/1227.full.html##ref-list-1</a>
<b>Citations</b>	This article has been cited by 4 HighWire-hosted articles: <a href="http://www.neurology.org/content/55/8/1227.full.html##otherarticles">http://www.neurology.org/content/55/8/1227.full.html##otherarticles</a>
<b>Permissions &amp; Licensing</b>	Information about reproducing this article in parts (figures, tables) or in its entirety can be found online at: <a href="http://www.neurology.org/misc/about.xhtml#permissions">http://www.neurology.org/misc/about.xhtml#permissions</a>
<b>Reprints</b>	Information about ordering reprints can be found online: <a href="http://www.neurology.org/misc/addir.xhtml#reprintsus">http://www.neurology.org/misc/addir.xhtml#reprintsus</a>

*Neurology*® is the official journal of the American Academy of Neurology. Published continuously since 1951, it is now a weekly with 48 issues per year. Copyright . All rights reserved. Print ISSN: 0028-3878. Online ISSN: 1526-632X.

