

15. Lennon VA, Howard FM: Serological diagnosis of myasthenia gravis, in Nakamura RM, O'Sullivan MB (eds): *Clinical Laboratory Molecular Analysis: New Strategies in Autoimmunity, Cancer and Virology*. New York, Grune & Stratton, 1985, 29–44.
16. Garlepp MJ, Dawkins RL, Christiansen FT, et al: Autoimmunity in ocular and generalized myasthenia gravis. *J Neuroimmunol* 1981;1: 325–332.
17. Larsen PR, Davies TE, Hay ID: Autoimmune and infectious thyroiditis, in Wilson JD, Foster DW, Kronenberg HM, Larsen PR (eds): *Williams Textbook of Endocrinology*. Philadelphia, WB Saunders, 1998, 475–479.
18. Vial C, Charles N, Chauplannaz G, Bady B: Myasthenia gravis in childhood and infancy: Usefulness of electrophysiologic studies. *Arch Neurol* 1991;48:847–849.
19. Pascuzzi RM, Roos KL, Phillips II LH: Granulomatous inflammatory myopathy associated with myasthenia gravis. *Arch Neurol* 1986;43: 621–623.
20. Behan WM, Behan PO, Doyle D: Association of myasthenia gravis and polymyositis with neoplasia, infection and autoimmune disorders. *Acta Neuropathol* 1982;57:221–229.

and IIIrd ventricles, and a subdural hematoma caudal to the craniotomy. The postoperative course was complicated by hemiparesis and global aphasia. During recovery, the patient developed what was thought to be a complex partial seizure evidenced by head turning to the right with vocalization and left upper extremity clonic jerks. These were brief and occurred multiple times per day. A trial of carbamazepine was given with no improvement. It was noted that the spells occurred more frequently under stress, as when the patient was frustrated with communication. The diagnosis was changed to complex motor tics and the therapy changed to clonidine. The tics subsequently improved by 80%, although they were still present. We believe the development of complex motor tics due to frontal hemorrhage represents a unique etiology and could complicate postsurgical recovery in similar cases. (*J Child Neurol* 2000;15:769–771).

New-Onset Tic Disorder Following Acute Hemorrhage of an Arteriovenous Malformation

ABSTRACT

The etiology of tic disorder includes idiopathic, postencephalitic, head injury, carbon monoxide poisoning, stroke, and developmental syndromes. We report a case of new-onset complex motor and vocal tics that began after hemorrhage of an arteriovenous malformation located in the left frontal lobe. We have found no reported cases of new-onset tics related to arteriovenous malformations or hemorrhage into the frontal lobes. The patient is a 16-year-old right-hand-dominant boy who presented with generalized tonic-clonic seizures. Evaluation, including magnetic resonance imaging, revealed a left frontal arteriovenous malformation, confirmed by angiogram. Following resection, there was an intraparenchymal hemorrhage of the left frontal lobe with intraventricular hemorrhage, noted most prominently in the left lateral

Complex motor and vocal tics related to frontal lobe pathology are very rare. Infrequently, tic disorders have been described following craniocerebral trauma, although no cases were found in the literature of a complex motor and vocal tic following an arteriovenous malformation hemorrhage.^{1,2} The pathophysiology of tic disorders has concentrated on dysfunction of the basal ganglia and subthalamic structures.^{3,4} We present a unique case of a complex tic disorder, initially felt to be epileptic, following a hemorrhage of a left frontal arteriovenous malformation. This suggests a more important role for a frontal lobe etiology.

Case Report

M.W. is a 16-year-old, right-hand-dominant black boy who presented to a hospital in Cairo after new onset of a generalized tonic-clonic seizure. Initial evaluation included a detailed neurologic examination, which was normal. Computed tomography and magnetic resonance imaging (MRI) subsequently revealed a 3.5 × 2.5 cm arteriovenous malformation in the left frontal lobe. Four-vessel angiogram confirmed the presence of the arteriovenous malformation with primary feeding vessels from the left anterior cerebral artery as well as a lesser portion from the left middle cerebral artery (Figure 1).

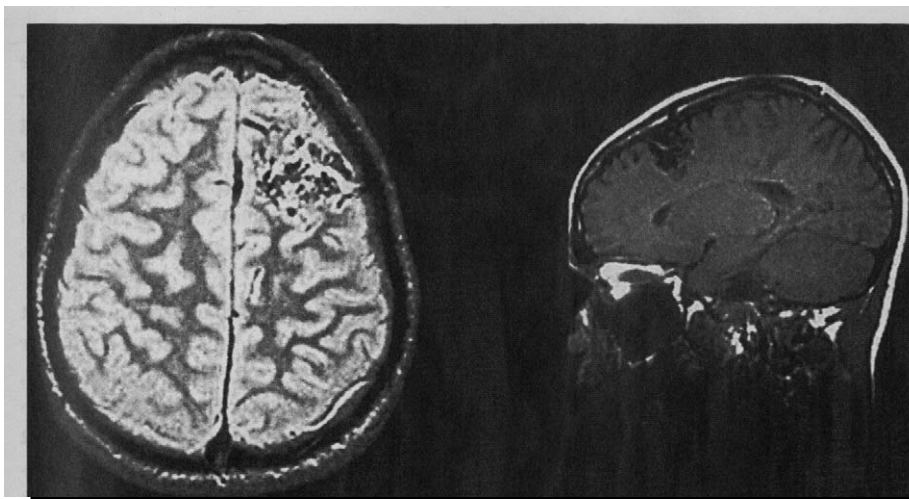


Figure 1. Preoperative magnetic resonance image of brain revealing left frontal arteriovenous malformation.

The patient was transferred to our center for preoperative embolization. Two days later, there was an acute rupture of the arteriovenous malformation with hemorrhage into the left frontal lobe and ventricles. The patient underwent an emergency frontoparietal craniotomy with evacuation of the intracerebral hematoma, placement of a left ventriculostomy, and resection of the arteriovenous malformation. The postoperative examination revealed a dense right hemiplegia and global aphasia. Additionally, M.W. developed some stereotypical movements: he would rapidly turn his head to the left multiple times, lasting for about 10 seconds at a time. Because of communication difficulty resulting from the aphasia, it was initially thought that these represented complex-partial seizures. An electroencephalogram revealed left anterior focal slowing with intermixed sharp components, although no electrographic equivalent correlated with the stereotypical movements. However, he was started on carbamazepine with no change in the severity or frequency of the movements after achieving a therapeutic blood level of carbamazepine. Additionally, M.W. began to have vocalizations associated with these movements, characterized by a brief "yeah" multiple times with each episode of head turning. It was noted that these occurred more frequently when the patient was under stress, as when attempting to answer questions. Upon subsequent evaluation, and with improvement of the receptive component of his aphasia, the patient stated that he felt a need to perform these actions and that he could suppress them for brief periods. These characteristics led to the diagnosis of complex motor and vocal tic. Therapy was changed to clonidine, initially at a dose of 0.1 mg daily and increased to 0.1 mg twice a day after several days. There was a resultant decrease in frequency and severity noted within a week of starting the clonidine. The frequency and severity of the tic had decreased significantly, by approximately 80%, by the patient's 6-month out-patient follow-up.

Discussion

The prototypical complex motor and vocal tic is seen with Tourette syndrome, first described by Gilles de la Tourette in 1885. Prevalence rates are quoted at 0.1 to 0.5 per 1000, but some authors suggest that the rates might be as high as 10 per 1000 with a male predominance. The diagnostic criteria for Tourette disorder, according to the *Diagnostic and Statistical Manual of Mental Disorders*, fourth edition (*DSM-IV*),⁵ are as follows: (1) both multiple motor and one or more vocal tics are present (not necessarily concurrently), (2) the tics occur multiple times per day, continuously or intermittently, for a period greater than 1 year, without a tic-free period greater than 3 months, (3) the disturbance causes marked distress or impairment in social, occupational, or other important areas of functioning, (4) onset is before age 18 years, and (5) the disturbance is not due to the direct physiologic effects of a substance or a general medical condition.

Despite much research in Tourette syndrome, the exact pathophysiology of it and of tic disorders in general is unknown. Hypotheses regarding the pathophysiology of posttraumatic tics include direct trauma, hemorrhage, ischemia, inflammatory changes, and central synaptic reorganization.¹ Structurally, it is widely believed that the basal ganglia, particularly the striatum, is the region predominantly affected.^{1,4,6,7} However, studies of tics developing after trauma and other injuries of both central and peripheral nervous systems would suggest that there also could be involvement of cortical areas, peripheral nerves, and axonal connections between the basal ganglia and cortex rather than solely basal ganglia damage. Recent studies by Braun et al have used positron emission tomographic (PET) scans to locate areas of abnormal metabolism in patients with Tourette syndrome.³ The most prominent areas of increased metabolism during active cognitive and behavioral symp-

toms associated with Tourette syndrome were the orbitofrontal cortices and the putamen. It is noteworthy that the frontal motor cortex was not active.³ Other studies with PET scans revealed decreased metabolic activity in orbital, frontal, and superior insular cortices, mesial temporal regions, and the striatum. Increased metabolism was shown in premotor areas, rolandic cortices, and the postrolandic sensory association areas.⁸ MRI studies also have shown volume reductions in the left putamen and globus pallidus and a reversal of the volumetric asymmetry seen in normal subjects, in whom the volume on the left is greater than the right.⁸⁻¹⁰ Thus, if the limbic-striatohalamic circuit is altered at any point, the entire circuit could be altered and could directly or indirectly influence the subsequent development of tic disorder.

Neurotransmitters also have been implicated in the production of Tourette syndrome and other tic disorders. One neurotransmitter frequently associated with tic disorders in the literature is dopamine.^{4,8-10} Autopsy evaluation of brains of some patients with Tourette syndrome has shown an increase in presynaptic dopamine receptors in the striatum. Various studies have shown that the receptors that are hyperactive in Tourette syndrome are primarily D₂ receptors. Increased D₂ receptors in the striatum would, in turn, cause overstimulation of the entire corticostriatohalamic system.¹⁰ Clinical evidence to support this includes the use of dopamine blockers to decrease tics. Further support comes from the fact that cessation of neuroleptics or use of dopamine agonists can induce tics in some patients.^{4,7,10}

Also implicated is the noradrenergic system. This comes primarily from the fact that medications such as clonidine (a potent α -adrenergic agonist) are used to treat tics, but it is further supported by the fact that tics can be exacerbated by the rapid withdrawal of clonidine. There are noradrenergic afferents that innervate the mesocortical and mesolimbic areas. As part of the ventral striatopallidal complex, they control motor behavior and can be altered by emotional stress. These afferents, when stimulated, will in turn modulate the release of dopamine in the ventral tegmental area.¹⁰

Finally, serotonin might also play a vital role in the pathogenesis of tics.^{4,10} Postmortem studies have revealed a decrease in serotonin, tryptophan, and 5-hydroxy-indoleacetic acid in the basal ganglia. Additionally, elevated plasma levels of a serotonin metabolite have been documented in patients with Tourette syndrome compared with normal controls.

We believe the mechanism in our case is that the hemorrhage caused dysfunction at the level of the corticostriate projections, thus decreasing inhibition to the basal ganglia and thereby triggering a hyperkinetic state presenting as tics, perhaps as alluded to by the PET studies conducted by Braun et al.³ This is in contrast to inherent dysfunction of the basal ganglia, which is directly affected in cases of tics caused by the aforementioned neurotransmitters, stroke, or encephalopathy.^{6,7}

In our case, initial treatment with carbamazepine was not beneficial. Because the spells were classic for a complex motor vocal tic, the patient's medication was soon changed to clonidine, which resulted in a decrease in symptoms. Both of these observations suggest that the disorder in this patient was a tic and not a seizure. They also support a cortical etiology for the tic. As previously mentioned, clonidine is an α -2 adrenergic agonist that acts

at the level of the cortex; its effect there is to modulate the release of dopamine in the ventral tegmental area. It is unclear why the tic disorder resolved given the degree of injury in this case. It is possible that the cells in the area of the hemorrhage responded with apoptosis and redirected neuronal circuitry. This is a suspected mechanism in the recovery process following traumatic brain injury. It is also possible that healing and scarring took place that were directly responsible for the resolution of the tics.

In conclusion, we believe our case represents a unique opportunity to expand the etiologic site of central nervous system dysfunction for complex motor vocal tics in that our patient's complex tic disorder resulted from damage to an area not presently known to be a site of pathology in complex tic disorders. Not only is the location of the dysfunction unique to a complex tic disorder, but the pathophysiology of hemorrhage following arteriovenous malformation rupture is also novel. This should be considered in assessing the risks and benefits of surgical management of arteriovenous malformations. Further study in this area also might help to provide insight into the etiologic mechanism of tic disorders, including Tourette syndrome.

Michael R. Yochelson, MD

Ronald G. David, MD

*Department of Child and Adolescent Neurology
Walter Reed Army Medical Center
Washington, DC*

Received August 16, 1999. Received revised Dec 20, 1999. Accepted for publication Dec 21, 1999.

Presented as a poster presentation at the Child Neurology Society Annual Meeting, Montreal, PQ, October 1998.

Address correspondence to Dr Michael R. Yochelson, Walter Reed Army Medical Center, Clinic 3J, Washington, DC 20307. Tel: 202-782-6368; fax: 202-782-0970; e-mail: duke91@dnamail.com.

References

1. Goetz CG, Pappert EJ: Trauma and movement disorders. *Neurol Clin* 1992;10:907-919.
2. Krauss JK, Jankovic J: Tics secondary to craniocerebral trauma. *Mov Disord* 1997;12:776-782.
3. Braun AR, Randolph C, Stoetter B, et al: The functional neuroanatomy of Tourette's syndrome: An FDG-PET study. II: Relationships between regional cerebral metabolism and associated behavioral and cognitive features of the illness. *Neuropsychopharmacology* 1995;13:151-168.
4. Riley DR, Lang AE: Movement disorders, in Bradley WG, Daroff RB, Fenichel GM, Marsden CD (eds): *Neurology in Clinical Practice*, 2nd ed. Boston, Butterworth-Heinemann, 1996, 1760-1761.
5. American Psychiatric Association: *Diagnostic and Statistical Manual of Mental Disorders*, 4th ed. Washington, American Psychiatric Association, 1994.
6. Brazis PW, Masdeu JC, Biller J: *Localization in Clinical Neurology*, 3rd ed. Boston, Little, Brown, 1996.
7. Weingarten K: Tics, in Vinken PJ, Bruyn GW (eds): *Handbook of Clinical Neurology*, Vol 6, *Diseases of the Basal Ganglia*. Amsterdam, North-Holland Publishing, 1968, 782-808.
8. Kurlan RM: Tourette's syndrome, in Watts RL, Koller WC (eds): *Movement Disorders: Neurologic Principles and Practice*. New York, McGraw-Hill, 1997, 569-575.
9. Juncos JL, Freeman A: Pathophysiology and differential diagnosis of tics, in Watts RL, Koller WC (eds): *Movement Disorders: Neurologic Principles and Practice*. New York, McGraw-Hill, 1997, 561-568.
10. Leckman JF, Bradley SP, Pauls DL, Cohen DJ: Tic disorders. *Psychiatr Clin North Am* 1997;20: 839-861.