

A. Sommer
S. Meairs
F. Gueckel
A. Cornelius
A. Schwartz

Traumatic brachiocephalic pseudoaneurysm presenting with delayed stroke: case report

Received: 11 May 1999
Accepted: 25 January 2000

A. Sommer · F. Gueckel
Department of Radiology,
University Hospital Mannheim,
Medical Faculty of University Heidelberg,
Germany

S. Meairs · A. Cornelius · A. Schwartz
Department of Neurology,
University Hospital Mannheim,
Medical Faculty of University Heidelberg,
Germany

A. Sommer (✉)
Lenaustrasse 4, 68167 Mannheim,
Germany
Tel.: (0049621) 3709890

Abstract We report a traumatic pseudoaneurysm of the internal carotid artery bifurcation and subclavian artery with recurrent strokes events in a 19-year-old man. He was admitted with an acute left hemiparesis. His history revealed a similar episode 1 year and a major car accident 3 years previously. Contrast enhanced MR angiography confirmed colour Doppler sonographic findings of a carotid and subclavian artery pseudoaneurysm presumably resulting from seat-belt trauma. The pseudoaneurysm, containing thrombus, was thought to be the source of artery-to-artery embolism.

Key words Aneurysm, traumatic · Artery, internal carotid · Magnetic resonance angiography · Sonography

Introduction

Traumatic pseudoaneurysms from blunt injury are often on the common or internal carotid artery, near the bifurcation of the former. Car accidents account for 62% of cases, with hyperextension of the cervical spine and vessel compression or a combination of hyperextension and strangulation by automatic shoulder seat-belts [1, 2]. It is often difficult to diagnose these lesions at an early stage, as they are sometimes accompanied by life-threatening injuries and the patients are frequently under general anaesthesia or sedation. Haematomas or contusion injuries of the neck are helpful signs of vessel injury in an unconscious patient. We present a case of recurrent stroke 3 years after trauma.

Case report

A 19-year-old man was admitted with an acute left hemiparesis. He was fully conscious. The history included previous but no current drug abuse and an episode of similar symptoms 1 year previously, with complete recovery, and a major car accident as a front seat passenger 3 years previously. At that time, he was kept under general anaesthesia, with adult respiratory distress syndrome, haemorrhagic shock, acute renal failure and major injuries of the abdomen and legs. No chest or neck trauma was reported. A correct catheter position in the right jugular vein was documented; no subclavian vein puncture was performed. The patient was operated upon twice and kept under assisted ventilation for 14 days. He recovered without any apparent neurological deficit.

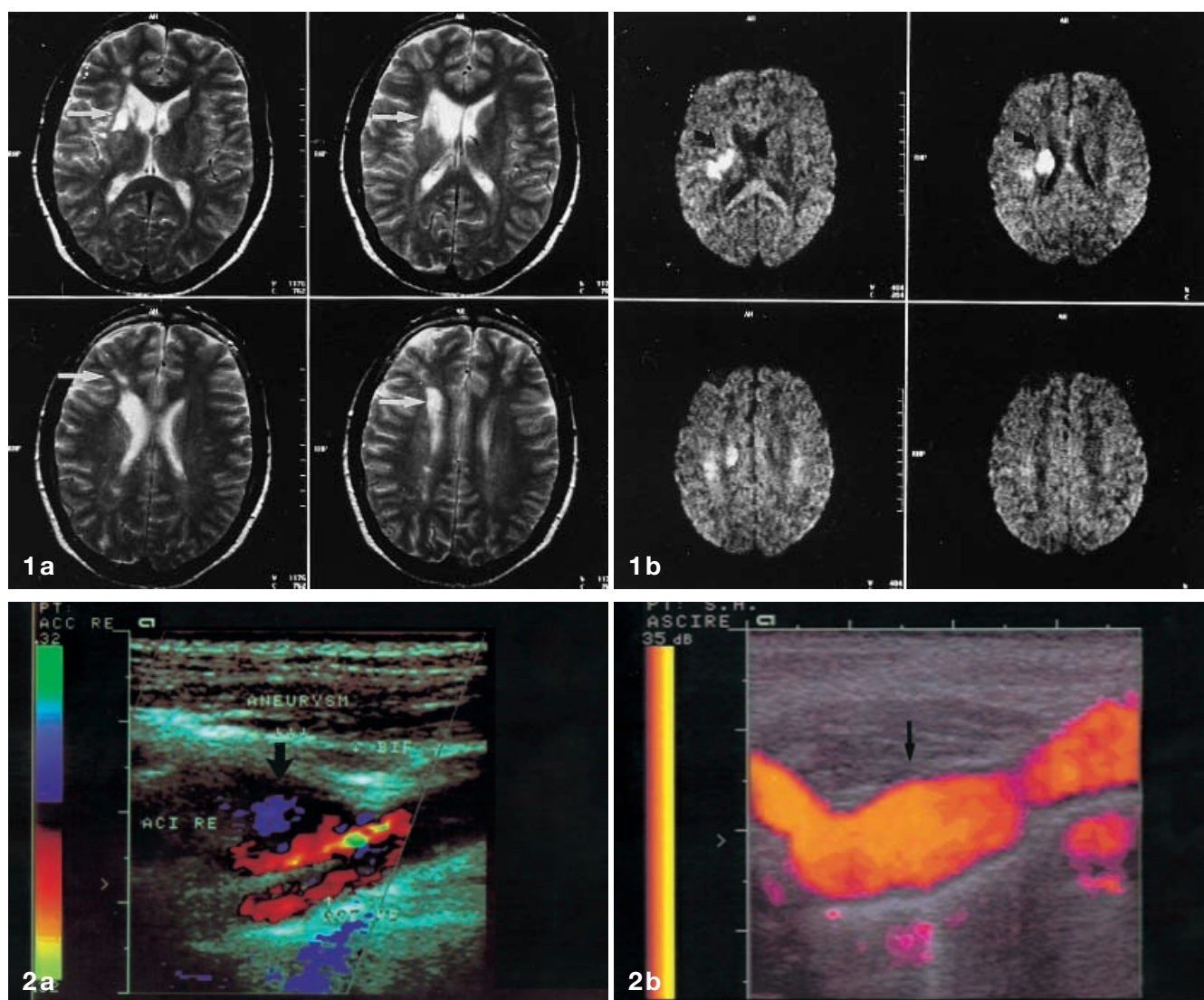


Fig. 1 **a** T2-weighted image shows multiple old ischaemic lesions in the white matter and close to the basal ganglia of the right hemisphere (*arrows*). **b** Diffusion-weighted image reveals a high-signal lesion close to the basal ganglia in the white matter indicating an acute infarct (*arrows*)

Fig. 2a,b Colour Doppler sonography shows an aneurysm of the right carotid bifurcation and ectasia of the subclavian artery

On the present admission, MRI showed old vascular lesions in the centrum semiovale and basal ganglia of the right cerebral hemisphere. Diffusion-weighted imaging (0.8/123 ms [TR/TE]) including apparent diffusion coefficient maps revealed an acute infarct in the right basal ganglia, posterolateral to an old lesion (Fig. 1). No apparent source of embolism was revealed by extensive cardiovascular investigation. Extracranial colour Doppler sonography suggested a pseudoaneur-

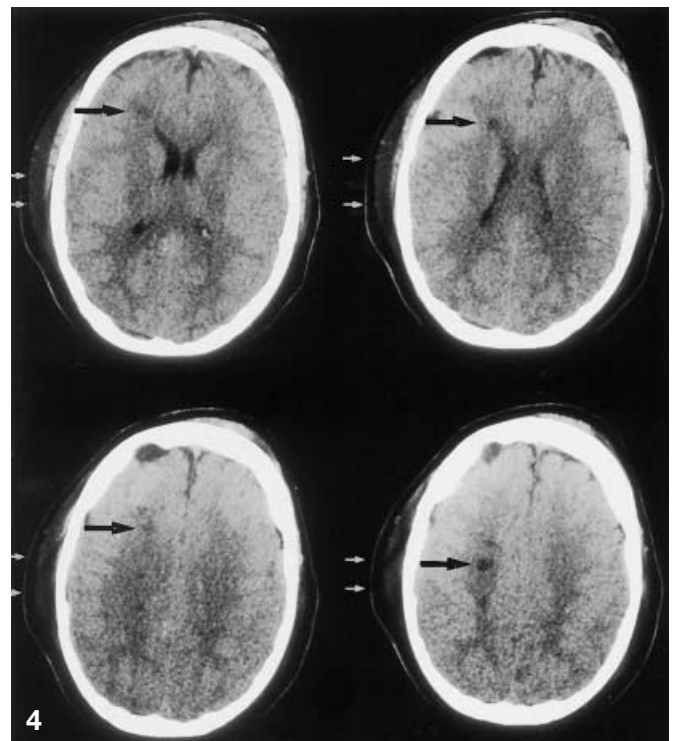
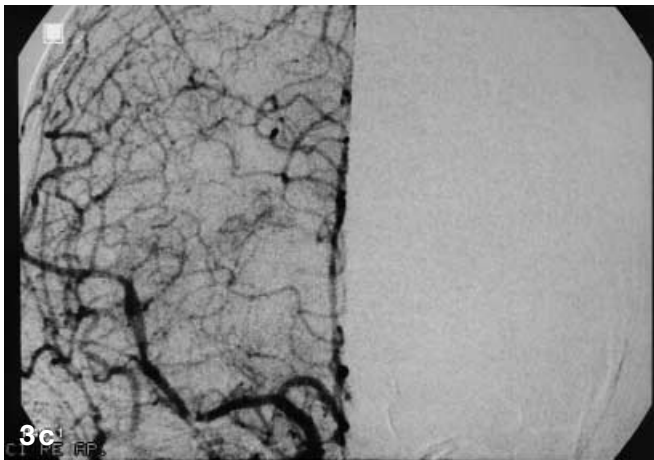
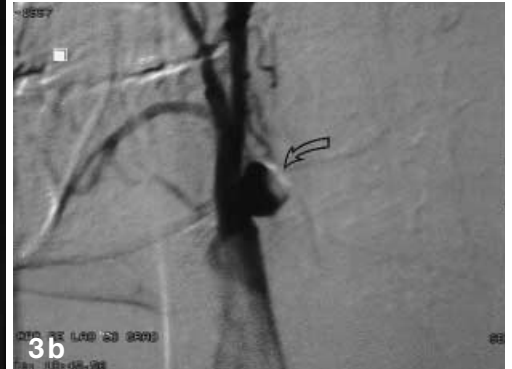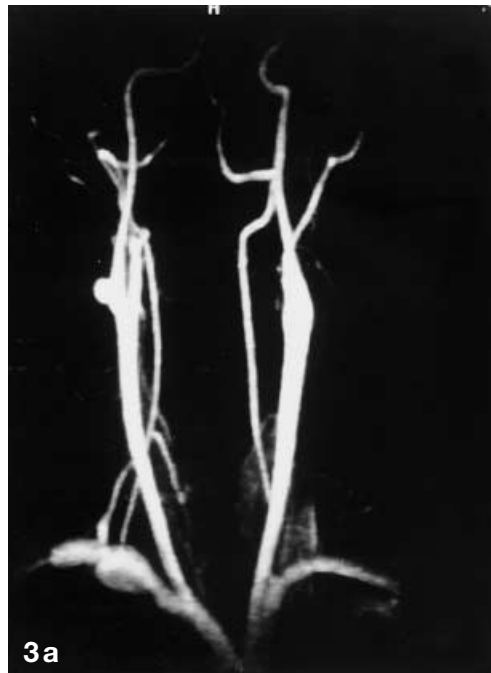ysm of the lateral wall of the right carotid bulb containing echolucent thrombus and an ectatic subclavian artery (Fig. 2). Contrast-enhanced MRA of the neck (4.6/1.8 ms, 20 s, 35° [TR/TE, acquisition time, flip angle]) and conventional angiography confirmed the sonographic findings (Fig. 3). The acute stroke was presumably due to partial occlusion of the right M1 segment shown by conventional angiography (Fig. 3c). A surgical removal of the common carotid artery bifurcation pseudoaneurysm was performed, and the endarterectomy completed by a saphenous vein graft.

Discussion

Traumatic common or internal carotid artery injury, first reported by Verneuil in 1872, is uncommon, occurring in less than 1 in 1000 blunt injuries [1–3]. However, a re-

Fig. 3a,b The findings of Fig. 2 are confirmed by contrast-enhanced of the neck and conventional angiography (*arrows*). **c** Conventional angiography shows thrombus in the right M1 segment

Fig. 4 CT 2 days after the initial accident demonstrates right extracranial swelling (*arrow*). White matter low density (*arrow*) may indicate acute ischaemic lesions



cently published study of unsuspected blunt carotid artery injury, suggested a tenfold risk in patients with moderate to severe systemic injury who were investigated appropriately [4]. Vessel occlusion, dissection, transection or pseudoaneurysm of the common or internal carotid artery have been described [5, 6]. Most

commonly, the vessel wall damage is attributed to five types of injury: hyperextension, with compression of the artery against the transverse process of the cervical vertebral body; hyperflexion, with compression between the mandible and the spine; direct intraoral trauma with a foreign body in the mouth; skull base fractures; a

combination of hyperextension and direct trauma by a three-point seat belt [2, 7]. Delayed neurological symptoms are a well known characteristic of blunt carotid artery injury, from hours to months following the injury. A delay of more than 20 weeks or even years is rare, but reported. Devastating consequences such as severe stroke or death have been observed [8, 9]. Our patient was admitted after the accident in an unconscious and unstable situation. But there was no report of injury to the right neck or upper chest; no remarkable haematoma or contusion of the right upper body had been documented. The possibility of iatrogenic pseudoaneurysm, because of puncture of the carotid or subclavian artery was excluded, and is unlikely due to the location (dorsolateral wall) of the pseudoaneurysm. CT 2 days after injury already showed white matter low density

suspicious of acute ischaemic lesions and a small right temporal extracranial haematoma (Fig. 4).

The history of this patient with recurrent embolic episodes demonstrates that a blunt cervical vessel injury after severe trauma by a three-point seat belt should be considered even in the absence of evident local injury (haematoma, skin lesions, neck swelling). It may be that white-matter lesions, not obviously due to contusion, should be investigated as possibly embolic; sonography may be helpful [10]. In cases of suspicious ultrasound findings we would recommend a noninvasive fast imaging modality, for example, MR- or CT-angiography [11]. Conventional angiography may be required when a surgical or interventional procedure is planned [9]. Surgical resection and endovascular stenting are competing methods for repair of a pseudoaneurysm [12–14].

References

1. Benito MC, García F, Fernández-Quero L, Lajara A, Jardón E, Firas I, Manzanos A (1990) Lesion of the internal carotid artery caused by a car safety belt. *J Trauma* 30: 116–117
2. McConnell EJ, Macbeth GA (1997) Common carotid artery and tracheal injury from shoulder strap seat belt. *J Trauma* 43: 150–152
3. Verneuil M. Confusions multiples; délire violent; hémiplegie à droite, Signes de compression cérébrale *Bull Acad Med (Paris)* 1872; 36: 46–56
4. Prall JA, Brega KE, Coldwell DW, Breeze RE (1998) Incidence of unsuspected blunt carotid artery injury. *Neurosurgery* 42: 495–499
5. Pozzati G, Giuliani M, Poppi A, Feanza (1989) Blunt traumatic carotid dissection with delay of symptoms. *Stroke* 20: 412
6. Hayes CW, Conway WF, Walsh JW, Coppage L, Gervin AS CW (1991) Seat belt injuries: radiologic findings and clinical correlation. *RadioGraphics* 11: 23–26
7. Mulloy JP, Flick PA, Gold RE (1998) Blunt carotid injury: a review. *Radiology* 207: 571–585
8. Pretre MD, Kürsteiner K, Reverdin A, Faidutti B (1995) Blunt carotid artery injury: devastating consequences of undetected pseudoaneurysm. *J Trauma* 39: 1012–1014
9. Wurm W, Löffler W, Wegenschimmel W, Fischer J (1995) Traumatische Schädigung der Arteria carotid interna im extrakraniellen Bereich. *Chirurg* 66: 916–919
10. Hebra A, Robison JG, Elliott M (1993) Traumatic aneurysm associated with fibrointimal proliferation of the common carotid artery following blunt trauma: case report. *J Trauma* 34: 297–299
11. Desimpelaere J, Seynaeve P, Kochx M, Apple B, Gyselincx J, Mortelmans L (1997) Mycotic pseudo-aneurysm of the extracranial carotid artery. *J Belge Radiol* 80: 170–171
12. Butterworth RJ, Thomas DJ, Wolfe JH, Mansfield AO, Al-Kutoubi A (1999) Endovascular treatment of carotid dissecting aneurysm. *Cerebrovasc Dis* 9 (4): 242–247
13. Simionato F, Righi C, Scotti G (1999) Post-traumatic dissecting aneurysm of extracranial internal carotid artery: endovascular treatment with stenting. *Neuroradiology* 41: 543–547
14. Horowitz MB, Miller G 3rd, Meyer Y, Carstens G 3rd, Purdy PD (1996) Use of intravascular stents in the treatment of internal carotid and extracranial vertebral artery pseudoaneurysms. *AJNR* 17: 693–696