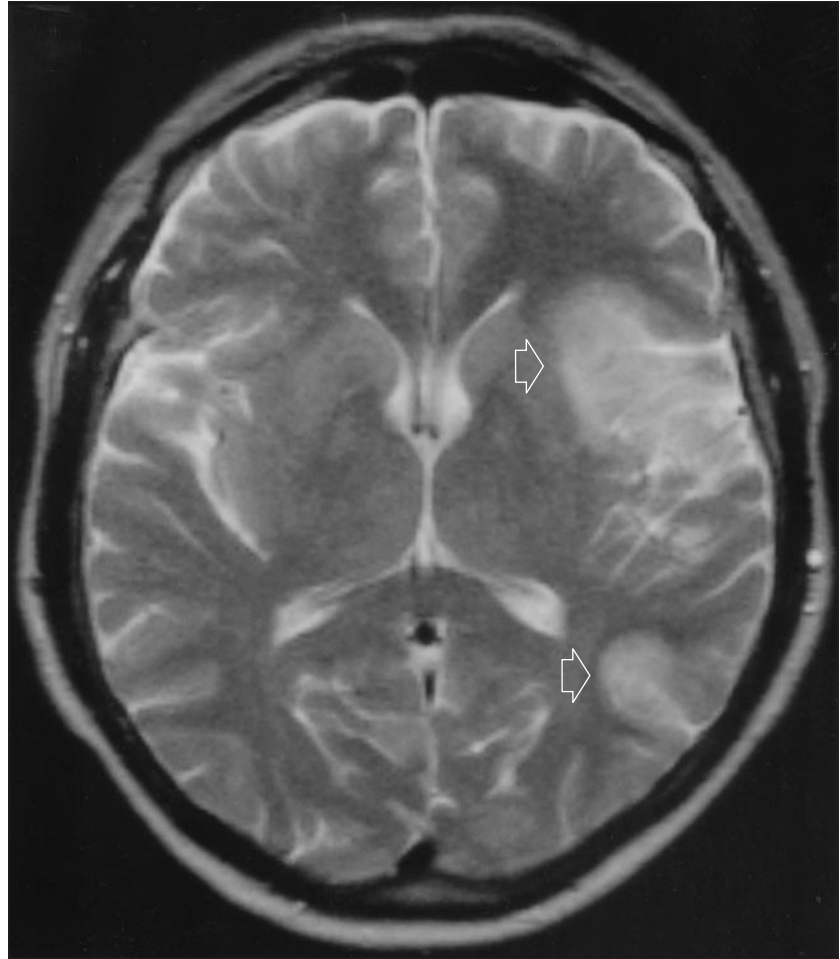


# Global Aphasia Without Hemiparesis Secondary to *Kingella kingae* Endocarditis

**A** 53-YEAR-OLD man was admitted with a 2-day history of odd behavior and increased drowsiness. On the day of admission he suddenly lost the ability to speak. He also had a 3-month history of lethargy, abdominal pain, and weight loss, which had been investigated by his general practitioner. The only abnormality found was a plasma viscosity of 2.27 mPas (normal, 1.25–1.72 mPas). He smoked 20 cigarettes per day. The remainder of the history was unremarkable. On admission he was pyrexial (temperature, 38.0°C) and tachycardic with a global aphasia without hemiparesis. There were no other abnormalities: in particular the findings of cardiovascular examination were normal.

He had a plasma viscosity of 2.5 mPas, a C-reactive protein level of 65 mg/L, and a positive rheumatoid factor with a titer of 1:320. The findings of other investigations, including transthoracic echocardiogram, were all normal. Cranial magnetic resonance imaging (**Figure 1**) revealed 2 discrete areas of infarction. His cerebrospinal fluid contained 20 red cells per cubic millimeter and 210 white cells per cubic millimeter, 80% of which were lymphocytes: the protein and glucose values were normal. He began treatment with high-dose cefotaxime and acyclovir. Cerebrospinal fluid examination 2 days later revealed 185 white cells per cubic millimeter, 0.80 neutrophils. The protein and glucose values were again normal. Transesophageal echocardiography demonstrated vegetation on the aortic (**Figure 2**) and mitral



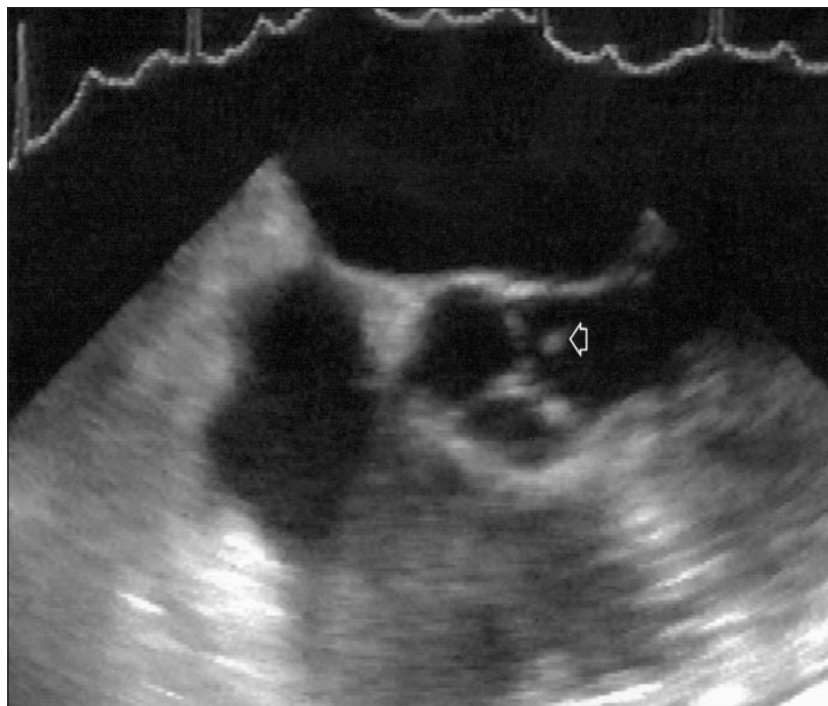
**Figure 1.** A turbo spin-echo T2-weighted magnetic resonance imaging scan revealing 2 discrete areas of cerebral infarction (arrows) in the territory of the left middle cerebral artery, separated by normal brain tissue.

(**Figure 3**) valves. Blood cultures after 14 days of incubation grew an unusual Gram-negative bacillus, which was later identified as *Kingella kingae*. He was treated with a 4-week course of cefotaxime, and the findings of a cerebrospinal fluid analysis after this time were entirely normal. His plasma viscosity, C-reactive protein levels, and

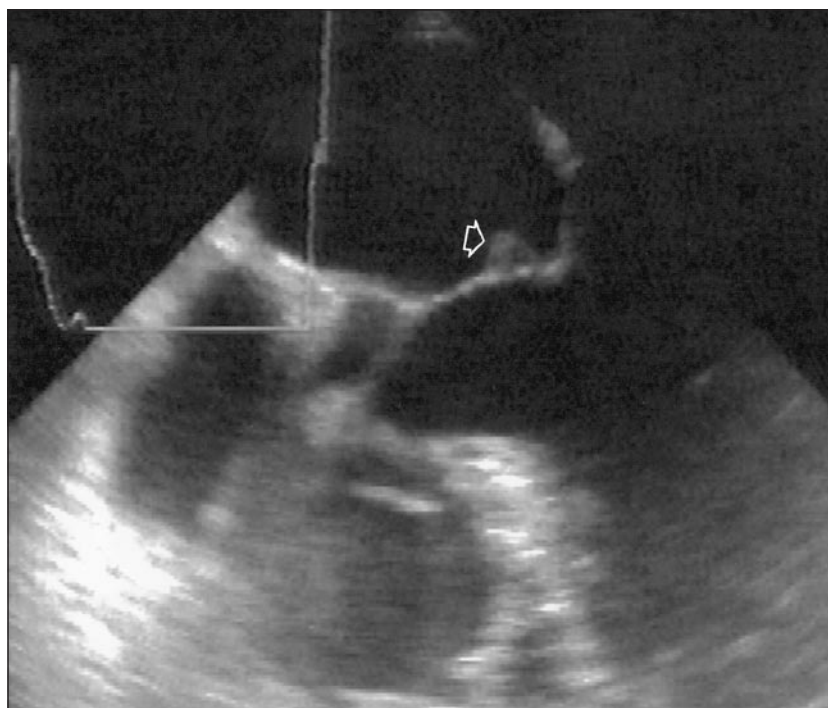
rheumatoid factor values all returned to normal. He continued to improve, though he was left with a mild expressive aphasia.

## COMMENT

Global aphasia without hemiparesis has been described and is usually the result of cardioembolism.<sup>1</sup>



**Figure 2.** A transesophageal echocardiogram revealing the typical appearance of the aortic valve with clearly visible vegetation (arrow).



**Figure 3.** A transesophageal echocardiogram showing vegetation attached to the mitral valve (arrow).

It seems likely that this patient had 2 embolic events: the initial embolus resulting in the "odd behavior" described by his wife, possibly representing a receptive aphasia; and the second completing the global aphasia. The magnetic resonance imaging scan correlates with this, demonstrating infarctions in the territories of both the anterior and posterior divisions of the middle cerebral artery (Figure 1).

*Kingella kingae* is a Gram-negative bacillus that is a member of a fastidious group of organisms called the HACEK group (*Hae-mophilus* species, *Actinobacillus actinomycesemimittans*, *Cardiobacterium hominis*, *Eikenella corrodens*, and *Kingella* species). These organisms are normal oropharyngeal commensals and can take up to 3 weeks to culture. They are responsible for about 3% of cases of endocarditis,<sup>2</sup> though *K kingae* endocarditis is rare, and this is the first report of it causing cerebral infarction in an adult.

M. B. Lewis MB BS, MRCP  
Leeds General Infirmary  
Great George Street  
Leeds LS1 3EX, England  
(e-mail: m-k-lewis@email.msn.com)

J. M. Bamford MD, FRCP  
Leeds

## REFERENCES

1. Hanlon RE, Lux WE, Dromerick AW. Global aphasia without hemiparesis: language profiles and lesion distribution. *J Neurol Neurosurg Psychiatry*. 1999;66:365-369.
2. Barbari EF, Cockerill FR III, Steckelberg JM. Infective endocarditis due to unusual or fastidious microorganism. *Mayo Clin Proc*. 1997;72:532-542.