

Case Reports

Dissecting Aneurysm of the Peripheral Posterior Inferior Cerebellar Artery

Y. Kanou¹, K. Arita¹, K. Kurisu¹, F. Ikawa¹, K. Eguchi², S. Monden², and K. Watanabe²

¹ Department of Neurosurgery, Hiroshima University School of Medicine, Hiroshima, Japan

² Department of Neurosurgery, Onomichi General Hospital, Onomichi, Japan

Summary

Dissecting aneurysms of intracranial posterior circulation have recently been shown to be less uncommon than previously thought. However, those involving the posterior inferior cerebellar artery (PICA) and not vertebral artery at all are extremely rare. We report here a case of a patient with a dissecting aneurysm of the lateral medullary segment of PICA which presented as subarachnoid haemorrhage. The aneurysm was treated by trapping surgery and the distant PICA was anastomosed to the occipital artery. The patient showed a slight ataxia immediately after surgery but recovered fully.

Recovery from immediately postoperative cerebellar symptoms due to intra-operative ischemia seemed to be due largely to recovery of flow in the region of cortical branches of PICA.

Keywords: Dissecting aneurysm; posterior inferior cerebellar artery; subarachnoid haemorrhage; anastomosis.

Introduction

Dissecting aneurysms of the posterior inferior cerebellar artery (PICA) are relatively rare, and when they occur typically arise at the origin of the PICA [9, 22, 30]. A search of the literature revealed 14 reported cases of peripheral PICA dissecting aneurysms. In most reported cases, the lesion was treated by occlusion of the proximal PICA. In our case, the dissection was located at the lateral medullary portion and the lesion was successfully treated by trapping combined with occipital artery (OA)-PICA anastomosis. We will discuss the pathophysiology, diagnosis, and treatment modalities associated with this condition, including recovery of blood flow in PICA.

Case Report

A 52-year-old man without hypertension or diabetes mellitus was admitted to Onomichi General Hospital, Department of Neurosurgery on August 28, 1997 due to severe headache and vomiting. His consciousness was almost clear (Glasgow coma scale: 15) and he

was neurologically intact apart from blurred vision bilaterally. Upon admission, computed tomography (CT) revealed a subarachnoid haemorrhage (SAH) mainly in the ambient cistern and haematomas in the third and fourth ventricle. Angiography performed on the same day failed to reveal any obvious aneurysms. The patient underwent conservative treatment at that point.

Angiography on 11 September revealed a “Pearl and string” sign in the left PICA, accompanied by retention and pooling of the contrast medium and diffuse vasospasm (Fig. 1b). Furthermore, a review of the previous angiograms revealed a subtle narrowing in the same region of the PICA (Fig. 1a), all of which led to the diagnosis of dissecting PICA aneurysm.

The patient was referred to Hiroshima University hospital, Department of Neurosurgery and admitted on October 15 to undergo radical treatment of the lesion. MRI performed two days after admission revealed an asymptomatic infarction of the right cerebellar hemisphere in the T2 weighted image (T2WI) (Fig. 2a). The T1 weighted image (T1WI) revealed a flow void the true lumen and the false lumens, visualized as a high intensity area surrounding the former (Fig. 3). Repeated angiography on the same day demonstrated an increase in the size of the aneurysm (Fig. 1c), which was predictive of rebleeding. Direct surgery was performed on October 27. The occipital artery was exposed. A left suboccipital craniectomy, quarter occipital condylotomy and C1 laminotomy were performed. After making a dural incision, the aneurysmal wall could be easily located at the left cerebello-medullary cistern. A subadventitial haemorrhage with black discoloration was observed in the wall of the aneurysm. The medial wall of the aneurysm had adhered to the medulla oblongata. A perforator was located proximal to the origin of the dissection. A second perforator already collapsed had its origin in the aneurysmal wall itself.

The aneurysm was trapped using two clips, one was applied just distal to the first perforator while the other was placed at the distal end of the aneurysm. Next, an occipital artery-PICA end to side anastomosis was performed at the posterior medullary segment. The surgery was performed under mild hypothermia at 34 °C.

The patient's postoperative course was uneventful, and no other clinical symptoms apart from mild cerebellar ataxia were present. The cerebellar infarction, which was present prior to surgery, increased slightly in size (Fig. 2b) probably due to a transient cessation of peripheral PICA blood flow during the anastomosis. The ataxia gradually improved and disappeared within 3 months. Postoperative left vertebral angiography confirmed good patency of the OA-PICA anastomosis and obliteration of the aneurysm (Fig. 4).

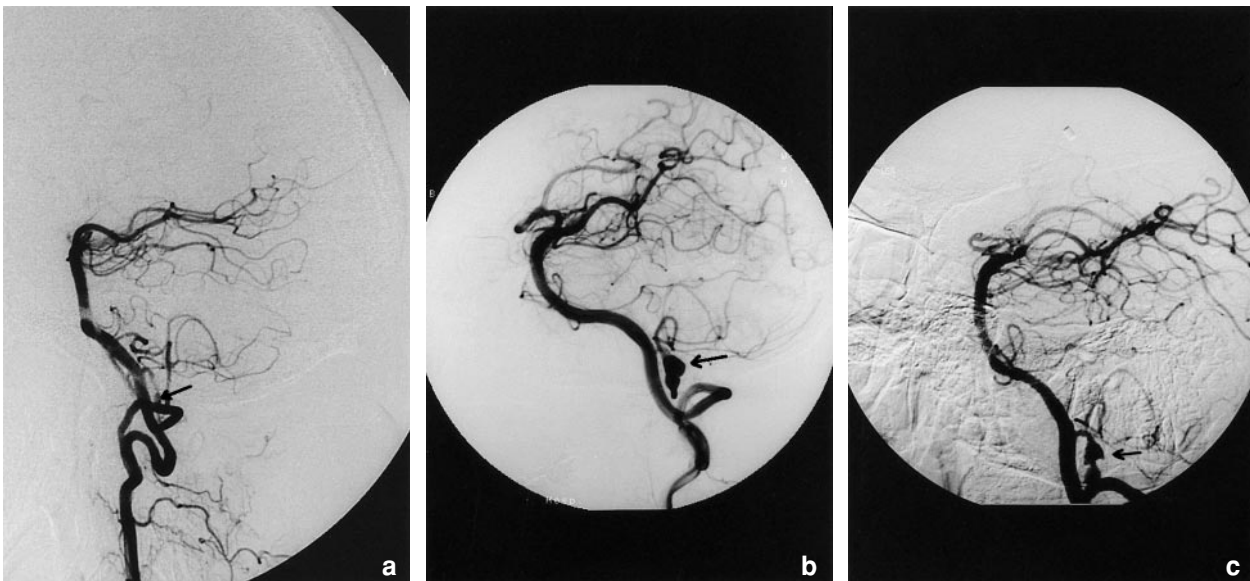


Fig. 1. Left vertebral angiograms, lateral (a), left anterior oblique 60° (b) and right anterior oblique 45° (c) views, showing an irregularly shaped dissecting aneurysm at the lateral medullary segment of the posterior inferior cerebellar artery (PICA) (arrows)

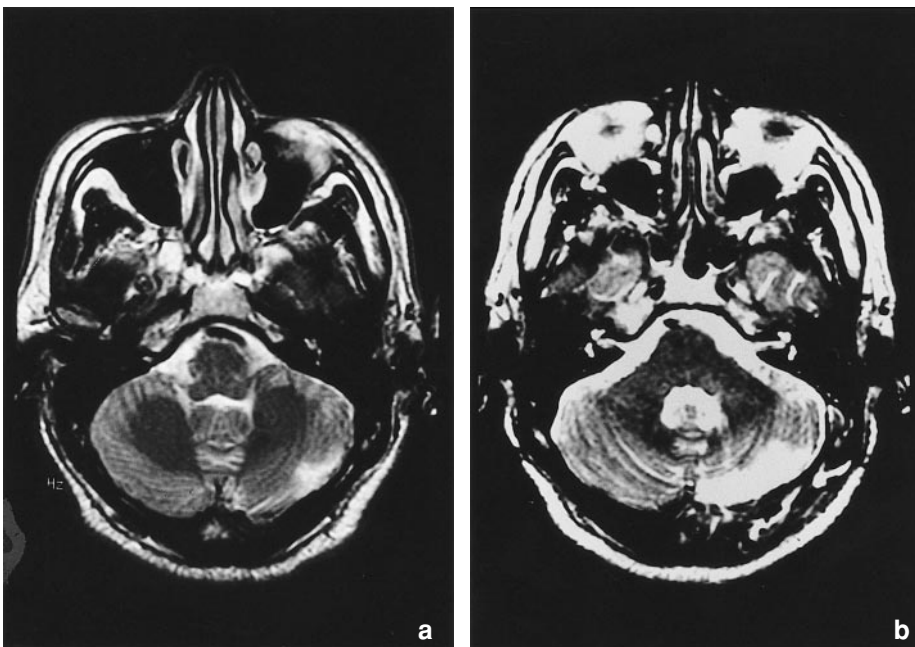


Fig. 2. T2-weighted magnetic resonance images, axial views, demonstrating a high intensity area in the left dorsal hemisphere the extent of which is larger in the postoperative image (b) than in the pre-operative image (a)

Review (Table 1) of the Literature

We will review previously reported case studies of peripheral dissecting PICA aneurysms [6, 10–12, 17, 18, 20, 26–28, 31, 33]. The 14 patients from these studies included 6 men and 8 women.

The mean age of the patients was 42.5 with a range of 22 to 68. Of the 14, 6 had hypertension and 1 had diabetes mellitus. No patient had an accompanying systemic disease which precipitated the occurrence of the dissecting aneurysms. The symptoms varied for each case. SAH was observed in nine cases and in-

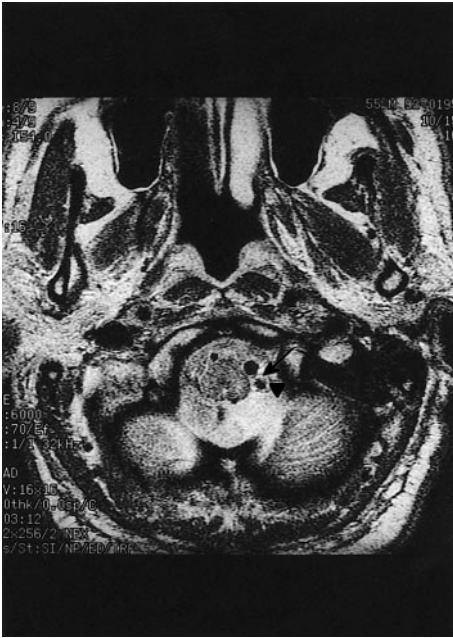


Fig. 3. MRI of dissection of the lateral medullary segment of the PICA. The axial T1-weighted magnetic resonance image demonstrates thrombus within the false lumen of the dissected vessel as an area of increased signal (arrowhead) surrounding the true lumen, which was demonstrated as flow void (arrow)

farction in six (one case presented with both), four of whom were associated with Wallenberg's syndrome. The major attack was heralded by a minor episode in five cases, two of whom presented with SAH. Vertebral angiography revealed a fusiform dilatation with or without irregular narrowing in almost all cases (13/14). The dissections were located at the origin in three cases, anterior medullary segment in seven (one case had bilateral aneurysms in this lesion), lateral medullary segment in one, cranial loop in one and tonsillo-hemispheric segment (including telovelotonsillar segment) in three.

The time period between the onset and surgery varied from one day to four months. Eleven patients underwent craniotomy. Aneurysmectomy was chosen in two, clipping in four (a Sundt clip was used in two), wrapping in one, simple trapping in two, and trapping with anastomosis in two. Endovascular embolisation was done in one case. The other two cases were treated conservatively.

Histological findings were obtained in four cases, but no definite tendency was detected as to the layer of dissection. Localized giant cell angitis without systemic involvement was histologically demonstrated in case eight.

All patients who underwent radical treatment survived. The activity of daily living score in these

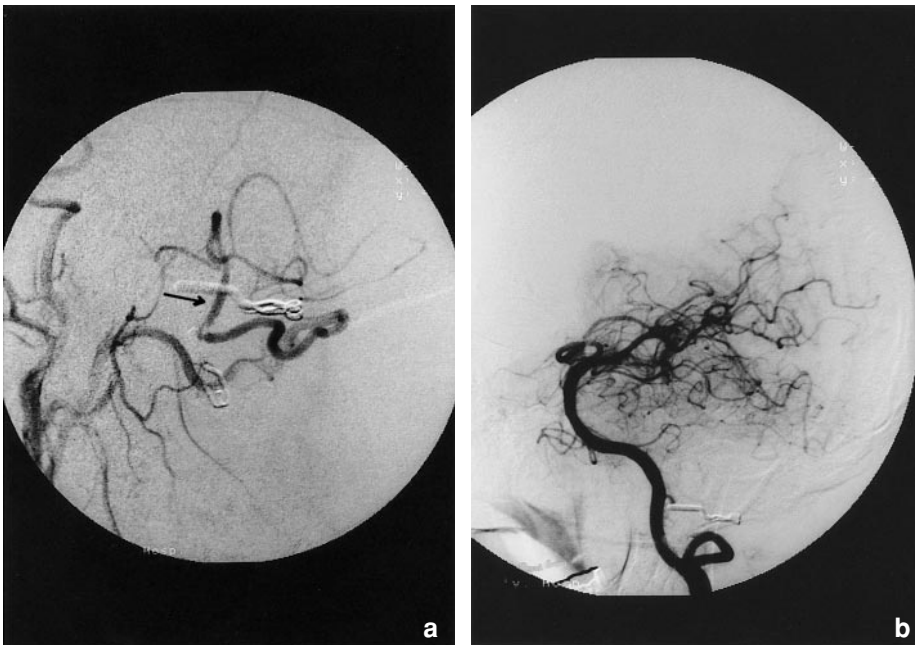

Fig. 4. Angiograms performed 1 week after surgery of the left external carotid artery (a) and left vertebral artery (b). The distal portion of PICA (arrow) was visualized through the occipital artery and the aneurysm has disappeared

Table 1. Summary of 15 Cases with Dissecting Aneurysms of the Posterior Inferior Cerebellar Artery

Authors	Age, sex	Presentation	Portion	Angiographic findings	Surgery	Outcome
Friedman AH, 1984 (6)	46, M	SAH	origin (right)	fusiform dilatation	clipping (by Sundt clip)	uneventful
Ueki K, 1987 (33)	47, F	SAH	anterior medullary segment (right)	narrowing and dilatation, contrast medium retention	wrapping	improvement of left Wallenberg's syndrome
Komiya H, 1988 (13)	37, M	infarction	anterior medullary segment (left)	fusiform dilatation	proximal clipping	hoarseness, dysarthria
Nishino A, 1991 (21)	51, F	SAH	telovelotonsillar segment (left)	saccular	aneurysmectomy	normal
Yamaura A, 1991 (35)	68, F	SAH	tonsillohemispheric branch (left)	narrowing and dilatation, contrast medium retention	entrap	normal
Yamaura A, 1991 (35)	47, M	infarction	anterior medullary segment (left)	fusiform, irregular dilatation	no surgery	normal
Yamaura A, 1991 (35)	59, F	SAH	tonsillohemispheric branch (left)	irregular dilatation	aneurysmectomy	normal
Takahashi K, 1992 (29)	22, F	SAH	lateral medullary segment (left)	tapering occlusion	trapping	normal
Kawaguchi S, 1993 (12)	29, F	infarction	anterior medullary segment (left)	fusiform dilatation	trapping + anastomosis	uneventful
Nagahiro S, 1991 (19)	31, M	infarction	origin (left)	distal narrowing	trapping + anastomosis	uneventful
Mizushima H, 1994 (18)	29, F	infarction	origin (left)	spindle-shaped dilatation	proximal clipping	unremarkable
Tikkakoski T, 1997 (30)	34, F	SAH	cranial loop (left)	fusiform, irregular dilatation	embolization	normal
Jafar JJ, 1998 (10)	48, M	SAH	anterior medullary segment (left)	irregular dilatation	clipping (by Sundt clip)	normal
Shinoda S, 1998 (28)	47, M	infarction (SAH)	anterior medullary segment (bilateral)	dilatation and narrowing	no surgery	dead
present case, 1999	52, M	SAH	lateral medullary segment (left)	narrowing and dilatation, contrast media retention	trapping + anastomosis	normal

SAH Subarachnoid haemorrhage, parentheses; reference number.

patients was grade I–II (Glasgow Outcome Scale). One of the two who were conservatively treated died as a result of SAH following ischemic symptoms. Follow-up angiography performed in eight patients with craniotomy demonstrated complete disappearance of the aneurysm in every case. In one case of conservative treatment, the aneurysm was found to have decreased in size.

Discussion

PICA aneurysms are rare, accounting for only 0.5 to 0.7% of all intracranial aneurysms [9, 22, 30]. Dissecting aneurysms of the PICA are far rarer and usually occur at the proximal part of the PICA which includes the vertebral artery. We report a case where the patient suffered SAH caused by a dissecting aneurysm in the PICA of the lateral medullary segment.

Etiology

The etiology of the dissecting aneurysms of the PICA remains unknown. No precipitating factors for dissecting aneurysms, such as trauma, multiple nodular angitis, migraine, fibrous dysplasia, Moyamoya disease, Marfan's syndrome or homocystinuria were found in any of the previously reported 14 cases, nor in our case [2, 7, 25, 32]. Localized giant cell angitis was detected in one case [27]. The coexistence of an intracranial aneurysm and vascular variation is not uncommon [13, 15, 16, 34]. In the PICA dissecting aneurysms, fenestration of both vertebral arteries was observed in the present case. A trigeminal artery was observed in case 12. It is also of interest that dissecting aneurysms of the PICA originated on the left side in 12 out of 14 cases (1 bilaterally). This may be due to the general tendency of the left vertebral artery to predominate as in our patient. More than half of the distal PICA aneurysms in previous reports arose at a turning point of an artery rather than at a junction of vessels [21]. Research into the hemodynamics and histopathology of aneurysms should prove useful in elucidating the mechanism underlying their formation [3, 8, 24, 29].

Symptomatology

The most common symptom is headache, usually occipitalgia, which presented in nine cases, with four cases found to have an infarction. In all six cases

manifesting infarction, the dissecting portion was located at the origin or anterior medullary segment. Wallenberg's syndrome was noted in four cases. Among the eight cases manifesting SAH, the dissection involved the proximal portion in only three cases. Thus, it can be deduced that the dissecting aneurysms of the proximal PICA tend to cause infarctions while peripheral aneurysms tend to give rise to SAH.

Image Diagnosis

MRI was performed in five cases: case 9–11, 13 and the present case. T2WI demonstrated infarction in two cases. In case 10, angiography demonstrated neither a double lumen nor the retention of the contrast medium, whereas T1WI depicted an iso-intense false lumen around the signal void enhanced with gadolinium, which led to the diagnosis. MRI also revealed double lumens as in the present case. MRI which is a non-invasive image diagnosis modality should be the first investigative tool used in cases involving a possible dissecting aneurysm [23].

Treatment

Although measurement involving trapping and an anastomosis is often used to treat vertebral dissecting aneurysms, it has not been widely used to treat PICA dissecting aneurysms [4, 14, 19]. Among the eight cases treated surgically in whom the dissecting aneurysm had a proximal origin (origin, anterior medullary segment or lateral medullary segment), trapping using an anastomosis was performed in only two cases. A simple occlusion of the proximal PICA was done without anastomosis in five cases, which showed no post-surgical neurological deterioration after operation.

Was the anastomosis really necessary in the present case? Balloon occlusion test should have been performed to assess the necessity of an anastomosis. It seemed, however, dangerous to try it because the exact point where the dissection start was unclear. We were afraid that an enlargement of the cerebellar infarction caused by simple occlusion of the proximal PICA and peri-operative systemic circulatory "unsteadiness" might lead to mortality or severe morbidity [1, 5]. A slight enlargement of the infarcted area was indeed seen postoperatively, which eventually became asymptomatic. Therefore, OA-peripheral PICA anastomosis seems to be necessary to achieve a better surgical outcome for PICA dissecting aneurysms at the

present time. Further investigations of cerebellar blood flow dynamics in cases involving PICA aneurysm should resolve this issue.

References

1. Amerenco P, Hauw JJ (1990) Infarction in the territory of the medial branch of the posterior inferior cerebellar artery. *J Neurol Neurosurg Psychiatry* 53: 731–735
2. Berger MS, Wilson CB (1984) Intracranial dissecting aneurysms of the posterior circulation: report of six cases and review of the literature. *J Neurosurg* 61: 882–894
3. Bulbul MA, Farrow GA (1992) Renal artery aneurysms. *Urology* 40: 124–126
4. Durward QJ (1995) Treatment of vertebral artery dissecting aneurysm by aneurysm trapping and posterior inferior cerebellar artery reimplantation: case report. *J Neurosurg* 82: 137–139
5. Feely MP (1979) Cerebellar infarction. *Neurosurgery* 4: 7–11
6. Friedman AH, Drake CG (1984) Subarachnoid hemorrhage from intracranial dissecting aneurysm. *J Neurosurg* 60: 325–334
7. Grosman H, Fornasier VL, Bonder D, Livingston KE, Platts ME (1980) Dissecting aneurysm of the cerebral arteries: case report. *J Neurosurg* 53: 693–697
8. Higashi K, Hatano M, Yamashita T, Inoue S, Matsumura T (1979) Coexistence of posterior inferior cerebellar artery aneurysm and arteriovenous malformation fed by the same artery. *Surg Neurol* 12: 405–408
9. Hudgins RJ, Day AL, Quisling RG, Rhoton AL, Sybert GW, Garcia-Bengochea F (1983) Aneurysms of the posterior inferior cerebellar artery. *J Neurosurg* 58: 381–387
10. Jafer JJ, Kamiryo T, Chiles BW, Nelson PK (1998) A dissecting aneurysm of posteroinferior cerebellar artery: case report. *Neurosurgery* 43: 353–356
11. Kawaguchi S, Sakai T, Kamada K, Iwanaga H, Takehashi K, Tsujimoto M (1993) Dissecting aneurysm of the posterior inferior cerebellar artery: case report. *Neurol Med Chir (Tokyo)* 33: 634–637
12. Komiya H, Saeki N, Iwadate Y, Sunami K, Yamaura A (1988) Posterior inferior cerebellar dissecting aneurysm presenting with Wallenberg's syndrome. *Neurol Med Chir (Tokyo)* 28: 404–408 (in Japanese)
13. Kowada M, Takahashi M, Gito Y, Kishikawa T (1973) Fenestration of the vertebral artery: report of 2 cases demonstrated by angiography. *Neuroradiology* 6: 110–112
14. Lee SY, Sekhar LN (1996) Treatment of aneurysms by excision or trapping with arterial reimplantation or interpositional grafting. *J Neurosurg* 85: 178–185
15. Miyazaki M, Kamata K, Yamaura A (1980) Multiple aneurysms of the vertebrobasilar system associated with fenestration of the vertebral artery. *Surg Neurol* 15: 192–195
16. Mizukami M, Tomita T, Mine T, Mihar H (1972) Bypass anomaly of the vertebral artery associated with cerebral aneurysm and arteriovenous malformation. *J Neurosurg* 37: 204–209
17. Mizushima H, Sasaki K, Kunii N, Nishino T, Jinbo H, Abe T, Shimazu M, Matsumoto K (1994) Dissecting aneurysm in the proximal region of the posterior inferior cerebellar artery presenting as Wallenberg's syndrome: case report. *Neurol Med Chir (Tokyo)* 34: 307–310
18. Nagahiro S, Goto S, Yoshioka S, Ushio Y (1993) Dissecting aneurysm of the posterior inferior cerebellar artery. *Neurosurgery* 33: 739–741
19. Nagasawa S, Ohta T, Kajimoto Y, Tanaka H, Kawanishi M, Tada Y (1994) Giant thrombosed vertebral artery aneurysm treated by extracranial-intracranial bypass and aneurysmectomy: case report. *Neurol Med Chir (Tokyo)* 34: 311–314
20. Nishino A, Sakurai Y, Niizuma H, Satou H, Yoshiyama T (1991) Dissecting aneurysm of distal posterior inferior cerebellar artery: case report and review of the literature. *No to Shinkei* 43: 381–386 (in Japanese)
21. Nishizaki T, Tamaki N, Nishida Y, Fujita K, Matsumoto S (1985) Aneurysms of the distal posterior inferior cerebellar artery with three cases and review of the literature. *Neurosurgery* 16: 829–832
22. Pasqualin A, Pian RD, Scienza R, Licata C (1981) Posterior inferior cerebellar artery aneurysm in the fourth ventricle: acute surgical treatment. *Surg Neurol* 16: 448–451
23. Quint DJ, Spickler EM (1990) Magnetic resonance demonstration of vertebral artery dissection: report of two cases. *J Neurosurg* 72: 183–188
24. Roberts WC, Bethesda (1981) Aortic dissection: anatomy, consequences, and causes. *Am Heart J* 101: 195–214
25. Siegelbaum MH, Weiss JP (1990) Renal infarction secondary to fibrous dysplasia and aneurysm formation of renal artery. *Urology* 35: 73–75
26. Shinoda S, Murata H, Waga S, Kojima T (1998) Bilateral spontaneous dissection of the posteroinferior cerebellar arteries: case report. *J Neurosurg* 43: 357–359
27. Takahashi I, Takamura H, Gotou S, Sasaki H, Makino K, Suzuki N, Nishihara I, Ishikawa T, Andou M (1992) Dissecting aneurysms of the posterior inferior cerebellar artery: a case report. *No Shinkei Geka* 20: 277–281 (in Japanese)
28. Tikkakoski T, Leinonen S, Siniluoto T, Koivukangas J (1997) Isolated dissecting aneurysm of the left posterior inferior cerebellar artery: endovascular treatment with a Guglielmi detachable coil. *AJNR* 18: 939–938
29. Tognetti F, Limoni P, Testa C (1983) Aneurysm growth and hemodynamic stress. *Surg Neurol* 20: 74–78
30. Urbach H, Meyer B, Cedzich C, Solymosi L (1995) Posterior inferior cerebellar artery aneurysm in the fourth ventricle. *Neuroradiology* 37: 267–269
31. Ueki I, Teraoka A, Yoshida S, Hori T (1987) Dissecting aneurysm of the posterior cerebellar artery: a case report. *No Shinkei Geka* 15: 1215–1219 (in Japanese)
32. Watson AJ (1956) Dissecting aneurysm of arteries other than the aorta. *J Pathol Bacteriol* 72: 439–449
33. Yamaura A, Isobe K, Karasudani H, Tanaka M, Kamiya H (1991) Dissecting aneurysms of the posterior inferior cerebellar artery. *Neurosurgery* 28: 894–898
34. Zang QJ, Kobayashi S, Gibo H, Hongo K (1994) Vertebrobasilar junction fenestration associated with dissection aneurysm of intracranial vertebral artery. *Stroke* 25: 1273–1275

Correspondence: Yukari Kanou, M.D., Department of Neurosurgery, Hiroshima University School of Medicine, 1-2-3, Kasumi, Minami-ku, Hiroshima, Japan.