

Intrauterine subdural hemorrhage

Cigdem Inan Akman* MD, Chief Resident;
Joan Cracco MD, Professor of Neurology, Division of
Pediatric Neurology, State University of New York, Health
Science Center at Brooklyn, New York, USA.

*Correspondence to first author at Harvard Medical School,
Children's Hospital, Clinical Neurophysiology, 300
Longwood Avenue, Boston MA 02115, USA.
E-mail: akman@A1.harvard.tch.edu

Subdural hemorrhage (SDH) detected postnatally in the newborn infant is usually related to trauma at the time of vaginal delivery¹. With improvement in obstetric methods, the incidence of this problem has declined. However, with advances in obstetric ultrasonography, it has been recognized that SDH may occur *in utero* before the onset of delivery. Intrauterine SDH remains a rare event. A review of the literature revealed only 32 cases to date (Tables I and II). Neonatal SDH is venous in origin and associated with trauma in most cases. Etiopathogenesis of neonatal SDH is explained by shearing of bridging veins or other venous structures caused by trauma¹. Instrumental delivery (forceps or vacuum extraction) causes distortion of the infant's cranium with elongation of the falx and angulation of the tentorium, leading to tearing of posterior fossa venous structures and bleeding into the subdural space. Rupture or tearing of large venous channels, such as the great vein of Galen, straight or transverse sinus or falx laceration with rupture of the sagittal sinus, result in accumulation of blood in both the supratentorial and infratentorial compartments¹⁻³. However, etiopathogenesis of intrauterine SDH is less certain. The fetus is usually well protected from direct abdominal trauma by maternal structures and amniotic fluid. Fetal intracranial vessels may be susceptible to shearing or acceleration/deceleration forces because of the following features: first, the head is large and neck muscles weak; this allows more rotational movement with angular acceleration. Second, the subarachnoid space is larger, allowing the brain to move within the cranium easily. Third, the fetal brain has a higher water content that increases its mass and allows it to develop more momentum when acceleration is applied^{3,4}. These unique conditions could make the fetus more susceptible to developing subdural hematomas and allow the development of subdural hematomas without obvious trauma.

Maternal trauma such as falls, assaults, or motor vehicle accidents, is the best-documented cause of SDH in the fetus before the onset of labor^{1,4}. Although trauma to the fetal head is the most common factor involved in intrauterine SDH, consideration should be given to other potential contributing factors such as fetal or maternal thrombocytopenia^{5,6}, coagulopathies secondary to hemophilia⁷⁻⁹, hepatic disease or hydrops fetalis⁶, and intrauterine infections or

sepsis with disseminated intravascular coagulopathy^{8,10}. Exposure to various drugs, especially aspirin and other anti-coagulants¹¹, and congenital vascular malformation¹² have also been reported in association with fetal SDH (see Table II). It should be noted, however, that abnormalities of the complete blood count and coagulation profile may not be primary but secondary to consumption of blood and clotting factors within an expanding intracranial hematoma.

In our case, fetal SDH occurred without any evidence of obvious causes or predisposing risk factors (see case report below). This condition is defined as spontaneous intrauterine SDH¹²⁻¹⁸. There are only seven reported cases of intrauterine spontaneous SDH in the world literature in addition to our own (see Table I). Mac Donald reported the first case of spontaneous intrauterine SDH in 1977¹³. Of the five other case reports of spontaneous intrauterine SDH, two were stillborn^{16, 18}; two died in the early neonatal period^{14, 17}, and only one had normal development¹² (see Table I). Gunn performed postmortem studies on 20 stillborn infants with unexplained intracranial hemorrhage delivered by mothers from the Pacific Islands¹⁹. He observed that all stillborn infants died unexpectedly before the onset of labor and had various degrees of intracranial hemorrhages. A subdural component was noted in 16 infants, half were located bilaterally. Hemosiderin deposition confirmed that the hemorrhages occurred before death *in utero*. Although etiology was unknown, the possibility of trauma was considered because of the history of abdominal massage to pregnant woman by traditional Pacific Islander healers. Subsequently, he reported three live-born infants with unexplained intrauterine SDH¹⁴. Due to the mothers of these two newborn infants also being immigrants from Pacific Islands, the same risk factor was considered as a cause of intrauterine SDH in those cases as well.

CASE REPORT

We recently encountered a neonate with extensive unilateral SDH present before delivery. This male infant was delivered by Cesarean section at 34 weeks' gestation because of fetal distress and suspected hydrocephalus. Obstetric sonogram at 28 weeks' gestation was normal, but a subsequent scan at 32 weeks' gestation was reported as showing hydrocephalus. The

mother stated that there had been no trauma, infection, or drug ingestion. Her prothrombin time (PT)/partial prothrombin time (PTT), platelet count, Hb, and hematocrit (Hct) were normal. Apgar scores were 9 and 9 at 1 and 5 minutes, respectively. The child's head circumference was 35.5 cm (>95th centile); the anterior fontanel was slightly bulging. No lacerations or hematomas were noted. He was active and alert. Right-sided ptosis and a mild left hemiparesis were present. Initial laboratory data showed the following: Hb 10 gr/dL, Hct 35%, plt 256/cu mm. PT was 16.5 seconds (12 to 21 s for preterm baby) and PTT was 58.3 s (70 s for preterm baby). Head CT on day 1 showed a right-sided extensive SDH with marked midline shift and transtentorial herniation (Fig. 1a). Burr holes were performed and 85 cc of 'motor oil' type subdural fluid was drained. Over the next 24 hours, an additional 65 cc was drained. The anterior fontanel became depressed

and the head circumference reduced to 34 cm. At 4 days of life, external drainage was discontinued. Head circumference remained stable. At 13 days, CT showed minimal subdural collection without midline shift. Repeat blood count, PT, thrombin, PTT, and fibrinogen were normal. TORCH studies, blood, and urine cultures were negative. The etiology of SDH was unknown. The infant's development, assessed at 2 and 4 months, was normal. At 11 months of age, he had three brief generalized seizures. An EEG revealed spikes over the left hemisphere with slow background activity. Neurological examination was normal except for questionable speech delay. A repeat CT showed chronic right residual subdural effusion and minimal atrophy of the left hemisphere with left periventricular leukomalacia (Fig. 1b). At present the child is 2½ years old and has moderate speech delay. His seizures are controlled with phenytoin.

Table I: Spontaneous subdural hemorrhages

Authors	n	Gestation (wk)	Apgar 1,5 min	Clinical signs	CT findings		CBC	Therapy	Outcome
					Site	Location			
Mac Donald 1977 ¹³	1	38	2, 6	Lethargy	BL	Convexity	Normal	Subdural tap	Hypotonia at 6 mo
Gunn 1985 ¹⁴	1	42	9, 9	L, ptosis	L	Convexity	Normal	Subdural tap	Died at 3rd day
Mateos 1987 ¹⁵	1	35	7, 9	Hypotonia	R	Convexity	Normal	Surgical evacuation	Died at 14th day
Demir 1989 ¹⁸	1	33	–	–	L	Convexity	–	–	Stillbirth
Nougeria 1992 ¹⁵	1	37	9, 10	Macrocephaly	L	Convexity	Normal	Surgical evacuation	Spastic diplegia Moderate developmental delay
Kawabata 1993 ¹⁶	1	35	–	–	R	Convexity	–	–	Stillbirth at 35 wk
Sohda 1996 ¹²	1	37	8, 10	Macrocephaly	R	Convexity Post fossa	Normal	Subdural tap	Normal at 13 mo

CBC, complete blood count; L, left; R, right; BL, bilateral; post, posterior; –, not available.

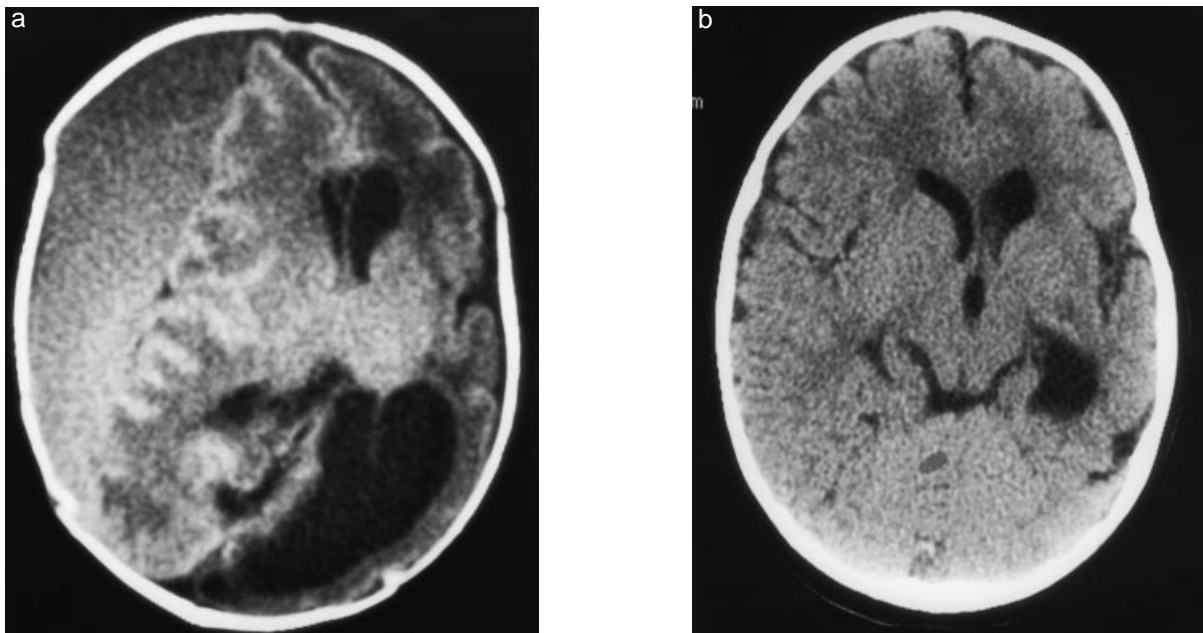


Figure 1: (a) CT without intravenous contrast taken immediately after birth showing large right isodense subdural hemorrhage with midline shift and transtentorial herniation. (b) At 11 months of age, minimal right chronic subdural collection and diffuse tissue loss of left cerebral hemisphere are present. Note paucity of white matter at left posterior cerebral hemisphere compatible with periventricular leukomalacia.

CLINICAL ASPECTS

The two principal locations of SDH in the fetus and newborn infant are over the cerebral hemisphere and posterior fossa¹. Review of the literature showed that SDH in the fetus appeared to be more common supratentorially rather than infratentorially, which is opposite to SDH in the newborn infant due to traumatic delivery (see Table I and II). Clinical presentation depends on the size and localization of the hemorrhage i.e. the degree to which it is confined to one area. Large SDHs, especially in the posterior fossa, cause focal neurological symptoms and signs at an early stage due to increased intracranial pressure and brain-stem compression²¹⁻²³. Massive hemorrhage may be associated with shock, coma, and rapid demise. In contrast, infants with small hemorrhages may have mild symptoms or no symptoms at all. Asymptomatic increased head size might be the only finding either pre and/or postnatally. Therefore, SDHs should be included in the differential diagnosis of macrocephaly at birth (see Table I and II). As small asymptomatic SDHs may not be detected, it is difficult to determine the incidence of intrauterine SDH accurately.

Owing to improvements in *in utero* imaging techniques, smaller SDHs have been recognized more frequently in recent years^{1,9}. The ultrasonogram may give a false negative or an erroneous result. In our case, the sonogram was interpreted as showing hydrocephalus and SDH was not suspected. However, fetal hydrocephalus is not surprising in association with intrauterine SDH^{5, 11, 24}. Ultrasonographic demonstration of increase in ventricular size associated with or without an abnormal intracranial mass should encourage further diagnostic imaging. Either the study should be repeated or other imaging techniques should be used until the intracranial structures are clearly delineated. CT and MRI¹⁶ provide better visualization of the distribution and

extension of intracranial hemorrhages in both the prenatal and neonatal period. MRI is better for posterior fossa SDH because it delineates the posterior fossa elements more effectively than a CT scan. Advanced neuroimaging techniques also provide the advantage of estimating the age of the hemorrhage to delineate underlying causes.

MANAGEMENT AND OUTCOME

In the absence of extensive experience with intrauterine SDH, it is essential to optimize close antenatal follow up and delivery management in the expectation of fetal survival. Cesarean section may be necessary because of considerable head enlargement. After birth, as in the cases of postnatal SDH, the localization and extension of hemorrhage and the clinical condition of the newborn infant are the essential factors in deciding on surgical or conservative management. Review of the literature on all SDHs and our patient demonstrate that prompt treatment is indicated in patients who present with increased intracranial pressure and clinical deterioration^{5-7, 12, 14}. Surgery can be life saving when there are signs and symptoms of brain-stem dysfunction.

Indications for surgery in the case of posterior fossa SDH, outlined by Tanaka and Govaert² are: (1) signs of brain-stem compression; (2) acute obstructive hydrocephalus with raised intracranial pressure; (3) a posterior fossa clot > 15 cm. There should be no delay if the newborn infant has clear neurological deterioration. If the posterior fossa hemorrhage is small and not expanding surgical intervention is not necessary. On the other hand, acute convexity SDH requires careful observation². Surgery is not mandatory if the infant remains neurologically stable. Subdural taps can be used to reduce intracranial pressure. However, surgery should be considered in the presence of a large hemorrhage, if there are signs of increased intracranial pressure and neurological deficits

Table II: Intrauterine subdural hemorrhages with risk factors

Authors	n	Risk	Gestation (wk)	Apgar 1,5min	Clinical signs	CT findings		CBC	Therapy	Prognosis
						Site	Location			
Robinson 1980 (11)	1	Warfarin (mother)	34	-	Shock	BL	Convexity	-	Supportive therapy	Died at 3 hr
Gunn 1984 (19)	16	Abdominal massage	-	-	-	BL	Convexity (n=8)	-	-	Stillbirth
Gunn 1985 (14)	1	Abdominal massage	40	7,8	Macrocephaly	BL	Covexity	Normal	-	Quadriparesis
	1	Abdominal massage	41	5,8	Macrocephaly	BL	Convexity	Normal	Surgical evacuation	Microcephaly Developmental delay
Hanigan 1985 (6)	1	Coagulopathy Hydrops	38	6,5	Hydrops	BL	Covexity	Abnormal PT/PTT	Subdural tap	Normal at 3 mo
Atluru 1987 (5)	1	Low PLT	43	9,10	Macrocephaly R hemiparesis	BL	Convexity	Low PLT	Subdural tap	Spastic quadriparesis
De Sousa 1988 (7)	1	Factor X deficiency	37	-	-	L	Covexity	Abnormal PT/PTT	Subdural tap Fresh frozen plasma	Normal development Died at 7 mo from acute hemorrhage
Rotmensch 1991 (8)	1	Coagulopathy	37	3,5	Macrocephaly	BL	Convexity Post fossa	Abnormal PT/PTT	Supportive therapy	Died at 6 hr
Catanzarite 1995 (20)	1	Asphyxia	28	-	-	BL	Covexity	Anemia	Supportive therapy	Stillbirth
Barozzino 1998 (9)	1	Maternal factor XI deficiency	30	8,9	-	BL	Convexity	Normal	Spontaneous resolution	Normal at 9 mo

CBC, complete blood count; PT, prothrombin time; PTT partial prothrombin time; PLT, platelet; -, not available.

indicating transtentorial herniation^{2, 25}.

Prognosis of the fetus affected by SDH is dependent on the severity of the hemorrhage and the underlying cause. The prognosis has generally been poor both in the cases of SDH with known risk factors and in the group with spontaneous SDH (see Table I and II). Of the 32 reported cases of intrauterine SDH, only 13 of the affected infants were live-born^{2-6, 8-11, 13, 15}. Four of these infants died during the neonatal period^{8, 11, 14, 17}, five had neurological impairment^{3, 13-15}, and four had normal development^{6, 7, 9, 12}.

Unfortunately, there is no information on long-term follow-up of these individuals. It is of interest that spontaneous intrauterine resolution of SDH was observed in one infant⁹.

Conclusion

Etiology of intrauterine SDH is unknown in many cases. With wider use and improved obstetric imaging techniques, intrauterine SDHs are being recognized more often. Ultrasonography, along with other imaging modalities may help in identifying specific etiology and defining optimal management of this problem. Early diagnosis and appropriate treatment should improve survival and minimize brain damage in these newborn infants. Optimal management and outcome of these infants will require close cooperation between obstetricians, neonatologists, neurologists, and neurosurgeons.

References

- Volpe JJ. (1995) Intracranial hemorrhage: subdural, primary subarachnoid, intracerebellar, intraventricular (term infant), and miscellaneous. In: Volpe JJ, editor. *Neurology of the Newborn*. Philadelphia: WB Saunders. p 373-402.
- Hayashi T, Hashimoto T, Fukuda S, Oshima Y, Moritaka K. (1987) Neonatal subdural hematoma secondary to birth injury. *Child's Nervous System* 3: 23-9.
- Brown JK, Minns RA. (1993) Non-accidental head injury, with particular reference to whiplash shaking injury and medico-legal aspects. *Developmental Medicine & Child Neurology* 35: 849-69.
- Stephens RP, Richards AC, Lewin JS. (1997) Bilateral subdural hematomas in a newborn infant. *Pediatrics* 99: 619-21.
- Atluru VL, Kumar IR (1987) Intrauterine chronic subdural hematomas with postoperative tension pneumocephalus. *Pediatric Neurology* 3: 306-9.
- Hanigan WC, Ali MB, Cusack TJ, Miller TC, Shah JJ. (1985) Diagnosis of subdural hemorrhage in utero. *Journal of Neurosurgery* 63: 977-9.
- De Sousa C, Clark T, Bradshaw A. (1988) Antenatally diagnosed subdural hemorrhage in congenital factor X deficiency. *Archives Disease of Childhood* 63: 1168-74.
- Rotmensch S, Grannum PA, Nores J, Hall C, Keller MS, Mc Carthy S, Hobbins JC. (1991) In utero diagnosis and management of fetal subdural hematoma. *American Journal of Obstetric and Gynecology* 164: 1246-8.
- Barozzino T, Sgro M, Toi A, Akouri H, Wilson S, Yeo E, Blaser S, Chitayat D. (1998) Fetal bilateral subdural hemorrhages. Prenatal diagnosis and spontaneous resolution by the time of delivery. *Prenatal Diagnosis* 18: 496-503.
- Ng PC, Fok TF, Lee CH, Wong W, Cheung KL. (1998) Massive subdural hematoma: an unusual complication of septicemia in preterm very low birth weight infants. *Journal of Pediatric Child Health* 34: 296-8.
- Robinson MJ, Cameron MD, Smith MF, Ayers AB. (1980) Fetal subdural hemorrhages presenting as hydrocephalus. *British Medical Journal* 281: 35.
- Sohda S, Hamada H, Takanami Y, Kubo T. (1996) Prenatal diagnosis of fetal subdural hematomas. *British Journal of Obstetric and Gynaecology* 103: 89-90.
- Mac Donald JT, Weitz R, Sher PK. (1977) Intrauterine chronic subdural hematoma. *Archives of Neurology* 34: 777-8.
- Gunn TR, Mok PM, Becroft DMO. (1985) Subdural hemorrhage in-utero. *Pediatrics* 76: 605-9.
- Nogueira GJ. (1992) Chronic subdural hematoma in utero: report of a case with survival after treatment. *Child's Nervous System* 8: 462-4.
- Kawabata I, Imai A, Tamaya T. (1993) Antenatal subdural hemorrhage causing fetal death before labor. *International Journal of Gynecology and Obstetrics* 43: 57-60.
- Mateos F, Esteban JT, Martin-Puerto MJ, Ozaita G, Martinez-Portillo J. (1987) Fetal subdural hematoma: diagnosis in utero. *Pediatric Neuroscience* 13: 125-8.
- Demir RH, Gleicher N, Myers SA. (1989) Atraumatic antepartum subdural hematoma causing fetal death. *American Journal of Obstetric and Gynecology* 160: 619-20.
- Gunn TR, Becroft DMO. (1984) Unexplained intracranial hemorrhage in utero: the battered fetus? *Australian and New Zealand Journal of Obstetrics and Gynecology* 24: 17-22.
- Catanzarite VA, Schrimmer DB, Maida C, Mendoza A. (1995) Prenatal sonographic diagnosis of intracranial hemorrhage: report of a case with a sinusoidal fetal heart rate tracing, and review of the literature. *Prenatal Diagnosis* 15: 229-35.
- Margalith D, Mogilner BM, Gadoth N. (1980) Posterior fossa subdural hematoma in a normally delivered, full term newborn. *Surgical Neurology* 14: 405-9.
- Huang CC, Shen EY. (1991) Tentorial subdural hemorrhage in term newborns: Ultrasonographic diagnosis and clinical correlates. *Pediatric Neurology* 7: 171-7.
- Perrin RG, Rutka JT, Drake JM, Meltzer H, Hellman J, Jay V, Hoffman HJ, Humphreys RP. (1997) Management and outcomes of posterior fossa subdural hematomas in neonates. *Neurosurgery* 40: 1190-200.
- Gunn TR, Mora JD, Becroft DMO. (1988) Congenital hydrocephalus secondary to prenatal intracranial hemorrhage. *Australian and New Zealand Journal of Obstetrics and Gynecology* 28: 197-200.
- Hernansanz J, Munoz F, Rodriguez D, Soler C, Principe C. (1984) Subdural hematomas of the posterior fossa in normal-weight newborns. *Journal of Neurosurgery* 61: 972-4.