

## BRIEF REPORT

Chien-Liang Chen · Yee-Hsuan Chiou · Chan-Yao Wu  
Ping-Hong Lai · Hsiao-Min Chung

## Cerebral vasculitis in Henoch-Schönlein purpura: a case report with sequential magnetic resonance imaging changes and treated with plasmapheresis alone

Received: 15 February 2000 / Revised: 30 July 2000 / Accepted: 1 August 2000

**Abstract** Neurological complications are rare during the course of Henoch-Schönlein purpura (HSP). We report a 7-year-old girl with HSP who presented with seizures, loss of vision and disturbance of consciousness. Magnetic resonance imaging (MRI) showed high signal intensity in the gray and white matter over the left parietal and both occipital lobes, compatible with MRI findings of cerebral vasculitis. The eye fundi revealed multiple branches of retinal artery occlusion. Intravenous pulse methylprednisolone (MTP) followed by oral steroid therapy was initially administered for HSP nephritis. Cerebral vasculitis developed 10 days post-MTP treatment, with progressive worsening of consciousness. Oral steroid was discontinued and plasmapheresis was performed alone. Her level of consciousness dramatically improved after plasmapheresis. The brain MRI and eye fundi findings were consistent with her clinical improvement. To the best of our knowledge, this is the first description of MRI abnormalities and multiple retinal artery branch occlusion of cerebral vasculitis in a patient with HSP that was successfully treated by plasmapheresis alone. In conclusion, we propose that plasmapheresis may be used as a first-line therapy or rescue therapy for cerebral vasculitis in HSP.

**Key words** Henoch-Schönlein purpura ·  
Methylprednisolone · Magnetic resonance imaging

C.-L. Chen · H.-M. Chung  
Division of Nephrology, Department of Internal Medicine,  
Veterans General Hospital,  
Kaohsiung, Taiwan 813, Republic of China

Y.-H. Chiou (✉) · C.-Y. Wu  
Division of Nephrology, Department of Pediatrics,  
Veterans General Hospital, 386, Ta-Chung First Road,  
Kaohsiung, Taiwan 813, Republic of China  
e-mail: cclchen@isca.vghks.gov.tw or cclchen@pavo.seed.net.tw  
Tel.: +886-7-34222121, ext. 2044, Fax: +886-6-2004767

P.-H. Lai  
Department of Diagnostic Radiology, Veterans General Hospital,  
Kaohsiung, Taiwan 813, Republic of China

### Introduction

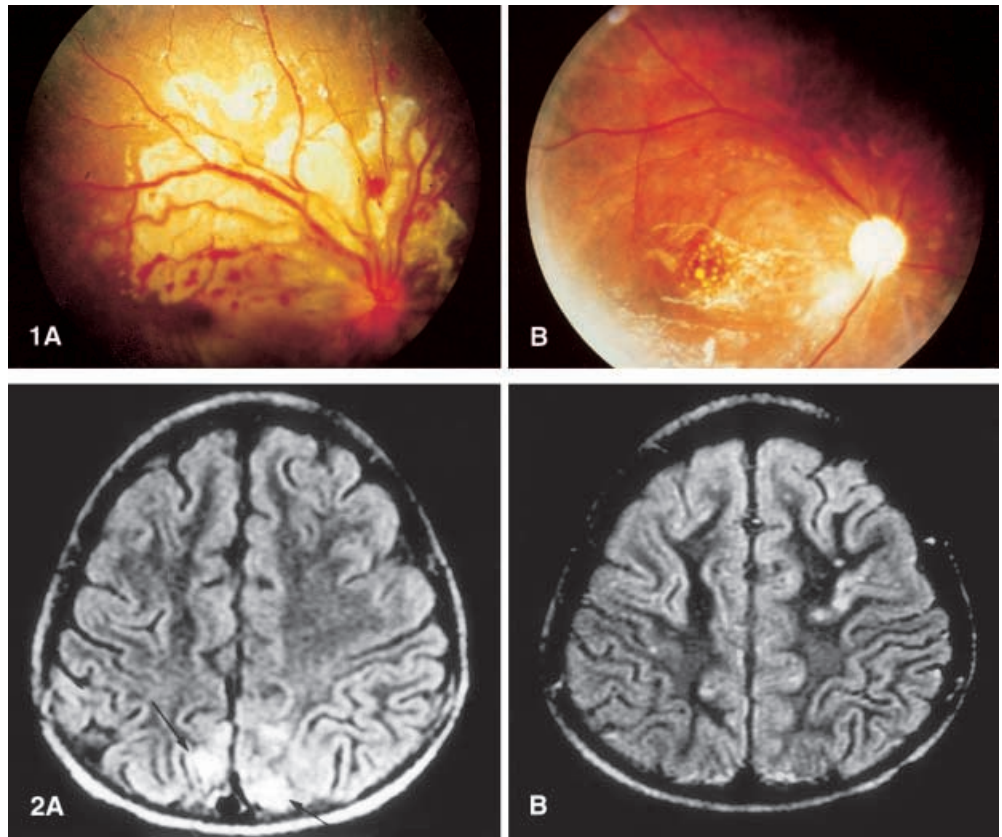
Henoch-Schönlein purpura (HSP) is a clinical syndrome characterized by multiple organ involvement including the gastrointestinal tract, skin, synovial membrane and kidney. Neurological manifestations are rarely encountered. Hypertensive encephalopathy, uremic encephalopathy, steroid, cytotoxic drugs, cerebral vasculitis and electrolyte imbalance are other possible causes of neurological manifestations of HSP [1, 2]. The literature to date [3, 4] has reported cerebral vasculitis in HSP and has suggested using magnetic resonance imaging (MRI) for diagnosis of cerebral vasculitis. Pulse methylprednisolone (MTP) therapy, triple therapy (oral steroid, cytotoxic drugs and antiplatelet drugs) [5, 6] and plasmapheresis [7] have been reported to be effective in purpuric nephritis. Pulse MTP with or without plasmapheresis [3, 4, 8] has been reported for treatment of cerebral vasculitis. We report a girl with cerebral vasculitis who improved dramatically after plasmapheresis.

### Case report

A 7-year-old girl was sent to our hospital with multiple petechiae over her lower extremities and buttock for 2 weeks. She had periumbilical pain, poor appetite and arthralgia. Her mother denied her having had a remarkable history, except for upper respiratory tract symptoms.

On admission, her vital signs were as follows: blood pressure 140/80 mmHg, pulse rate 100/min and body temperature 36.8°C. Positive physical findings included multiple erythematous purpura and induration of skin over her extremities, and buttock. Initial laboratory studies showed a white blood cell (WBC) count of 6360/mm<sup>3</sup>, hemoglobin of 8.6 g/dl and a platelet count of 423,000/mm<sup>3</sup>. Biochemical studies revealed blood urea nitrogen to be 15 mg/dl, creatinine 0.6 mg/dl, C-reactive protein (CRP) 0.36 mg/dl and IgA 361 mg/dl. Serological studies were negative for antinuclear antibody (ANA). Urinalysis revealed 0–2 red blood cells (RBC)/high power field (HPF), 1–3 WBCs/HPF and absence of protein and urinary casts. A panendoscopy showed multiple erythematous lesions in the duodenum, compatible with HSP [9]. Prednisolone (1 mg/kg) was administered for abdominal pain and naproxen was given for arthralgia. Due to marked symptomatic improvement, she was discharged.

**Fig. 1 A** Eye fundi findings show multiple retinal artery branch occlusion at the first diagnosis of cerebral vasculitis. **B** Eye fundi findings show improvement after plasmapheresis 40 days after onset of symptoms



**Fig. 2 A** Axial magnetic resonance fluid attenuated inversion recovery images (TR 9002 ms, TE 133 ms, TI 2200 ms, slice thickness 5 mm, average 2) demonstrate high-signal abnormalities (arrows) affecting the cortex and subcortical white matter of occipital lobes bilaterally. **B** Axial magnetic resonance fluid attenuated inversion recovery images (TR 9002 ms, TE 133 ms, TI 2200 ms, slice thickness 5 mm, average 2) performed 40 days after onset of symptoms show resolution of cerebral lesions

Two weeks after discharge, she was sent to our hospital again due to hematuria, arthralgia and edema of her lower legs. Laboratory studies revealed the following: serum albumin 1.9 g/dl, blood urea nitrogen 21 mg/dl, creatinine 0.9 mg/dl, triglycerides 348 mg/dl, cholesterol 322 mg/dl, white blood cell count 18,280/mm<sup>3</sup>, hemoglobin 9.4 g/dl and platelet count 498,000/mm<sup>3</sup>. The urinalysis showed protein >300 mg/dl, numerous RBCs/HPF and 15–18 WBCs/HPF. The CRP was 1.4 mg/dl, IgA was 239 mg/dl and ANA was negative. HSP nephritis was diagnosed. Renal biopsy revealed 25% crescent glomerulonephritis, normal interstitium and vessels. Unfortunately, immunofluorescent studies could not be done because there was no glomerulus. Electron microscopy disclosed the presence of electron-dense sub-epithelial and mesangial deposits. Pulse MTP therapy (30 mg/kg) was given for 3 days and subsequent oral prednisolone (2 mg/kg) was maintained for treatment of HSP nephritis.

Persistent oliguria with acute pulmonary edema developed, and hemodialysis was performed 8 and 9 days after pulse MTP. However, an acute focal seizure, headache, and intermittent loss of vision and of consciousness developed 10 days after pulse MTP. Blood urea nitrogen level was 45 mg/dl and serum creatinine level was 4 mg/dl. She was intubated with ventilation. Dilantin was administered for control of seizure and her blood pressure was controlled around 130/80 mmHg. On fundoscopic examination (Fig. 1A), there was no evidence of hypertensive retinopathy, but multiple branches of retinal artery occlusion were compatible with vasculitis. Emergent brain computed tomography was negative. MRI of the brain demonstrated an area of increased signal intensity in the left parietal lobe and bilateral occipital area (Fig. 2A) consistent with ischemia or demyelinations. Examination of the cerebrospinal fluid revealed 4 WBCs/mm<sup>3</sup> and 570 RBCs/mm<sup>3</sup>, with normal levels of protein, sugar and cerebrospinal pressure. The electroencephalogram showed continuous slowing of background activity with large amplitude, without epileptiform discharges. A diagnosis of cerebral vasculitis was made. Because of intermittent seizures and disturbance of consciousness during the subsequent 3

weeks, oral steroid was discontinued and plasmapheresis was given alone, with a volume of 50 ml/kg body weight of plasma exchange. The substitution solution was fresh frozen plasma. The plasma exchange regimen consisted of a thrice-weekly regimen for 2 weeks, then once weekly treatment for 6 weeks.

After two sessions of plasmapheresis, she regained consciousness and had no further seizures. Sequential brain MRI (Fig. 2B) was performed 40 days after the first seizure, and showed improvement of previous brain lesions. Her eye fundi (Fig. 1B) and renal function were also improved. Serum chemistry values were creatinine 0.9 mg/dl, blood urea nitrogen 13 mg/dl and 24-h urine protein excretion 8 g. Her neurological examination was normal.

## Discussion

HSP is an autoimmune hypersensitivity vasculitis that results in clinical symptoms, including a purpuric rash on the lower extremities, abdominal pain or renal involvement and arthritis. Neurological involvement in HSP has rarely been reported [1–4]. Hypertensive encephalopathy, uremic encephalopathy, electrolyte imbalance and cerebral vasculitis were contributing factors. The diagnosis of cerebral vasculitis is difficult since neurological abnormalities in HSP can be caused by multiple factors.

According to the previous literature [3, 4], MRI was the modality of choice for diagnosis of cerebral vasculitis because of its high sensitivity. Two major reversible cerebral pathologic processes thought to result from derangement in vascular autoregulatory dysfunction in-

clude uremic encephalopathy and a reversible posterior leukoencephalopathy syndrome [4, 10, 11]. In uremic encephalopathy, the imaging study frequently shows negative findings even in the presence of neurological symptoms. When images are abnormal, T2-weighted images typically reveal increased signal intensity involving basal ganglia with extension into the internal and external capsule bilaterally [10]. The reversible posterior leukoencephalopathy syndrome includes hypertensive encephalopathy, preeclampsia and eclampsia, and immunosuppressive therapy. They are characterized by mainly symmetrical white matter lesions with or without cortical involvement, mostly in the posterior parietal-temporal-occipital regions of the brain [10, 11]. The clinical neurological abnormalities are headache, mental status changes, seizures and visual loss. The neuroimaging and clinical manifestations of our patient were less likely to arise from uremic encephalopathy, but were more compatible with a reversible posterior leukoencephalopathy syndrome.

Our patient demonstrated acute focal seizures and blurred vision and fell into a comatose state. However, her blood pressure and electrolytes were within the normal range. The findings on MRI in our patient were not compatible with uremic encephalopathy. Her eye fundi demonstrated multiple branches of retinal artery occlusion, compatible with vasculitis (Fig. 1A). Although she had renal function impairment, we believe that vasculitis was the major contributing factor.

HSP is caused by small vessel vasculitis, possibly IgA mediated. Treatment of vasculitis with steroids acts by inhibiting inflammation. However, steroid has unfavorable side effects of thrombosis and vasoconstriction [12]. Plasmapheresis is thought to act primarily by rapid clearance of specific disease-associated factors and possible desaturation of the mononuclear phagocytic system. The clearance is more rapid than that achievable with intravenous or oral immunosuppressants.

According to the previous literature on cerebral vasculitis in HSP, pulse methylprednisolone therapy provided effective relief of cerebral vasculitis. One report [8] showed that three patients with central nervous system manifestations recovered after plasma exchange and steroids. This patient remained comatose despite high dose oral steroid. However, after plasma exchange, her level of consciousness improved dramatically. To the best of our knowledge, this is the first description of MRI ab-

normalities and multiple retinal artery branch occlusion of cerebral vasculitis in patients with HSP that were successfully treated by plasmapheresis. Based on our experience, we conclude that plasmapheresis may be more effective than high dose oral steroid therapy for the prevention and treatment of cerebral vasculitis in HSP.

In conclusion, although cerebral vasculitis is rare in HSP, it should be considered in all cases of HSP with neurological manifestations. We suggest that plasmapheresis could be used as the first-line therapy or rescue therapy for cerebral vasculitis in HSP. MRI is more sensitive than computed tomography and is the modality of choice for diagnosis and evaluation of cerebral vasculitis in HSP.

---

## References

1. Belman AL, Leicher CR, Moshe SL, Mezey AP (1985) Neurologic manifestations of Schoenlein-Henoch purpura: report of three cases and review of the literature. *Pediatrics* 75:687-692
2. Moore PM, Cupps TR (1983) Neurological complications of vasculitis. *Ann Neurol* 14:155-167
3. Ha TS, Cha SH (1996) Cerebral vasculitis in Henoch-Schönlein purpura: a case report with sequential magnetic resonance imaging. *Pediatr Nephrol* 10:634-632
4. Woolfenden AR, Hukin J, Poskitt KJ, Connolly MB (1998) Encephalopathy complicating Henoch-Schonlein purpura: reversible MRI changes. *Pediatr Neurol* 19:74-78
5. Szer IS (1996) Henoch-Schönlein purpura: when and how to treat. *J Rheumatol* 23:1661-1665
6. Rieu P, Noel LH (1999) Henoch-Schönlein nephritis in children and adults. *Ann Intern Med* 150:151-158
7. Hattori M, Ito K, Konomoto T, Kawaguchi H, Yoshioka T, Khono M (1999) Plasmapheresis as the sole therapy for rapid progressive Henoch-Schönlein purpura nephritis in children. *Am J Kidney Dis* 33:427-432
8. Gianviti A, Trompeter RS, Barratt TM, Lythgoe MF, Dillon MJ (1996) Retrospective study of plasma exchange in patients with idiopathic rapidly progressive glomerulonephritis and vasculitis. *Arch Dis Child* 75:186-190
9. Nathan K, Gunasekaran TS, Berman JH (1999) Recurrent gastrointestinal Henoch-Schönlein purpura. *J Clin Gastroenterology* 29:86-89
10. Port JD, Beauchamp NJ Jr (1998) Reversible intracerebral pathologic entities mediated by vascular autoregulatory dysfunction. *Radiographics* 18:353-367
11. Hinchey J, Chaves C, Appignani B, Breen J, Pao L, Wang A, Pessin MS, Lamy C, Mas JL, Caplan LR (1996) A reversible posterior leukoencephalopathy syndrome. *N Engl J Med* 334:494-500
12. Conn DL, Tompkins RB, Nichols WL (1988) Glucorticoids in the management of vasculitis - a double edged sword? *J Rheumatol* 15:1181-1183