

De novo mutation in the mitochondrial tRNA^{Leu(UUR)} gene (A3243G) with rapid segregation resulting in MELAS in the offspring

CH KO,¹ CW LAM,² PWT TSE,¹ CK KONG,¹ AKH CHAN¹ and LJC WONG³

¹Department of Paediatrics, Caritas Medical Centre, Hong Kong, ²Department of Chemical Pathology, The Chinese University of Hong Kong, Hong Kong, China and ³Molecular Diagnostic Laboratory, Institute for Molecular and Human Genetics, Georgetown University Medical Center, Washington DC, USA

Abstract: A 14-year-old Chinese boy with a normal perinatal and early developmental history presented at 5 years of age with migraine, intractable epilepsy, ataxia, supraventricular tachycardia, paralytic ileus and progressive mental deterioration. Computerized tomography revealed multiple cerebral infarcts in the parieto-occipital region without basal ganglial calcification. Magnetic resonance imaging showed increased signal intensity in T2 weighted images in the same regions. A cerebral digital subtraction angiogram was normal. Venous lactate, pyruvate, lactate to pyruvate ratio and cerebrospinal fluid lactate were elevated. Muscle biopsy did not reveal any ragged red fibres; dinucleotide–tetrazolium reductase activity was normal. Mitochondrial DNA analysis detected an adenine to guanine mutation at nucleotide position 3243 of tRNA^{Leu(UUR)}. All four tissues analysed demonstrated heteroplasmy: leucocyte 56%, hair follicle 70%; buccal cell 64%; muscle 54%. The mother and brother of the proband, both asymptomatic, were also found to have a heteroplasmic A3243G mutation in the leucocytes, hair follicle and buccal cells. Other members of the maternal lineage, including the maternal grandmother, did not have the mutation. This report describes a patient with mitochondrial encephalopathy, lactic acidosis, stroke-like episodes, who presented with multisystem involvement. The absence of ragged red fibres in muscle biopsy did not preclude the diagnosis. Mutational analysis of mitochondrial DNA conveniently confirmed the diagnosis of the disorder. A *de novo* mutation is demonstrated in this family.

Key words: *de novo* mutation; mitochondrial encephalomyopathies; mitochondrial encephalopathy; lactic acidosis; stroke-like episodes syndrome.

Mitochondrial encephalomyopathy, lactic acidosis, and stroke-like episodes (MELAS) were described as forming a distinct syndrome by Pavlakis *et al.*¹ in 1984. Subsequent reports have revealed that this maternally inherited disorder is associated with defects in the respiratory chain enzymes, particularly complex I.² Eighty per cent of cases are associated with an adenine to guanine base substitution in the gene encoding tRNA^{Leu(UUR)} at nucleotide (nt) position 3243 in the mitochondrial DNA.^{3–5} MELAS is a maternally inherited disorder, and the A3243G mutation is often detected in other asymptomatic or oligosymptomatic relatives of the maternal lineage.^{6–8} *De novo* mutation is seldom reported.^{9,10} In this report, this mutation was analysed in seven family members of a MELAS pedigree. Transmission from the mother to the proband and his asymptomatic sibling was detected. However, the mutation was not detected in the maternal grandmother and the other siblings of the mother. This suggests that the mother of the index patient is the carrier of the *de novo* A3243G mutation, with rapid segregation and high levels of mutant mitochondrial (mt) DNA detected in her offspring. To our knowledge, this is the first report of a *de novo* mutation occurring in Chinese MELAS families.

CASE REPORT

The patient (III1) was a 14-year-old Chinese boy with a normal prenatal, perinatal and early developmental history. He enjoyed good health and had normal development until the age of 5.5 years, when he experienced intermittent migraine-like headache with colour vision changes and vomiting. At age 7 years, he was admitted to hospital for left-sided focal convulsions with secondary generalization. Phenobarbital treatment was started with only temporary improvement. The epilepsy became intractable and various anticonvulsants (valproic acid, carbamazepine, phenytoin, clonazepam and vigabatrin) were administered without a satisfactory response. He became increasingly clumsy and ataxic. His handwriting deteriorated while his speech became slurred. He was diagnosed initially as having multiple sclerosis, and was treated with steroids without any improvement. Upon admission to our hospital for residential care at the age of 12 years, he was profoundly mentally retarded, deaf, blind, had a spastic tetraplegia and was wheelchair bound. At age 13 years, he had an attack of supraventricular tachycardia which responded to adenosine therapy. An electrocardiogram (ECG) did not show evidence of a Wolff–Parkinson–White syndrome. At age 14 years he developed paralytic ileus, which resolved after conservative management.

An electroencephalogram (EEG) at age 7 years showed focal epileptiform discharges at the right parieto-occipital and left anterior regions. An EEG at age 13 years revealed diffuse

Correspondence: Dr CH Ko, Department of Paediatrics, Caritas Medical Centre, 111 Wing Hong Street, Shamshuipo, Hong Kong, China. Fax: (852) 2785 5755; email: kochunhung@hotmail.com

CH Ko, MRCP. CW Lam, FRCPA. PWT Tse, MRCP. CK Kong, MRCP. AKH Chan, FRCP. LJC Wong, FACMG.

Accepted for publication 12 May 2000.

slow waves compatible with an encephalopathic picture. Multiple cerebral infarcts, involving the right parieto-occipital and left temporal occipital regions, were shown on computed tomography (CT) scanning. There was no basal ganglial infarct or calcification. A magnetic resonance imaging (MRI) brain scan taken at age 10 years showed increased signal intensity in T2-weighted images in both occipital lobes and the right parieto-temporal area. A MRI brain scan at age 13 years showed progressive cerebral atrophy (Fig. 1). A cerebral digital subtraction angiogram at age 12 years was normal.

The deproteinated blood lactate concentration was 4.9 mmol/L (reference interval: 0.5–1.3 mmol/L) and the pyruvate concentration was 205 μ mol/L (reference interval: 45–80 μ mol/L), with a lactate to pyruvate (L/P) ratio of 24 (reference interval: 6–14). Cerebrospinal fluid lactate was 6.0 mmol/L (reference interval: 0.8–2.2 mmol/L). Other serum and CSF laboratory tests were normal. All the specimens were taken at the age of 12 years, when he had been free of epileptic seizures for more than 1 month. Muscle biopsy revealed a normal checkerboard pattern with no evidence of fibre type grouping or group atrophy. No ragged red fibres were demonstrated in the modified Gomori trichrome stain. Nicotinamide adenine dinucleotide–tetrazolium reductase (NADH-TR) activity was normal. Electron microscopy did not show any abnormality. In particular, there were no giant mitochondria with paracrystalline inclusion granules characteristic of a mitochondrial myopathy.

All family members of the maternal lineage enjoyed good health. Physical examinations were unremarkable. A brainstem evoked potential study for the brother (III2) was normal but revealed a subclinical hearing loss of 40 dBnHL for the mother (II2). Visual evoked potential studies, EEG, and fasting serum lactate and pyruvate levels were normal for III2 and II2.

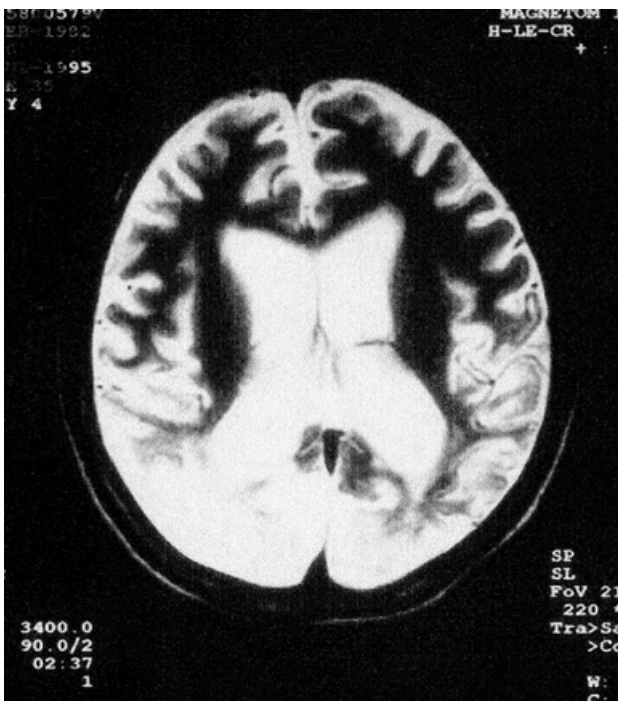


Fig. 1 A magnetic resonance imaging brain scan at age 13 years revealed cerebral atrophy with increased signal intensities on T2 weighted images in both occipital lobes and the right parietal lobe.

METHODS

Seven members in three generations of the family were screened for the A3243G mutation (Fig. 2). The other members of the family (subjects II, II3 and II5) declined screening. Apart from the proband, all other family members were asymptomatic. The muscle biopsy of the proband was taken from the right vastus lateralis. Peripheral blood leucocytes, hair follicles and buccal cells were obtained from all seven family members. Genomic DNA was extracted from the tissues according to the method described previously.¹¹ A fragment of mtDNA encompassing the common mutation site for MELAS was amplified by polymerase chain reaction (PCR). Primers for the reaction were nt3116–3134 (sense) and nt3353–3333 (antisense) of the mtDNA sequence.

Quantitative PCR analysis of the A3243G mutation was performed according to the procedures described by Moraes *et al.*¹² The PCR products were digested with 10 units of *Hae*III at 37°C for 2 h. The DNA mixture was then analysed by polyacrylamide gel electrophoresis. The radioactivity of each fragment was measured by a Betascope 603 blot analyser (Betagen, Waltham, MA, USA).

The previously mentioned pair of primers produced a 238-bp PCR product. Digestion of normal mtDNA with *Hae*III produces fragments of 32, 37 and 169 bp. The putative A3243G point mutation creates an additional *Hae*III recognition site to cleave the 169 bp fragment into 72 and 97 bp fragments.

RESULTS

Results of the mtDNA analysis are represented in Table 1. The heteroplasmic A3243G mutation was found in the peripheral leucocytes, hair follicles and buccal cells of the proband III1 and subjects III2 and II2. Muscle biopsy from the proband also revealed the same mutation. The point mutation was not detected in subjects I2, II4, II6, and II7. There was no apparent correlation between the amount of mutant mtDNA and symptoms: whilst the proband (III1) had the full-blown presentation of MELAS, his 8-year-old brother (III2) remained asymptomatic on follow up for 3 years, even though the levels of mutant mtDNA in his blood, hair follicles and buccal cells were higher than that in the proband. Subject II2 had a low level of mutant mtDNA in her tissues (11–32%) and was asymptomatic.

DISCUSSION

Mitochondrial encephalopathy, lactic acidosis, stroke-like episodes syndrome is a maternally inherited disorder affecting multiple systems. In the proband in this report, the involvement of the CNS, cardiovascular system and gastrointestinal system was characteristic of a mitochondrial disorder.^{13,14} The clinical presentation fulfils the diagnostic criteria of MELAS (Hirano *et al.*): stroke before 40 years of age; encephalopathy characterized by seizures or dementia; and mitochondrial dysfunction characterized by lactic acidosis or ragged red fibres.¹⁵ The metabolic strokes typically involve the parieto-occipital regions and do not conform to cerebral vascular territories.^{16,17} Utilizing the brain perfusion single photon emission computed tomography, others have demonstrated focal hypoperfusion in

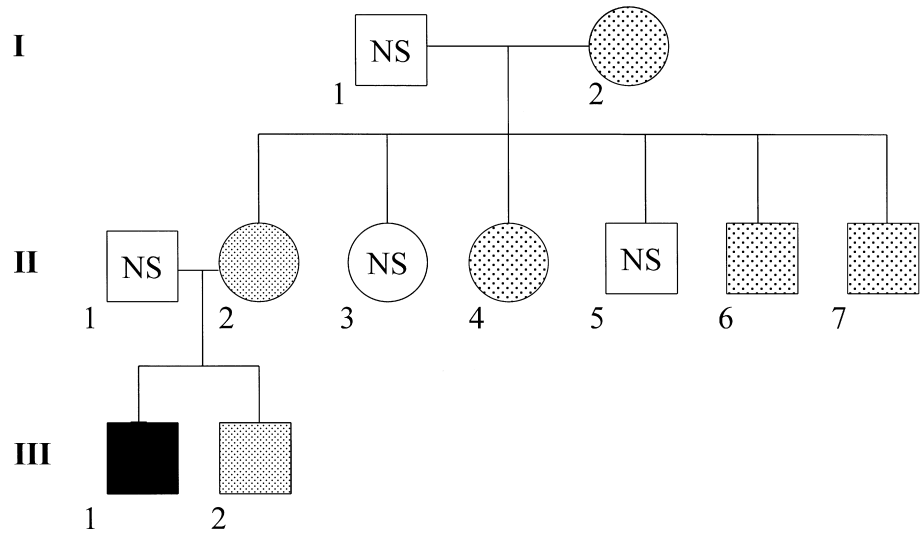


Fig. 2 Pedigree of the Chinese mitochondrial encephalomyopathy, lactic acidosis, and stroke-like episodes family. Black, Proband; Gray, asymptomatic carriers of the A3243 mutation; Dotted, subjects who do not have the A3243G mutation. NS, not screened.

Table 1 A3243G point mutation in the Chinese family with mitochondrial encephalomyopathy, lactic acidosis, and stroke-like episodes

Subject	I2	II2	II4	II6	II7	III1	III2
Sex/age (years)	F/72	F/38	F/36	M/40	M/39	M/14	M/8
A3243G mutation*							
Blood (%)	0	11	0	0	0	56	65
Hair (%)	0	27	0	0	0	70	79
Buccal cell (%)	0	32	0	0	0	64	70
Muscle (%)	NA	NA	NA	NA	NA	54	NA

*Number represents percentages of mutant mitochondrial DNA. NA, not available.

the parieto-occipital regions, correlating with abnormal CT/MRI findings. The cerebral perfusion reserve in MELAS patients is reduced significantly compared with that in patients with other types of mitochondrial disease.¹⁸

Migraine-like headache occurs with a high incidence in MELAS,² and the association of migraine headache, vomiting and stroke-like symptoms in young patients should raise the suspicion of the syndrome.¹⁹ However, in the analysis of the mtDNA of 23 migraine patients with aura, Klopstock *et al.* failed to detect any large-scale deletions or point mutations at base pair 3243 (MELAS) and base pair 8344 (mutation site for myoclonic epilepsy with ragged-red fibres (MERRF)).²⁰ Whether the pathogenesis of migraine is related to mitochondrial dysfunction remains unclear.

In this pedigree, the A3243G mutation was not present in the leucocytes, buccal cells and hair follicles of the proband's maternal grandmother (I2) and his maternal aunt and uncles. Although not all the siblings of the mother (II2) were screened, the results strongly suggest that a *de novo* mutation has occurred in the mothers' mtDNA. Although paternity testing was not performed, we have confirmed that I2 is the biological mother of II2 by checking the name of the mother on the birth certificate of II2 to be subject I2. Whether the mutation has occurred in the oocytes of the maternal grandmother or during the embryonic development of the mother remains unclear.⁹ To

our knowledge, the present study is the first report of a *de novo* mutation occurring in a Chinese family. Yamamoto has reported a *de novo* 3243 mutation in the mother of a Japanese MELAS patient.⁹ She was oligosymptomatic with fatigability, and had nerve deafness and diabetes mellitus. Campos *et al.* reported a *de novo* 3243 mutation leading to a sporadic MERRF/MELAS overlap syndrome.¹⁰ It seems that the *de novo* mutation may lead to various clinical presentations, ranging from subclinical to full-blown illness.

The level of mutated mtDNA is relatively low in the proband's mother, with rapid segregation resulting in a high level of mutated mtDNA in the tissues of her offspring. It seems that a threshold level of mutant mtDNA may have been reached in the affected tissues of the proband leading to the disease phenotype.^{2,21} Nonetheless, his brother remains asymptomatic at the age of 11 years despite having a higher level of mutant mtDNA. This raises several possibilities. The level of mutant mtDNA may be below the threshold in the CNS of III2. However, extrinsic factors may be required to trigger the expression of the phenotype.⁸ We have shown previously that the administration of valproate can precipitate the symptomatology of MELAS.²² Finally, as the age of disease onset is highly variable, subject III2 may develop the syndrome later.

In this study, in addition to the commonly used peripheral leucocytes and hair follicles, buccal cells were used for mutation screening.²³ The level of mutant mtDNA in the buccal cells correlates well with that in other tissues. The buccal cells can be obtained easily by brushing the walls of the buccal cavity. This non-invasive and convenient method is useful for large scale family screening.

The spontaneous occurrence of deleted mtDNA is seen in most patients with Pearson syndrome and Kearns-Sayre syndrome. *De novo* occurrence of mtDNA point mutations have been reported recently for the T8993G mutation in Leigh disease and neuropathy, ataxia, and retinitis pigmentosa syndrome patients, where the threshold (usually clinical manifestation occurs when the mutant mtDNA is > 90% in affected tissues) is much higher than that for A3243G mutation.²⁴⁻²⁶ The *de novo* mutation of mtDNA may occur at substantial levels, thus causing disease within one or two generations. The

two carriers of the A3243G mutation were followed for 3 years (1996–99). Coenzyme Q₁₀ treatment was empirically started for the brother (III2) of the proband. Both of them remained asymptomatic during this period. Damian *et al.* reported that among eight oligosymptomatic adult carriers of the mutation, three developed diabetes mellitus, renal failure or cardiomyopathy on long term follow up. Positron emission tomography showed widespread cortical and basal ganglion metabolic deficits in six patients.²⁷ Lam *et al.* reported a 16-year-old asymptomatic carrier of the 3243 mutation who developed repeated tonic clonic convulsion 3 months after the molecular genetics study.⁷ Thus long-term follow up of carriers is mandatory, which should include a thorough neurological and audiometric examination, serum biochemistry, renal function tests, urinalysis, ECG and EEG.²⁷ Carriers should avoid exposure to agents that may compromise mitochondrial function (e.g. phenytoin, phenobarbitone, valproic acid, tetracycline and chloramphenicol).²⁸ It may be useful to repeat the quantitative PCR analysis on carriers to monitor any change in the degree of heteroplasmy, as well as the correlation with clinical symptoms.

REFERENCES

- Pavakis SG, Phillips PC, DiMauro S, DeViro DC, Rowland LP. Mitochondrial myopathy, encephalopathy, lactic acidosis and stroke-like episodes: A distinctive clinical syndrome. *Ann. Neurol.* 1984; **16**: 481–8.
- Ciafaloni E, Ricci E, Shanske S *et al.* MELAS: Clinical features, biochemistry, and molecular genetics. *Ann. Neurol.* 1992; **31**: 391–8.
- Goto Y, Nonaka I, Horai S. A mutation in the tRNA^{Leu}(UUR) gene associated with the MELAS subgroup of mitochondrial encephalomyopathies. *Nature* 1990; **384**: 651–3.
- Shoffner JM, Wallace DC. Oxidative phosphorylation diseases and mitochondrial DNA mutations: Diagnosis and treatment. *Annu. Rev. Nutr.* 1994; **14**: 535–68.
- Flierl A, Reichmann H, Seibel P. Pathophysiology of the MELAS 3243 transition mutation. *J. Biol. Chem.* 1997; **272**: 27189–96.
- Liou CW, Huang CC, Chee ECY *et al.* MELAS syndrome: Correlation between clinical features and molecular genetic analysis. *Acta Neurol. Scand.* 1994; **90**: 354–9.
- Lam CW, Jain K, Chan KY, Silva DK, Chan YW, Wong LJC. Diagnosis of mitochondrial encephalomyopathy, lactic acidosis, and stroke-like episodes (MELAS) in a Chinese family by PCR-restriction enzyme analysis. *J. Clin. Pathol. Mol. Pathol.* 1995; **48**: M273–7.
- Martinuzzi A, Bartolomei L, Carozzo R *et al.* Correlation between clinical and molecular features in two MELAS families. *J. Neurol. Sci.* 1992; **113**: 222–9.
- Yamamoto M. Did de novo MELAS common mitochondrial DNA point mutation (mtDNA3243, A→G transition) occur in the mother of a proband of a Japanese MELAS pedigree? *J. Neurol. Sci.* 1996; **135**: 81–4.
- Campos Y, Martin MA, Lorenzo G, Aparicio M, Cabello A, Arenas J. Sporadic MERRF/MELAS overlap syndrome associated with the 3243 tRNA^{Leu}(UUR) mutation of mitochondrial DNA. *Muscle Nerve* 1996; **19**: 187–90.
- Lahiri DK, Nurnberger JL. A rapid non-enzymatic method for the preparation of HMW DNA from blood for RFLP studies. *Nucl. Acids Res.* 1991; **19**: 5444.
- Moraes CT, Ricci E, Bonilla E, DiMauro S, Schon EA. The mitochondrial tRNA^{Leu}(UUR) mutation in mitochondrial encephalomyopathy, lactic acidosis, and stroke-like episodes (MELAS): Genetic, biochemical, and morphological correlations in skeletal muscle. *Am. J. Hum. Genet.* 1992; **50**: 934–49.
- Jackson MJ, Schaefer JA, Johnson MA, Morris AAM, Turnbull DM, Bindoff LA. Presentation and clinical investigation of mitochondrial respiratory chain disease: A study of 51 patients. *Brain* 1995; **118**: 339–57.
- Johns DR. Mitochondrial DNA and disease. *N. Engl. J. Med.* 1995; **7**: 638–44.
- Hirano M, Ricci E, Koenigsberger MR *et al.* MELAS. An original case and clinical criteria for diagnosis. *Neuromuscul. Disord.* 1992; **2**: 125–35.
- Koo B, Becker LE, Chuang S *et al.* Mitochondrial encephalopathy, lactic acidosis, stroke-like episodes (MELAS): Clinical, radiological, pathological, and genetic observations. *Ann. Neurol.* 1993; **34**: 25–32.
- Kim IO, Kim JH, Kim WS, Hwang YS, Yeon KM, Han MC. Mitochondrial myopathy-encephalopathy-lactic acidosis and stroke-like episodes (MELAS) syndrome: CT and MR findings in seven children. *Am. J. Roentgenol.* 1996; **166**: 641–5.
- Watanabe Y, Hashikawa Moriwaki H *et al.* SPECT findings in mitochondrial encephalomyopathy. *J. Nucl. Med.* 1998; **39**: 961–4.
- Ohno K, Isotani E, Hirakawa K. MELAS presenting as migraine complicated by stroke: Case report. *Neuroradiology* 1997; **39**: 781–4.
- Klopstock T, May A, Seibel P, Papagiannuli E, Diener HC, Reichmann H. Mitochondrial DNA in migraine with aura. *Neurology* 1996; **46**: 1735–8.
- Morgan-Hughes JA, Sweeney MG, Cooper JM *et al.* Mitochondrial DNA (mtDNA) diseases: Correlation of genotype to phenotype. *Biochim. Biophys. Acta* 1995; **1271**: 135–40.
- Lam CW, Lau CH, Williams JC, Chan YW, Wong LJ. Mitochondrial myopathy, encephalopathy, lactic acidosis and stroke-like episodes (MELAS) triggered by valproate therapy. *Eur. J. Pediatr.* 1997; **156**: 562–4.
- Wong LJ, Lam CW. Alternative, noninvasive tissues for quantitative screening of mutant mitochondrial DNA. *Clin. Chem.* 1997; **43**: 1241–3.
- Tulinius MH, Houshmand M, Larsson NG *et al.* De novo mutation in the mitochondrial ATP synthase subunit 6 gene (T8993G) with rapid segregation resulting in Leigh syndrome in the offspring. *Hum. Genet.* 1995; **96**: 290–4.
- Takahashi S, Makita Y, Oki J *et al.* De novo mtDNA nt 8993 (T→G) mutation resulting in Leigh syndrome. *Am. J. Hum. Genet.* 1998; **62**: 717–9.
- de Coo IF, Smeets HJ, Gabreels FJ, Arts N, van Oost BA. Isolated case of mental retardation and ataxia due to a de novo mitochondrial T8993G mutation. *Am. J. Hum. Genet.* 1996; **58**: 636–8.
- Damian MS, Hertel A, Seibel P *et al.* Follow-up in carriers of the 'MELAS' mutation without strokes. *Eur. Neurol.* 1998; **39**: 9–15.
- Peterson PL. The treatment of mitochondrial myopathies and encephalopathies. *Biochim. Biophys. Acta* 1995; **1271**: 275–80.