

Atypical MELAS syndrome associated with a new mitochondrial tRNA glutamine point mutation

Article abstract—The authors studied a 47-year-old patient who presented with an association of deafness, acute cerebral stroke-like episode, leukoencephalopathy, and extensive basal ganglia calcifications. Late onset and neuroradiologic findings were atypical for MELAS syndrome (Mitochondrial Myopathy, Encephalopathy, Lactic Acidosis, and Stroke-like episodes). A heteroplasmic G to A transition at nucleotide 4332 in the tRNA glutamine gene was identified in the patient's muscle mitochondrial DNA. The pathogenicity of the mutation was shown in single muscle fibers by the correlation between high mutation load and cytochrome *c* oxidase defect.

NEUROLOGY 2001;56:405–407

M. Bataillard, MD; E. Chatzoglou, PhD; L. Rumbach, MD; D. Sternberg, MD; A. Tournade, MD; P. Laforêt, MD; C. Jardel, PhD; T. Maisonobe, MD; and A. Lombès, MD, PhD

MELAS syndrome (Mitochondrial Myopathy, Encephalopathy, Lactic Acidosis, and Stroke-like episodes) typically presents during childhood.^{1,2} Most MELAS syndromes are linked to the presence of the mitochondrial DNA (mtDNA) leucine transfer RNA (tRNA) point mutation A3243G,³ but other mtDNA point mutations occur.⁴ We report a patient who presented with a MELAS syndrome with unusual clinical and neuroradiologic features. Molecular investigations disclosed an original mtDNA point mutation in the glutamine tRNA gene.

Patient and methods. *Case report.* The patient had sensorineural deafness since the age of 20 years. His family history was negative. He presented with acute aphasia and right hemiparesis (grade 2/5 in arm and leg, Medical Research Council scale) at the age of 47 years. Blood pressure, cardiac rhythm, and results of echocardiography, Doppler analysis of neck vessels, and cerebral angiography were normal. Routine blood tests were normal but for a slightly elevated triglyceride concentration of 2.2 g/L (normal, 0.35 to 1.5 g/L). Acute symptoms partially regressed. The patient is now 51 years old. He has recently experienced episodes of twitching in the right arm that were successfully treated with carbamazepine. His clinical status has remained otherwise stable.

Methods. Lactate measurements were performed in blood and in CSF. Deltoid muscle was taken by open biopsy and processed for routine morphologic techniques, including the reactions for succinate dehydrogenase (SDH) and cytochrome *c* oxidase (COX). Immunohistochemical methods were as previously described.⁵ Primary antibodies were a rabbit polyclonal against the mtDNA encoded

COX2 protein and a mouse monoclonal against the nuclear DNA-encoded COX4 protein.

Extraction of total DNA and Southern blot analysis were performed according to routine procedures. mtDNA tRNA genes were scanned for mutations and heteroplasm by a PCR-denaturing gradient gel electrophoresis (DGGE)-based strategy as described.⁶

Correlative studies of mutation load and COX activity were performed on single muscle fibers as described.⁷ Briefly, muscle sections, 16- μ m thick, were stained for both SDH and COX activities. Single muscle fibers were then isolated with a tungsten electrode, and their total DNA was extracted with an alkaline lysis procedure. Fragments encompassing the glutamine tRNA gene were amplified as described⁶ and rendered radioactive by a last PCR cycle with ³³P dCTP. The PCR products were restricted with the enzyme *Mae*I, whose unique site is abolished by the mutation, run on 10% acrylamide-bisacrylamide gels (19:1), and counted by using a β -imager. The proportion of the mutation in COX-positive fibers was compared to the proportion in COX-negative fibers with the nonparametric statistical test of Mann and Whitney.

Results. A mitochondrial origin of the patient's stroke was suspected based on its brain imaging. CT scan showed the presence of extensive and symmetric calcifications in basal ganglia (figure 1A) and nuclei dentati (not shown). MRI showed confluent high-density signals in the supratentorial white matter on T2-weighted images (see figure 1B). There was also an important dilatation of the infratentorial and frontotemporal cisterns, which was in relation to a severe cortical atrophy, especially of the cerebellum giving pseudocystic aspect (see figure 1C). CSF analysis showed the presence of 1 white blood cell (WBC)/mm³ and 80 mg/dL protein. Lactate level was abnormally high in CSF (2.95 mmol/L; normal values below 2.2), but normal in plasma.

Gomori-trichrome stain showed the presence of muscle mitochondrial proliferation with several ragged red fibers (not shown). Muscle COX activity was diffusely decreased, and several fibers were severely deficient (figure 2A), whereas their SDH activity was increased (see figure 2B). These strongly SDH-stained fibers represented 3% of the muscle fibers. Strongly SDH-positive blood vessels were also noted. The mosaic pattern of the COX activity (coexistence of normal and defective muscle fibers in a checker-

From the Hôpital A Bouloche (Drs. Bataillard, Rumbach, and Tournade), Montbéliard cedex; Unité INSERM U523, Institut de Myologie (Drs. Chatzoglou, Laforêt, and Lombès), Service de Biochimie B (Drs. Sternberg and Jardel), and the Service de Neuropathologie (Dr. Maisonobe), Hôpital de La Salpêtrière, Paris, France.

Supported by grants from La Fondation pour la Recherche Médicale and from the AFM (Association Française contre les Myopathies).

E.C. received a postdoctoral fellowship from the AFM (Association Française contre les Myopathies).

Received May 25, 2000. Accepted in final form October 12, 2000.

Address correspondence and reprint requests to Dr. A. Lombès, INSERM UR 523, Institut de Myologie, Hôpital de La Salpêtrière, 75651 Paris cedex 13, France; e-mail: a.lombes@myologie.chups.jussieu.fr

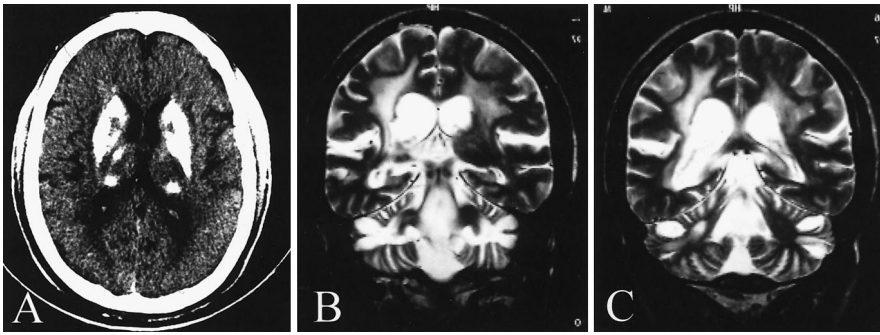


Figure 1. Neuroradiologic findings. (A) CT scan showing large calcifications in basal ganglia. (B and C) Coronal sections of brain MRI T2-weighted sequences showing extensive high-density signals in the supratentorial white matter and cerebellar atrophy associated with important dilatation of the fourth ventricle with pseudocysts.

board pattern) suggested an mtDNA origin of the disease. This was further vindicated by the analysis of serial sections, which showed that the scattered COX-defective fibers had a decreased immunoreactivity for the mtDNA-encoded subunit COX2 (see figure 2C), whereas that of the nuclear DNA encoded subunit COX4 was increased (see figure 2D).

Spectrophotometric analyses of the respiratory chain did not show any significant defect in the patient muscle homogenate (not shown).

mtDNA size and quantity appeared normal on Southern blot analysis (not shown). A heteroplasmic mutation in the glutamine tRNA gene was found by DGGE (figure 3A), whereas the sequence of all other tRNA genes was identical to the consensus human sequence (Genbank access code: hummtcg). Sequencing identified the mutation as a G to A transition at nucleotide 4332. The mutation was present in 81% of the muscle mtDNA molecules, as shown by restriction of amplified mtDNA fragments with *MaeI*. It was absent in mtDNA from the patient's blood or his skin fibroblasts. It was also absent in the blood mtDNA from his mother and from his brother.

Pathogenic relevance of the mutation was suspected because of the total conservation of the involved nucleotide in all mammalian species and on the absence of the mutation in 300 controls. It was shown by the significant correlation between the proportion of the mutation and the defect of

COX in single fibers from the patient muscle sections (see figure 3, B and C).

Discussion. Stroke at an early age without cardiovascular cause was sufficient to look for a mitochondrial disorder. Deafness and basal ganglia calcifications were in favor of that diagnosis. The mitochondrial dysfunction was shown by the high lactate concentration in CSF and by the presence of mitochondrial proliferation and COX defect in muscle. The patient had all of the criteria for the diagnosis of MELAS: Mitochondrial myopathy, Encephalopathy, Lactic acidosis (at least in CSF), and Stroke-like episode.¹ His clinical presentation was atypical, however, because the patient was healthy up to the age of 47 years, with the exception of his sensorineural deafness.¹⁻³ Progressive deafness per se has been reported as a frequent symptom associated with mtDNA alterations.⁸

The patient brain MRI differed from classic MELAS cases by the absence of increased signals involving both gray and white matter in T2-weighted sequences.⁹ This may be related to the relative mildness of the acute episode. Conversely, diffuse supratentorial leukoencephalopathy is most unusual in MELAS syndrome but has recently been linked to

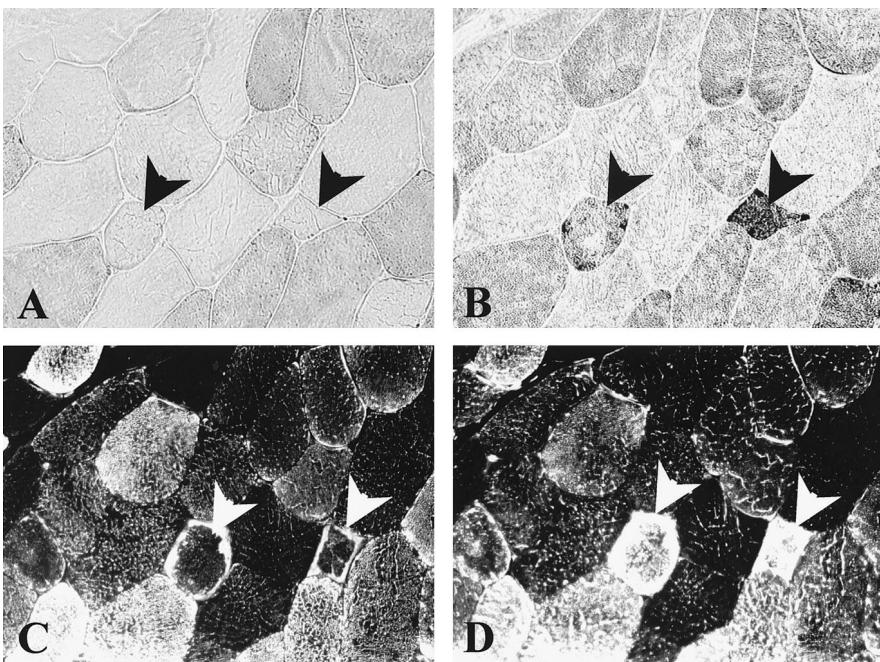


Figure 2. Morphologic analysis of serial sections from the patient's deltoid muscle. (A) Cytochrome c oxidase (COX) activity; (B) succinate dehydrogenase (SDH) activity; (C) immunohistochemical reactivity of the mitochondrial DNA (mtDNA)-encoded subunit COX2; (D) immunohistochemical reactivity of the nuclear DNA encoded subunit COX4. Muscle fibers designated with an arrowhead showed both COX defect (A) and mitochondrial proliferation shown by the increase of SDH activity (B). The mtDNA-encoded subunit COX2 was decreased in these fibers (C), whereas the nuclear DNA-encoded subunit of COX4 was increased (D).

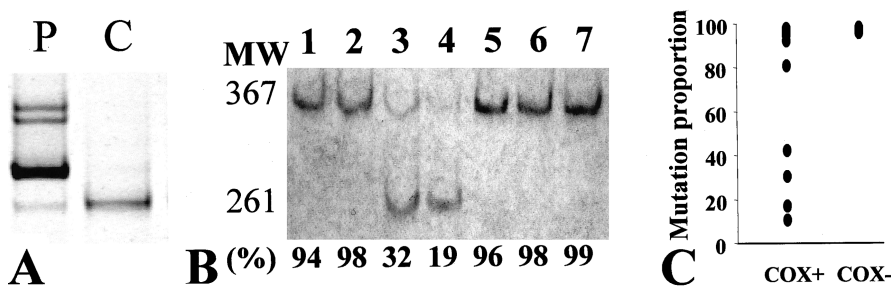


Figure 3. Screening and analysis of the G4332A mutation. (A) Electrophoretic pattern in denaturing gradient gel of mitochondrial DNA (mtDNA) fragments encompassing glutamine, isoleucine, and methionine tRNA genes. P = patient mtDNA; C = control mtDNA. (B) Electrophoretic pattern of the mtDNA fragments amplified from total DNA extracted from single muscle fibers, digested with the MaeI restriction enzyme,

and run on a nondenaturing polyacrylamide gel. Numbers on top designate each single muscle fiber. Numbers at the bottom designate the mutation proportion calculated from the restriction pattern (in percents). MW = molecular weight of fragments in base pairs; 367 = size of the uncut fragments; 261 = size of the larger restriction fragment generated by MaeI digestion. (C) Comparison of the G4332A mutation proportion in single muscle fibers classified in two groups: COX+ = fibers with a normal cytochrome c oxidase (COX) activity; and COX- = fibers with a defective COX activity. The p value was 0.002 as calculated by the Mann-Whitney U test.

respiratory chain deficiency in children affected with mitochondrial disorders.¹⁰ Finally, if cerebellar atrophy is a common finding, its pseudocystic aspect has never been, to our knowledge, reported.

The G to A transition at nucleotide 4332 in tRNA glutamine gene was considered as potentially pathogenic for indirect reasons such as its heteroplasmy, its skewed tissue distribution, its absence in 300 controls, and the high phylogenetic conservation of the involved nucleotide within the glutamine tRNA gene. The deleterious potential of the mutation was directly shown by the highly significant correlation between COX defect and mutation load in single muscle fibers. This new mutation further exemplifies the genetic diversity of the MELAS syndrome. It induces an energetic mitochondrial deprivation that is similar to that of the other reported mutations, thus further strengthening the mitochondrial origin of the MELAS syndrome. Whether the specific mutation underlies the atypical characteristics of the patient presentation remains to be shown.

References

- Hirano M, Ricci E, Koenigsberger MR, et al. MELAS: an original case and clinical criteria for diagnosis. *Neuromusc Disord* 1992;2:125-135.
- Hammans SR, Sweeney MG, Hanna MG, Brockington M, Morgan-Hughes JA. The mitochondrial DNA transfer RNA^{Leu} (UUR) A→G(3243) mutation: a clinical and genetic study. *Brain* 1995;118(3):721-734.
- Goto Y, Nonaka I, Horai S. A mutation in the tRNA^{Leu} (UUR) gene associated with the MELAS subgroup of mitochondrial encephalomyopathies. *Nature* 1990;348:651-653.
- Simon DK, Johns DR. Mitochondrial disorders: clinical and genetic features. *Annu Rev Med* 1999;50:111-127.
- Possekkel S, Lombès A, Ogier de Baulny H, et al. Immunohistochemical analysis of muscle cytochrome c oxidase deficiency in children. *Histochemistry* 1995;103:59-68.
- Sternberg D, Danan C, Lombès A, et al. Exhaustive scanning approach to screen all the mitochondrial tRNA genes for mutations and its application to the investigation of 35 independent patients with mitochondrial disorders. *Hum Mol Genet* 1998;7:33-42.
- Moraes CT, Ricci E, Petruzzella V, et al. Molecular analysis of the muscle pathology associated with mitochondrial DNA deletions. *Nature Genet* 1992;1:359-367.
- Chinnery PF, Elliott C, Green GR, et al. The spectrum of hearing loss due to mitochondrial DNA defects. *Brain* 2000;123:82-92.
- Majamaa K, Turkka J, Kärppä M, Winqvist S, Hassinen IE. The common MELAS mutation A3243G in mitochondrial DNA among young patients with an occipital brain infarct. *Neurology* 1997;49:1331-1334.
- de Lonlay-Debeney P, von Kleitz-Retzow JC, Hertz-Pannier L, et al. Cerebral white matter disease in children may be caused by mitochondrial respiratory chain deficiency. *J Pediatr* 2000;136:209-214.

Neurology[®]

Atypical MELAS syndrome associated with a new mitochondrial tRNA glutamine point mutation

M. Bataillard, E. Chatzoglou, L. Rumbach, et al.
Neurology 2001;56;405-407
DOI 10.1212/WNL.56.3.405

This information is current as of February 13, 2001

Updated Information & Services	including high resolution figures, can be found at: http://www.neurology.org/content/56/3/405.full.html
References	This article cites 10 articles, 4 of which you can access for free at: http://www.neurology.org/content/56/3/405.full.html#ref-list-1
Citations	This article has been cited by 4 HighWire-hosted articles: http://www.neurology.org/content/56/3/405.full.html#otherarticles
Permissions & Licensing	Information about reproducing this article in parts (figures, tables) or in its entirety can be found online at: http://www.neurology.org/misc/about.xhtml#permissions
Reprints	Information about ordering reprints can be found online: http://www.neurology.org/misc/addir.xhtml#reprintsus

Neurology® is the official journal of the American Academy of Neurology. Published continuously since 1951, it is now a weekly with 48 issues per year. Copyright . All rights reserved. Print ISSN: 0028-3878. Online ISSN: 1526-632X.

