

Supracerebellar transtentorial approach to posterior temporomedial structures

Technical note

YASUHIRO YONEKAWA, M.D., HANS-GEORG IMHOF, M.D., ETHAN TAUB, M.D.,
MARIJAN CURCIC, M.D., YASUHIKO KAKU, M.D., PETER ROTH,
HEINZ GREGOR WIESER, M.D., AND PETER GROSCURTH, M.D.

Department of Neurosurgery, Anesthesiology, Neurology, and Anatomy, Zurich University Hospital, Switzerland

✓ The supracerebellar transtentorial (SCTT) approach, a modification of the infratentorial supracerebellar approach, facilitates simple and minimally invasive access to posterior temporomedial structures without requiring retraction of the temporal or occipital lobe.

The SCTT approach was used in 16 patients over a 3-year period. Eleven patients harbored tumors confined to, or located mainly within, the posterior hippocampal formation, three patients harbored aneurysms (one ruptured posterior cerebral artery [PCA] aneurysm at the P₂-P₃ junction, one ruptured giant PCA [P₂] aneurysm, and one giant basilar artery–superior cerebellar artery aneurysm), one patient had juvenile-type moyamoya disease, and one patient suffered from medically intractable epilepsy. In these patients, the SCTT approach enabled tumor removal, aneurysm clipping, and vascular bypass procedures.

The authors' experience suggests that this approach can be used routinely in treating lesions in the posterior temporomedial region.

KEY WORDS • surgical approach • parahippocampal gyrus • posterior cerebral artery • aneurysm • revascularization

Clinical Material and Methods

Case Selection

The SCTT approach was used in 16 patients who underwent surgery at the Department of Neurosurgery of Zurich University Hospital between September 1997 and May 2000. The clinical data are listed in Table 1. There were seven female and nine male patients in this group, and their mean age was 47 years (range 3–66 years).

Indications for surgery included six tumors confined to the posterior hippocampus (two low-grade astrocytomas [WHO Grade⁷ II], two anaplastic astrocytomas [WHO Grade III], one neuroglial angiodysplasia, and one metastasis of a melanoma), five tumors occupying the whole temporomedial region (two astrocytomas [WHO Grade II] and three glioblastomas multiforme), three aneurysms (one ruptured aneurysm at the P₂-P₃ junction of the PCA treated by neck clipping, one giant aneurysm of the proximal P₂ segment treated by ligation, and one BA–SCA giant aneurysm treated by OA–PCA bypass), one case of Moyamoya disease treated by indirect revascularization of the PCA territory, and one case of medically intractable epilepsy.

ACCESS to posterior temporomedial structures around the tentorial notch may be gained by occipital interhemispheric, subtemporal, or temporal transventricular approaches. Each approach carries its own inherent risk of compromising visual fields and/or language function (when performed in the dominant hemisphere) because of the need for retraction or cortical incision. The SCTT approach was devised to avoid these risks and was originally reported, as far as we can determine from our review of the literature, by Voigt and Yasargil²⁰ in 1976 for removal of a cavernous angioma in the left parahippocampal gyrus.

In this communication we describe our experience in using the SCTT approach to structures such as the posterior hippocampal formation and the PCA (P₂ and P₃ segments), which does not place these highly important functional areas at risk.

Abbreviations used in this paper: BA = basilar artery; OA = occipital artery; PCA = posterior cerebral artery; PTA = posterior temporal artery; P₂ = P₂ segment of PCA; P₃ = P₃ segment of PCA; SCA = superior cerebellar artery; SCTT = supracerebellar transtentorial; WHO = World Health Organization.

TABLE 1

*Clinical characteristics of 16 patients who underwent neurosurgical procedures via the SCTT approach**

Case No.	Age (yrs), Sex	Diagnosis	Symptoms	GOS Score at 3 Mos Postop	Comment
1	57, F	multiple aneurysms	SAH, rt temporal ICH, WFNS Grade IV	good recovery	ruptured rt PCA aneurysm
2	65, M	rt BA-SCA giant aneurysm	rt-sided ocular ptosis	good recovery	rt OA-PCA bypass
3	37, F	lt temporal tumor	seizures	good recovery	astrocytoma in posterior hippocampus
4	18, F	lt temporal tumor	seizures	good recovery	neuroglial angiodysplasia in lt lingual gyrus
5	47, F	tumor in the quadrigeminal cistern	vertigo, headache	good recovery	oligoastrocytoma originating in lt parahippocampal gyrus
6	20, F	rt temporal tumor	seizures	good recovery	astrocytoma
7	66, F	ruptured giant lt PCA aneurysm	SAH, lt temporal ICH, WFNS Grade IV	moderately disabled	lt P ₂ ligation
8	56, M	rt temporal tumor	POS	good recovery	glioblastoma multiforme
9	50, M	lt temporal tumor	POS, seizures	moderately disabled	astrocytoma
10	58, M	rt temporal tumor	POS, seizures	good recovery	glioblastoma multiforme
11	47, F	multiloculated tumor	POS, seizures	moderately disabled	AA in lt parahippocampal gyrus
12	3, M	moyamoya disease	TIA	good recovery	indirect revascularization of rt PCA territory
13	48, M	pharmacotherapy-resistant epilepsy	recurrence of seizures	good recovery	rt selective amygdalohippocampectomy performed in 1989
14	63, M	lt temporal tumor	POS, seizures	moderately disabled	glioblastoma multiforme
15	58, M	rt temporal tumor	POS, seizures	good recovery	melanoma metastasis in lt parahippocampal gyrus
16	57, M	rt temporal tumor	POS, seizures	good recovery	AA in lt parahippocampal gyrus

* AA = anaplastic astrocytoma; GOS = Glasgow Outcome Scale; ICH = intracerebral hematoma; POS = psychoorganic syndrome; SAH = subarachnoid hemorrhage; TIA = transient ischemic attack; WFNS = World Federation of Neurosurgical Societies.

Operative Technique

The SCTT approach is performed in the following manner (Fig. 1). The patient is placed in the sitting position. Fixation of the head is the same as that used during the standard posterior fossa craniotomy, including the infratentorial supracerebellar approach. A paramedian incision and craniotomy are made, as described elsewhere.^{5,11,24,26} The transverse sinus is visible obliquely in the upper one third of the craniotomy. It is not necessary to expose either the confluens sinuum or the junction of the transverse and sigmoid sinuses. The craniotomy need not extend all the way downward to the foramen magnum.

The dura is opened in a V configuration and the bottom of the V is reflected upward so that the transverse sinus is seen in the cranial corner of the reflected area. The lateral portion of the cerebellomedullary cistern is opened to allow drainage of cerebrospinal fluid, which slackens the cerebellum. Adhesions of arachnoid villi between the cerebellum and the transverse sinus are removed so that a space is obtained between the cerebellum and the tentorium. Proceeding forward along the undersurface of the tentorium over the cerebellar surface (quadrangular lobule), one can recognize the trochlear nerve and the SCA anterior to the anterior margin of the quadrangular lobule. In approximately one third of cases, the procedure is possible only by sacrificing a bridging vein between the cerebellum and the tentorium. Medial to the tentorial hiatus, one may see the medial portion of the posterior hippocampus and the parietooccipital artery bulging toward the lateral portion of the midbrain and the quadrigeminal plate.

The tentorium is now cut from below, beginning around the midportion and extending as posteriorly as possible in the direction of the posterior margin of the tentorial hiatus. If large venous lakes or sinuses in the tentorium are encountered, they should be closed using titanium clips to prevent an air embolism. The free, cut edge of the tentori-

um is now retracted, together with the superior surface of the cerebellum, so that the tentorial flap protects the cerebellum as it is retracted downward. One can now inspect the posterior inferior surface of the temporal lobe (parahippocampal gyrus and lingual gyrus) along with two branches of the PCA, the parietooccipital artery and the PTA. If one lifts or partially resects the parahippocampal gyrus, one can discern the P₂-P₃ junction of the PCA.

Once the operation (for example, aneurysm clipping, tumor removal, or posterior hippocampectomy) has been accomplished, the free edge of the tentorium is restored to its position and secured with sutures or fibrin glue (Tissucol). The craniotomy is then closed in a routine fashion.

Illustrative Cases

Case 1

This 57-year-old woman sustained a subarachnoid hemorrhage with a hematoma in the right temporal lobe in December 1998 (Fig. 2 upper).

Examination. Angiography revealed multiple aneurysms, including a ruptured aneurysm of the right PCA at the P₂-P₃ junction (Fig. 2 center). The patient was admitted to the hospital on the day of rupture (Day 0) and assigned World Federation of Neurosurgical Societies² Grade IV and Fisher Grade 4; she underwent surgery on the same day.

Operation. With the patient in the sitting position, a right paramedian occipitotemporal osteoplastic craniotomy was performed. After temporary clipping of the P₂ segment, which lasted 10 minutes, the ruptured aneurysm at the P₂-P₃ junction was radically clipped via the SCTT approach. The intracerebral hematoma was partly removed through a cortical incision in the lateral occipitotemporal gyrus.

Supracerebellar transtentorial approach to posterior temporomedial structures

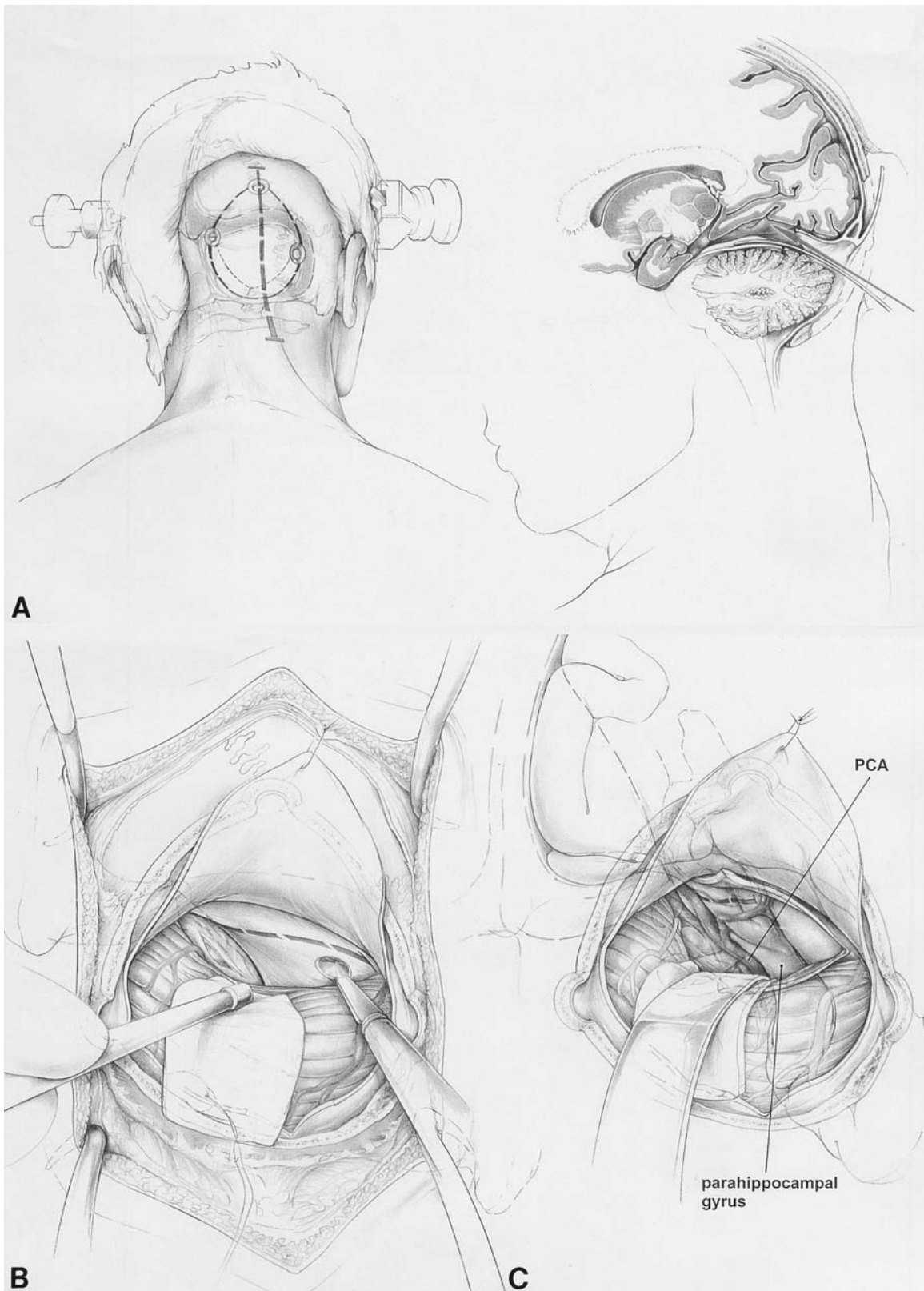


FIG. 1. Drawings depicting the operative steps used in the SCTT approach. A: Craniotomy. B: Incision of the tentorium. C: Exposure of the parahippocampal gyrus and the PCA after downward retraction of the tentorium and cerebellum.

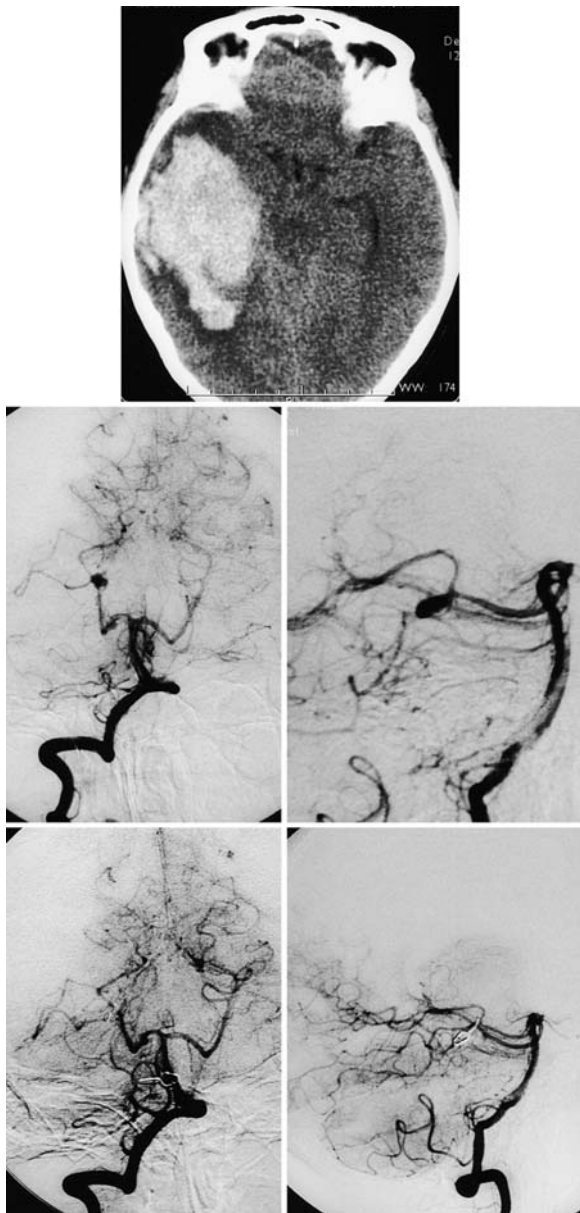


FIG. 2. Case 1. Imaging studies obtained in a 57-year-old woman who underwent surgery via the SCTT approach for a P₂-P₃ junction aneurysm. *Upper*: Computerized tomography scan revealing an intracerebral hematoma in the right temporal lobe. *Center*: Anteroposterior (*left*) and lateral (*right*) angiograms revealing the ruptured aneurysm at the P₂-P₃ junction. *Lower*: Follow-up anteroposterior (*left*) and lateral (*right*) angiograms demonstrating complete clipping of the aneurysm.

Postoperative Course. The patient recovered well from the procedure. Postoperative vasospasm was treated successfully with hemodynamic therapy and selective endovascular application of papaverine. The unruptured aneurysms were treated during two subsequent craniotomies after the patient recovered from the first procedure. The final follow-up angiograms obtained in March 1999 confirmed complete clipping of all aneurysms (Fig. 2 *lower*). The patient's outcome was good, as determined using the Glasgow Outcome Scale,⁴ 4 months later.

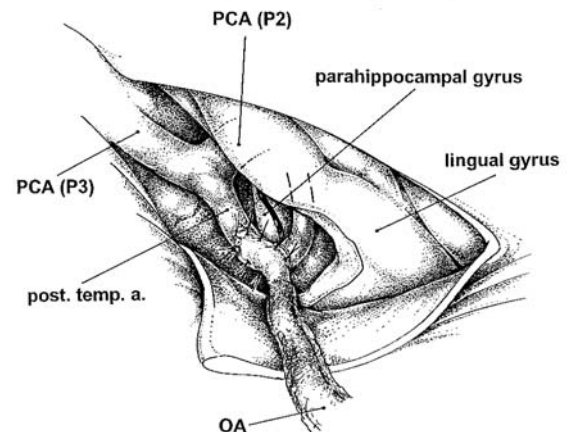
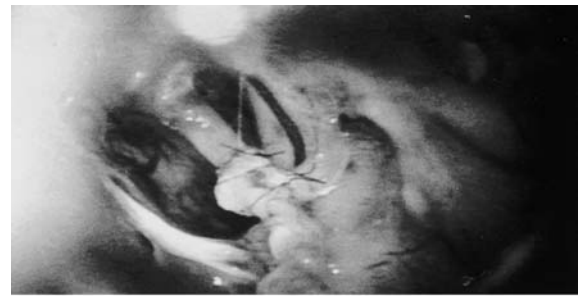

FIG. 3. Case 2. Intraoperative photograph (*upper*) and drawing (*lower*) showing an OA-PCA bypass that was created in a 65-year-old man with a BA-SCA aneurysm. Surgery was performed using the SCTT approach. Post. temp. a. = posterior temporal artery.

Comment. Other approaches that have been used for clipping aneurysms in this location include the conventional subtemporal,¹⁴ occipital interhemispheric,^{8,23} and transsylvian-transventricular approaches.²⁷ This case shows that aneurysm clipping in the P₂-P₃ junction of the PCA is technically feasible via the SCTT approach, without retraction of the temporal lobe or occipital lobe. Despite an intraoperative premature rupture, the aneurysm was successfully clipped after temporary clipping of the P₂, which lasted no longer than 10 minutes.

Case 2

This 65-year-old man was admitted to the hospital in March 1999 because he was experiencing progressive right-sided ocular ptosis of 1 month's duration.

Examination. Magnetic resonance imaging revealed a giant aneurysm of the upper BA, which was subsequently localized using angiography to the right BA-SCA junction.

Operation. In preparation for an intended long temporary or permanent occlusion of the proximal BA, an OA-PCA bypass procedure was performed via the SCTT approach. A linear incision was made over the OA, which was dissected free. A right paramedian occipitotemporal craniotomy was then performed, the tentorium was incised, and the PTA (diameter 1 mm) was dissected on the inferior surface of the parahippocampal gyrus. A microsurgical end-to-side bypass was performed between the OA and the PTA (Fig. 3).

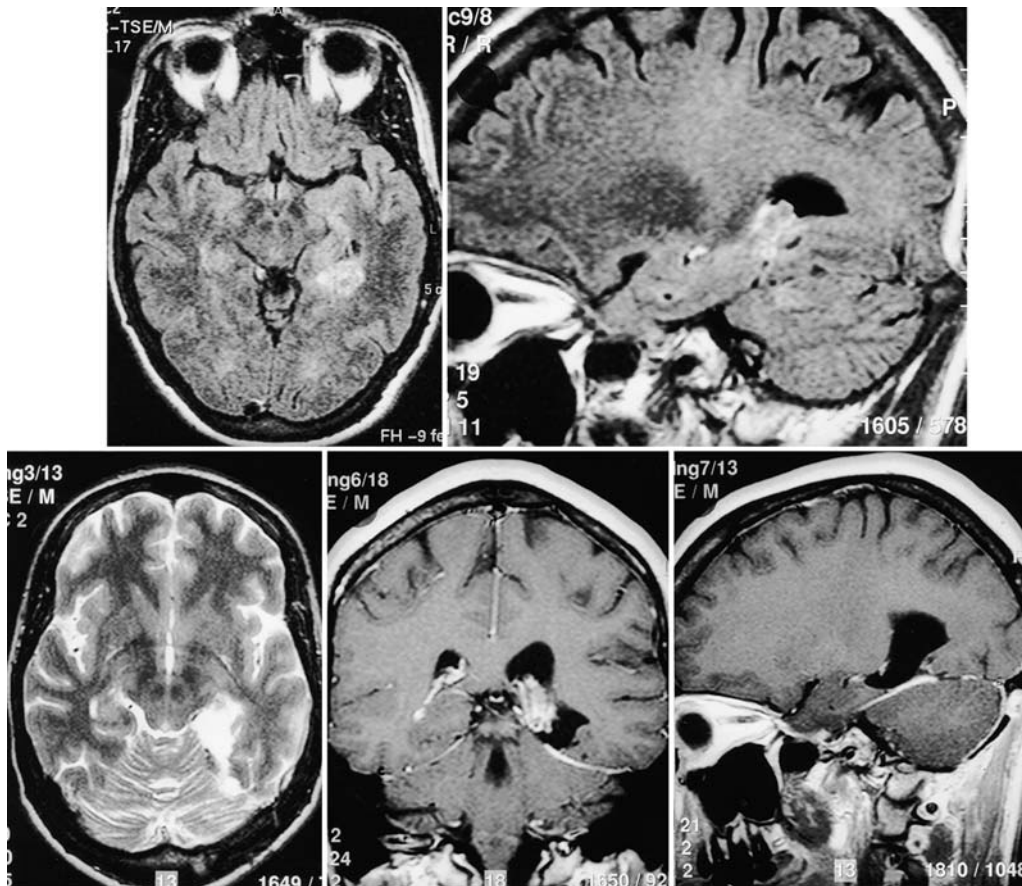


FIG. 4. Case 3. Imaging studies obtained in a 37-year-old woman in whom a low-grade astrocytoma was located in the posterior hippocampus. Axial (upper left) and sagittal (upper right) MR images revealing a space-occupying lesion. Follow-up CT scan (lower left) and coronal (lower center) and sagittal (lower right) MR images confirming complete removal of the mass along with removal of the posterior hippocampal formation.

This aneurysm was finally treated successfully by using an endovascular coiling procedure because neither direct clipping nor BA occlusion was possible. Patency of the OA-PCA bypass was not confirmed at the time of the aneurysm coiling procedure.

Postoperative Course. The patient was discharged in April 1999, with unchanged ophthalmoplegia.

Comment. This case also demonstrates the feasibility of using the SCTT approach for posterior fossa revascularization (OA-PCA bypass or OA-SCA bypass), although bypass patency could not be confirmed at the time of follow-up angiography. Vascularization performed using this approach does not compromise the performance of either the pterional or the subtemporal approach for aneurysms of this location.

Case 3

This 37-year-old woman was admitted to the hospital in May 1999 because she suffered from medically intractable partial epilepsy with complex partial seizures (manifested by episodes of flush over the entire body).

Examination. Magnetic resonance images revealed a mass in the posterior hippocampus on the dominant (left) side (Fig. 4 upper). The lesion was removed via a left-

sided SCTT approach. The lesion was difficult to find because it was located subcortically; however, it was successfully localized with the aid of intraoperative electrocorticography, which revealed spiking around the periphery of the lesion. The final histopathological diagnosis was low-grade astrocytoma (WHO⁷ Grade II). There were no surgical complications and the patient was discharged 13 days after admission.

Postoperative Course. Follow-up MR images obtained 3 months later revealed complete removal of the posterior hippocampal formation without any sign of residual tumor (Fig. 4 lower). The patient has remained seizure free since then.

Comment. The alternative approach to removing this tumor—a conventional temporal approach—would have been difficult to perform without retraction or incision of the dominant temporal lobe, which would have increased the risk of a neurological complication.

Results

Characteristics of the patients and operative results are listed in Table 1. There were no postoperative complications related to the SCTT approach.

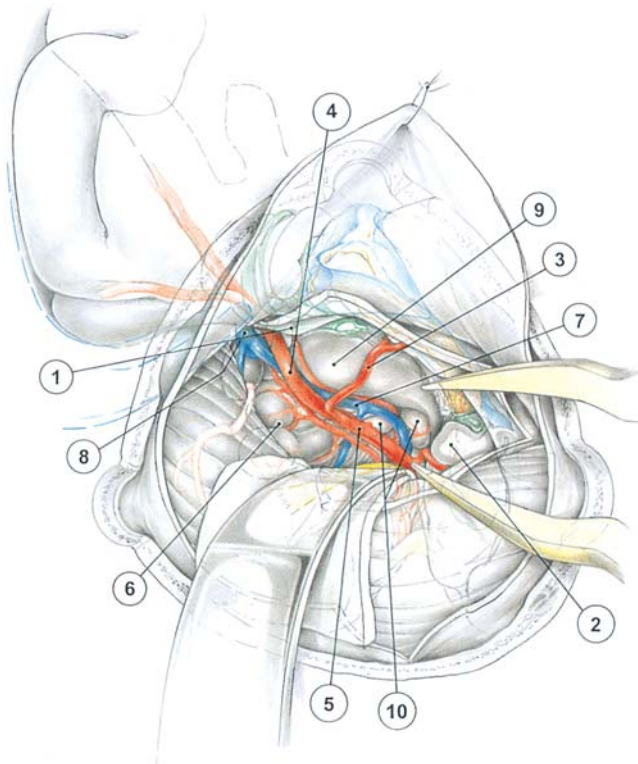


FIG. 5. Drawing demonstrating the anatomy of the posterior temporomedial region after removal of the posterior hippocampal formation. 1 and 2 = parahippocampal gyri; 3 = PTA; 4 = parieto-occipital artery; 5 = P₂; 6 = quadrigeminal plate; 7 = vein of Rosenthal; 8 = vein of Galen; 9 = pulvinar; 10 = medial and lateral geniculate bodies.

Discussion

Anatomical Structure of the Tentorium and the Posterior Temporomedial Territory of the Brain

Knowledge of the topographical anatomy around the tentorial incisura¹⁵ is necessary for the performance of this surgery. One must take care to minimize injury to the bridging veins between the cerebellum and the tentorium. In our experience, however, significantly large bridging veins must be coagulated and cut in approximately one third of cases to make this approach feasible. We have not experienced any complications after this vein sacrifice, although such complications have been reported by others.⁶

The tentorium may contain large venous lakes or sinuses, which are reportedly most commonly located in its medial third portion.⁹ These should be carefully closed using metal clips when the tentorium is incised. The incision is best made from the lateral to the medial end because the free edge of the tentorium suddenly becomes steep toward its medial end, and is thus difficult to cut from the medial to the lateral end.

Upon a slightly downward retraction of the incised tentorium together with the cerebellum, one obtains an overview of the posterior temporomedial structures around the tentorial notch: the isthmus, parahippocampal gyrus, lingual gyrus, PCA with its branches (including the PTA and the parietooccipital artery) and other structures including the SCA, trochlear nerve, quadrigeminal plate, pi-

neal body, and vein of Galen with its major tributaries (Fig. 1C).

Removal of the parahippocampal gyrus yields exposure of the following structures: the pulvinar, lateral and medial geniculate bodies, crus cerebri, vessels such as the vein of Rosenthal and its tributaries, the trunk of the PCA with its branches, and the temporal horn with its choroid plexus (Fig. 5).

Incision and replacement of the tentorium have caused no complications so far, except for temporary bradycardia or arrhythmia in some patients at the time of the incision. These may have been caused by trigeminal nerve irritation, and the anesthesiologist should be forewarned of this possibility.

Surgical Approaches

The infratentorial supracerebellar approach was first reported by Oppenheim and Krause¹² in 1913 and was later refined by Zapletal³⁰ and Stein.¹⁷ It was advocated by Yasargil^{21,22} in 1984 and, subsequently, by others as a useful approach to the dorsal portion of the midbrain and pons.^{6,11,28} The advantages and disadvantages of surgery performed while the patient is in the sitting position have been discussed elsewhere.^{16,25}

The SCTT approach described by Voigt and Yasargil²⁰ in 1976 has two major advantages. 1) It provides ease of access to the posterior hippocampus, enabling posterior hippocampectomy, which could not be performed via Yasargil's transsylvian-transventricular approach^{24,29} or other approaches^{3,10,13,19} without risking injury to normal structures and, thus potentially leading to a postoperative neurological deficit. 2) It provides ease of access to the P₂-P₃ junction of the PCA and, thus, aneurysms at this site may be managed with minimal risk. We consider the SCTT approach to be as good as, or better than, all other aforementioned approaches: subtemporal, occipital interhemispheric, and transsylvian-transventricular.

A microsurgical OA-PCA bypass procedure can be performed without retraction of the temporal lobe, which has been one of the causes of serious complications of revascularization procedures to the PCA or the SCA.^{1,18,26} A bypass procedure of this kind performed via the SCTT approach remains technically difficult, however, because the bypass site lies very deep within the surgical opening.

The technique described in this paper differs slightly from that of the original description by Voigt and Yasargil²⁰ in that a paramedian rather than midline craniotomy is performed. We believe this variation offers easier access to more laterally localized lesions.

Conclusions

The SCTT approach performed with the patient in the sitting position is used to greatest benefit in surgery of the posterior temporomedial region: removal of tumors in this location, posterior hippocampectomy, clipping of aneurysms located at the P₂-P₃ junction, and OA-PCA bypass.

Acknowledgments

The authors are indebted to Mrs. Schurter and Ms. Frick for their secretarial assistance and to Mr. Stillhard for his photographic work.

References

1. Ausman JI, Diaz FG, de los Reyes RA, et al: Posterior circulation revascularization. Superficial temporal artery to superior cerebellar artery anastomosis. **J Neurosurg** **56**:766–776, 1982
2. Drake CG: Report of World Federation of Neurological Surgeons (sic) Committee on a Universal Subarachnoid Hemorrhage Grading Scale. **J Neurosurg** **68**:985–986, 1988 (Letter)
3. Hori T, Kondo S, Takenobu A, et al: Retrolabyrinthine presigmoid transpetrosal approach for selective subtemporal amygdalohippocampectomy. **Neurol Med Chir** **39**:214–225, 1999
4. Jennett B, Bond M: Assessment of outcome after severe brain damage. A practical scale. **Lancet** **1**:480–484, 1975
5. Kaku Y, Yonekawa Y, Taub E: Transcollicular approach to intrinsic tectal lesions. **Neurosurgery** **44**:338–344, 1999
6. Kanno T, Kasama A, Shoda M, et al: Intraoperative monitoring on the occlusion of the venous system. **Neurosurgons** **11**: 51–59, 1992
7. Kleihues P, Berger PC, Scheithauer BW: The new WHO classification of brain tumours. **Brain Pathol** **3**:255–268, 1993
8. Mabuchi S, Kamiyama H, Kuroda S, et al: Occipital interhemispheric approach for distal posterior cerebral artery (P₃) aneurysms. **Surg Cereb Stroke** **23**:163–166, 1995
9. Muthukumar N, Palaniappan P: Tentorial venous sinuses: an anatomical study. **Neurosurgery** **42**:363–371, 1998
10. Niemeyer P: The transventricular amygdala-hippocampectomy in temporal lobe epilepsy, in Baldwin M, Bailey P (eds): **Temporal Lobe Epilepsy**. Springfield, IL: Charles C Thomas, 1958, pp 461–482
11. Ogata N, Yonekawa Y: Paramedian supracerebellar approach to the upper brain stem and peduncular lesions. **Neurosurgery** **40**:101–105, 1997
12. Oppenheim H, Krause F: Operative Erfolg bei Geschwülsten der Sehhügel- und Vierhügelgegend. **Berl Klin Wochenschr** **50**:2316–2322, 1913
13. Park TS, Bourgeois BFD, Silbergeld DL, et al: Subtemporal transparahippocampal amygdalohippocampectomy for surgical treatment of mesial temporal lobe epilepsy. Technical note. **J Neurosurg** **85**:1172–1176, 1996
14. Peerless SJ, Drake CG: Posterior circulation aneurysms, in Wilkins RH, Rengachary SS (eds): **Neurosurgery**. New York: McGraw-Hill, 1985, Vol 2, pp 1422–1437
15. Rhoton AL Jr, Ono M: Microsurgical anatomy of the region of the tentorial incisura, in Wilkins RH, Rengachary SS (eds): **Neurosurgery**. New York: McGraw-Hill, 1996, Vol 1, pp 897–915
16. Standefer M, Bay JW, Trusso R: The sitting position in neurosurgery: a retrospective analysis of 488 cases. **Neurosurgery** **14**:649–658, 1984
17. Stein BM: The infratentorial supracerebellar approach to pineal lesions. **J Neurosurg** **35**:197–202, 1971
18. Sundt TM Jr, Piepgras DG, Houser OW, et al: Interposition saphenous vein graft for advanced occlusive disease and large aneurysms in the posterior circulation. **J Neurosurg** **56**: 205–215, 1982
19. Vajkoczy P, Krakow K, Stodieck S, et al: Modified approach for the selective treatment of temporal lobe epilepsy: transsylvian-transcisternal mesial en bloc resection. **J Neurosurg** **88**: 855–862, 1998
20. Voigt K, Yasargil MG: Cerebral cavernous haemangiomas or cavernomas. Incidence, pathology, localization, diagnosis, clinical features and treatment. Review of the literature and report of an unusual case. **Neurochirurgia** **19**:59–68, 1976
21. Yasargil MG: **Microneurosurgery**. Stuttgart: Thieme, 1984, Vol 1, p 242
22. Yasargil MG: **Microneurosurgery**. Stuttgart: Thieme, 1984, Vol 2, pp 232–295
23. Yasargil MG: **Microneurosurgery**. Stuttgart: Thieme, 1984, Vol 4A, 1984, pp 308–309
24. Yasargil MG, Teddy PJ, Roth P: Selective amygdalo-hippocampectomy: operative anatomy and surgical technique. **Adv Techn Stand Neurosurg** **12**:93–123, 1985
25. Yonekawa Y: Posterior circulation revascularization—our indication, techniques and results, in Hashi K, Saito I (eds): **Proceedings of the 6th Meeting of The Mt. Fuji Workshop on CVD**. Tokyo: Kodama, 1988, pp 71–76
26. Yonekawa Y: Problems and their management in the operating sitting position. **Neurosurgons** **8**:50–58, 1989
27. Yonekawa Y, Kaku Y, Imhof HG, et al: Posterior circulation aneurysms. Technical strategies based on angiographic, anatomical findings and the results of 60 recent consecutive cases. **Acta Neurochir Suppl** **72**:123–140, 1999
28. Yonekawa Y, Kaku Y, Taub E, et al: New aspects of the infratentorial supracerebellar approach: technical note and summary of results. **Kitakanto Med J (Suppl 1)**:15–22, 1998
29. Yonekawa Y, Leblebicioglu-Könu D, Strommer K, et al: Selective amygdalohippocampectomy according to Yasargil-Wieser for intractable epilepsy. **Neurosurgons** **15**:184–191, 1996
30. Zapletal B: Ein neuer operativer Zugang zum Gebiet der incisura Tentorii. **Zentralbl Neurochir** **16**:64–69, 1956

Manuscript received December 20, 1999.

Accepted in final form October 4, 2000.

Address reprint requests to: Yasuhiro Yonekawa, M.D., Department of Neurosurgery, University Hospital, Frauenklinikstrasse 10, CH-8091 Zürich, Switzerland. email: yonekawa@nch.unizh.ch.