

# Successful Treatment of a Ruptured Enlarged Infundibular Widening of the Posterior Communicating Artery

## —Case Report—

Seikou KUWAHARA, Shigetoshi UGA\*, and Koreaki MORI\*\*

Departments of Neurosurgery and \*Internal Medicine, Kouhoku National Health Insurance Hospital of Sakawa-cho, Kochi; \*\*Department of Neurosurgery, Kochi Medical School, Nankoku, Kochi

### Abstract

A 67-year-old female with a history of hypertension and cerebral infarction presented with subarachnoid hemorrhage (SAH) (Hunt and Kosnik grade 4). Brain computed tomography (CT) revealed a clot dominantly on the right (Fisher's classification Group 4). Cerebral angiography showed funnel-shaped widenings at the origins of the bilateral posterior communicating arteries. The maximum diameter of the widening was greater than 3 mm, so this widening was called an enlarged infundibular widening. Angiography showed a small bulge protruding posterolaterally from the wall of the right enlarged infundibular widening, and the right posterior communicating artery arose from the apex of the enlarged infundibular widening. Based on the findings of the brain CT and cerebral angiography, the diagnosis was SAH due to rupture of the right enlarged infundibular widening. Approximately 12 hours after the onset, the clot was evacuated through the right pterional approach. Bleeding from the small bulge of the right enlarged infundibular widening occurred intraoperatively, so a right-angled ring clip was applied parallel to the right internal carotid artery to obliterate the rupture point. Postoperatively, she was discharged without neurological deficit, and follow-up CT showed no other new infarction. We recommend clipping rather than wrapping or coating for similar cases of ruptured enlarged infundibular widening.

Key words: infundibular widening, subarachnoid hemorrhage, rupture

### Introduction

Infundibular widening most frequently occurs at the origin of the posterior communicating artery (PcomA) at its junction with the internal carotid artery (ICA). The angiographic criteria for the diagnosis of infundibular widening are: the PcomA is recognized at the tip of the infundibular widening; the maximum diameter is less than 3 mm; the shape is round or conical, but not saccular nor irregular; and there is no aneurysm-like neck.<sup>14)</sup> The incidence of infundibular widening is about 5–17% on carotid angiography, and increases with age.<sup>4,8,12,15)</sup> Infundibular widening usually does not rupture, but has caused fatal subarachnoid hemorrhage (SAH)<sup>1,12)</sup> and development of cerebral aneurysm.<sup>3,10,11,17,18)</sup>

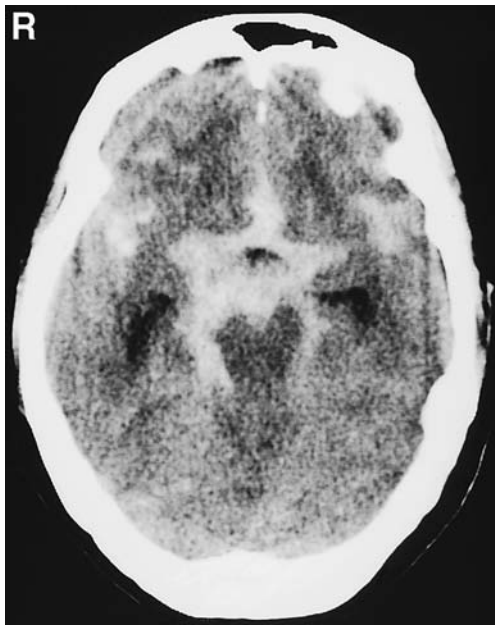
Here, we describe the successful treatment of a

case of ruptured enlarged infundibular widening.

### Case Report

A 67-year-old female with a history of hypertension and cerebral infarction presented with sudden severe headache and vomiting on September 13, 1999. Brain computed tomography (CT) on admission showed diffuse SAH with the clot located predominantly on the right (Fisher's classification Group 4) (Fig. 1). Her consciousness level was 100 on the Japan Coma Scale, and she had no focal neurological dysfunction (Hunt and Kosnik grade 4).

Right carotid angiography showed a posterolaterally directed funnel-shaped widening at the origin of the PcomA. The right PcomA was confirmed to arise from the apex of the widening. The maximum diameter of the widening was larger than 3 mm, so it was not a usual infundibular widening, and is described here as an enlarged infundibular widening.



**Fig. 1** Brain computed tomography scan showing diffuse subarachnoid hemorrhage and a clot predominantly located on the right.

A small bulge was also observed protruding posterolaterally from the enlarged infundibular widening (Fig. 2A, B). Left carotid angiography also demonstrated an enlarged infundibular widening without an irregular wall at the origin of the PcomA (not shown). Vertebral angiography detected no causative vascular lesion of the SAH in the posterior circulation. Based on the findings of the brain CT and cerebral angiography, the diagnosis was SAH due to rupture of the right enlarged infundibular widening.

Approximately 12 hours after the onset, the subarachnoid clot was evacuated from the right sylvian and carotid cisterns through the right pterional approach. The right ICA and the origin of the right PcomA (enlarged infundibular widening) were clearly observed. A small bulge of 2 mm in diameter was also noticed protruding posterolateral-inferiorly from the wall of the enlarged infundibular widening, and located close to the distal junction of the right ICA-PcomA bifurcation. The wall of the bulge was very thin and its color was reddish. The wall of the enlarged infundibular widening except for the small bulge showed no arteriosclerotic change (Fig. 3 left). Sudden arterial bleeding from the small bulge occurred during observation around the right ICA and PcomA. Wrapping or coating was considered inadequate to control the bleeding from the infundibular widening. Therefore, a right-angled ring clip (Sugita

clip No. 41) was placed parallel to the ICA to obliterate the bleeding point (Fig. 3 right). Special care was taken to preserve the right anterior choroidal artery (AchA) and PcomA. The remnant of the enlarged infundibular widening was completely wrapped with Bemsheet.

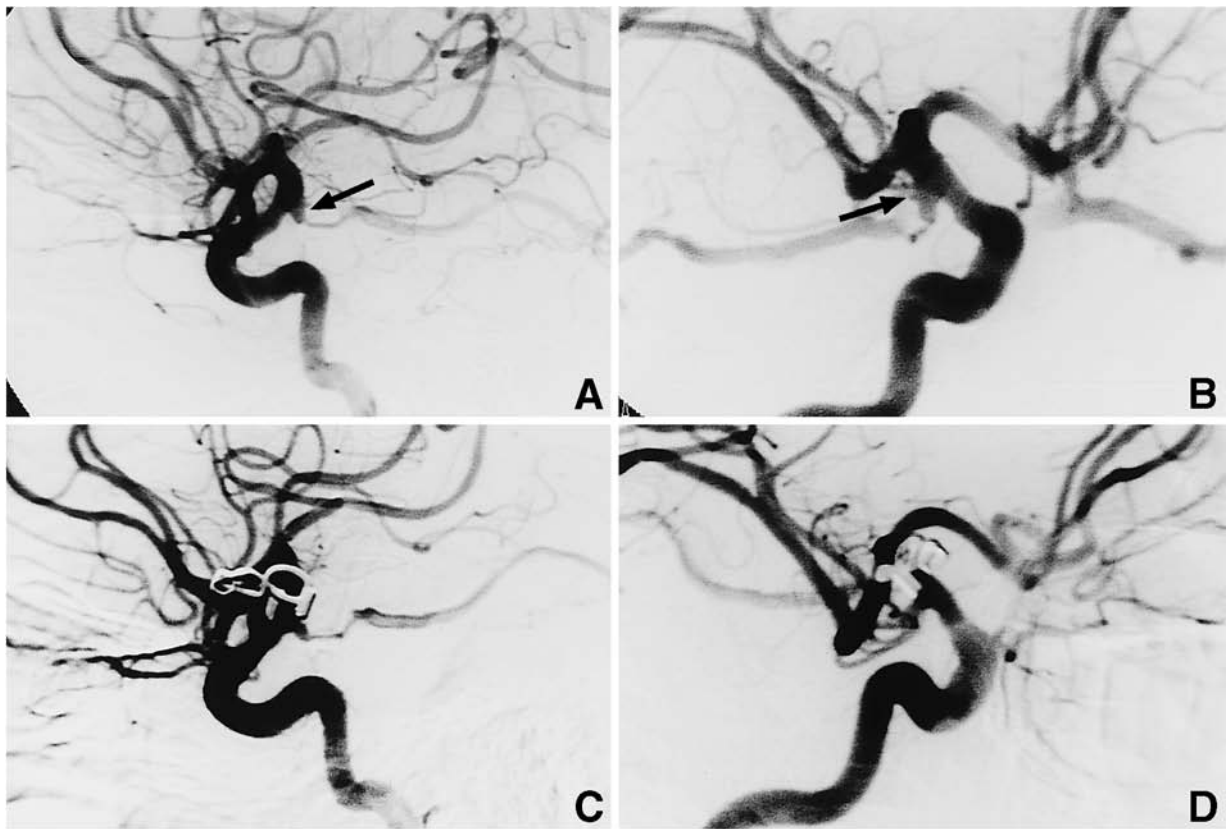
Postoperatively, the patient developed left hemiparesis but recovered gradually with improvement of consciousness. Follow-up brain CT showed no new infarction area caused by the surgical procedure or vasospasm. Approximately 3 months after the operation, the right carotid angiography revealed remnants of the right infundibular widening with obliteration of the small bulge. The cause of poor filling of the AchA remained unknown (Fig. 2C, D). The left enlarged infundibular widening was left untreated since the patient's consent could not be obtained. She was discharged without neurological deficits in December 1999, and she began leading an ordinary life as a housewife in August 2000.

## Discussion

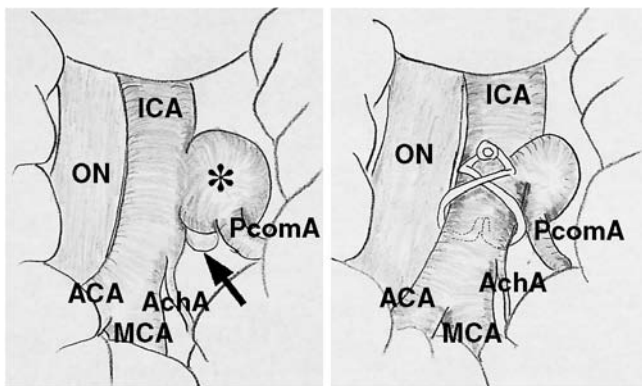
Some infundibular widenings of the PcomA may present as a preaneurysmal lesion or a cause of SAH previously ascribed to unknown origin. Infundibular widening of the PcomA is neither an aneurysmal nor preaneurysmal lesion based on the findings of normal vascular morphology in a series of autopsy specimens.<sup>6)</sup> On the other hand, the degenerative changes or defects in the muscular layer of the tunica media and/or the internal elastic lamina of the infundibular widening are identical with those of minute aneurysms.<sup>1,7,16)</sup> The occurrence and growth of infundibular widening seems to be influenced by the balance between the local tissue fragility of the infundibular wall and the hemodynamic stress.<sup>4)</sup>

Analysis of the intraoperative and angiographic findings of 34 lesions at the ICA-PcomA junction identified preoperatively as unruptured aneurysms because of a diameter exceeding 3 mm, non-visualized PcomA, or PcomA not originating at the apex of the widening found that six of the lesions were true aneurysms, four were enlarged infundibular widenings with reddish bulges (i.e., preaneurysmal bulge), and 24 were merely enlarged infundibular widenings without wall abnormality.<sup>5)</sup> The diagnosis of cerebral aneurysm should not be based simply on the size and shape of the dilatation, especially if the PcomA does not fill or appears very small on carotid angiography.

Observation of the flow pattern in a replica of a ruptured ICA-PcomA aneurysm showed that at the aneurysm origin, the blood flow entered through the



**Fig. 2** Preoperative right carotid angiograms, lateral (A) and right anterior oblique (B) views, demonstrating an enlarged funnel-shaped infundibular widening with a small bulge (arrow) at the distal border of the internal carotid artery and posterior communicating artery (PcomA) junction. Postoperative right carotid angiograms, lateral (C) and right anterior oblique (D) views, showing remnants of the infundibular widening with good filling of the right PcomA, but the small bulge is obliterated by the clipping.



**Fig. 3** Illustration of the intraoperative findings. *left:* The enlarged infundibular widening (asterisk) has a small bulge (arrow) protruding posterolateral-inferiorly. The bulge had a very thin wall and the size was about 2 mm. The bulge is located close to the distal junction of the right internal carotid artery (ICA)-posterior communicating artery (PcomA) bifurcation. The wall of the enlarged infundibular widening except for the bulge showed no arteriosclerotic change. The bleeding point was in the small bulge. *right:* A right-angled ring clip (Sugita clip No. 41) was placed parallel to the right ICA to obliterate the bleeding point. ACA: anterior cerebral artery, AchA: anterior choroidal artery, MCA: middle cerebral artery, ON: optic nerve.

distal aneurysmal neck, struck the distal lateral aneurysmal wall and then swirled slowly in a reverse vertical pattern within the aneurysm sac, and finally exited through the proximal aneurysmal neck.<sup>9)</sup> The flow pattern clearly showed an impact zone of the entering blood flow which indicates the

point of aneurysm rupture. This observation was consistent with our intraoperative finding in the present case and suggests check points for the angiographical interpretation of cerebral aneurysm or infundibular widening.

Progression of infundibular widening to true aneurysm is rare,<sup>2,3,10,11,13,17-21</sup> and the average interval for detection of the developed aneurysm is 7 years. Therefore, a long period of follow up is necessary for patients with infundibular widening. More careful observation should be performed, especially in cases of infundibular widening<sup>4</sup>) associated with a contralateral ICA-PcomA aneurysm, in young patients, in hypertensive patients, with well-developed PcomA, with a great divergent angle with respect to the ICA, or associated with a small bulge of the wall as in the present case.

When the infundibular widening or enlarged infundibular widening ruptures, surgical treatment should be performed for complete repair of the lesion. From our experience in the present case, we recommend clipping to control the bleeding and reconstruction of the ICA rather than wrapping of the infundibular widening or coating of the bleeding point. Clipping procedure to obliterate the bleeding point is considered more reliable for controlling the arterial bleeding from the infundibular widening. Preservation of the PcomA and AchA naturally follows. However, the optimum practical procedure must be selected from clipping, wrapping, coating, or others on the basis of the operative findings or the expertise of the neurosurgeon.

## References

- 1) Archer CR, Silbert S: Infundibula may be clinically significant. *Neuroradiology* 15: 247-251, 1978
- 2) Björkesten G, Troupp H: Changes in the size of intracranial arterial aneurysms. *J Neurosurg* 19: 583-588, 1962
- 3) Drake CG: On the surgical treatment of ruptured intracranial aneurysms. *Clin Neurosurg* 13: 122-155, 1966
- 4) Ebina K, Ohkuma H, Iwabuchi T: An angiographic study of incidence and morphology of infundibular dilatation of the posterior communicating artery. *Neuroradiology* 28: 23-29, 1986
- 5) Endo S, Furuichi S, Takaba M, Hirashima Y, Nishijima M, Takaku A: Clinical study of enlarged infundibular dilatation of the origin of the posterior communicating artery. *J Neurosurg* 83: 421-425, 1995
- 6) Epstein F, Ransohoff J, Budzilovich GN: The clinical significance of junctional dilatation of the posterior communicating artery. *J Neurosurg* 33: 529-531, 1970
- 7) Hassler O, Saltzman GF: Histologic changes in infundibular widening of the posterior communicating artery: a preliminary report. *Acta Path Microbiol Scand* 46: 305-312, 1959
- 8) Hassler O, Saltzman GF: Angiographic and histologic change in infundibular widening of the posterior communicating artery. *Acta Radiol [Diagn] (Stockholm)* 1: 321-327, 1963
- 9) Imbesi SG, Kerber CW: Analysis of slipstream flow in two ruptured intracranial cerebral aneurysms. *AJNR Am J Neuroradiol* 20: 1703-1705, 1999
- 10) Itakura T, Ozaki F, Nakai E, Fujii T, Hayashi S, Komai N: Bilateral aneurysm formation developing from junctional dilatation (infundibulum) of the posterior communicating arteries: case report. *J Neurosurg* 58: 117-119, 1983
- 11) Marshman LAG, Ward PJ, Walter PH, Dossetor RS: The progression of an infundibulum to aneurysm formation and rupture: case report and literature review. *Neurosurgery* 43: 1445-1449, 1998
- 12) Ohyama T, Ohara S, Momma F: Fatal subarachnoid hemorrhage due to ruptured infundibular widening of the posterior communicating artery. *Neurol Med Chir (Tokyo)* 34: 172-175, 1994
- 13) Patrick D, Appleby A: Infundibular widening of the posterior communicating artery progressing to true aneurysm. *Br J Radiol* 56: 59-60, 1983
- 14) Pool JL, Potts DG: *Aneurysms and Arteriovenous Anomalies of the Brain: Diagnosis and Treatment*. New York, Harper & Row, 1965, pp 132-133
- 15) Saltman GF: Infundibular widening of the posterior communicating artery studied by carotid angiography. *Acta Radiol* 51: 415-421, 1959
- 16) Stehbens WE: Histopathology of cerebral aneurysms. *Arch Neurol (Chicago)* 8: 272-285, 1963
- 17) Stuntz JT, Ojemann GA, Alvord EC: Radiographic and histologic demonstration of an aneurysm developing on the infundibulum of the posterior communicating artery: case report. *J Neurosurg* 33: 591-595, 1970
- 18) Trasi S, Vincent LM, Zingesser LH: Development of aneurysm from infundibulum of posterior communicating artery with documentation of prior hemorrhage. *AJNR Am J Neuroradiol* 2: 368-370, 1981
- 19) Waga S, Morikawa A: Aneurysm developing on the infundibular widening of the posterior communicating artery. *Surg Neurol* 11: 125-127, 1979
- 20) Yoshimoto T, Suzuki J: Surgical treatment of an aneurysm on the funnel-shaped bulge of the posterior communicating artery: case report. *J Neurosurg* 41: 377-379, 1974
- 21) Young B, Meacham WF, Allen JH: Documented enlargement and rupture of a small arterial sacculaton: case report. *J Neurosurg* 34: 814-817, 1971

---

Address reprint requests to: S. Kuwahara, M.D., Department of Neurosurgery, Kouhoku National Health Insurance Hospital of Sakawa-cho, 1687 Sakawa-cho, Takaoka-gun, Kochi 789-1201, Japan.