

Psychotic depression after a fall

N Tabet MSc MRCPsych C Fraser FRCR¹

J R Soc Med 2001;94:83–84

Psychiatric disorders are a common sequel to head injury¹ but trauma is easily missed in a patient with an array of psychiatric symptoms and no neurological signs.

CASE HISTORY

A man aged 79 attended his local accident and emergency department with right hip pain after a fall. Physical examination and a hip X-ray revealed no abnormality, and he was discharged home. Over the next few weeks his family noticed a rapidly progressive change in his behaviour and mood. He ate less, lost interest in his personal hygiene, lacked energy, became very agitated, and substantially increased his alcohol intake. He also expressed paranoid and suicidal ideations, had fears that he was harbouring a cancerous growth, and was relentlessly preoccupied with financial worries. In view of the rapid mental deterioration he was admitted to hospital where a dual diagnosis of psychotic depression and alcohol dependence syndrome was made in accordance with *ICD 10* guidelines.

Nothing abnormal was evident on neurological examination. On cognitive examination, he was fully conscious and oriented to place and person though only partly to time. Treatment was started with an antidepressant (citalopram), thiamine and a reducing dose of benzodiazepine (chlordiazepoxide). Over the next few days he remained depressed and suspicious, and was at times very agitated. Six days after admission, however, he became mildly drowsy—a change initially attributed to the benzodiazepine and antidepressant medication. Neurological findings were unaltered; Glasgow Coma Score was 15/15. Since drowsiness persisted after discontinuation of chlordiazepoxide, a computed tomographic (CT) scan of the brain was arranged. This showed a large subdural haematoma, extending from the midline in the anterior cranial fossa to the trocula posteriorly. Much of the collection was of low density, but there were also areas of high density (Figure 1). The patient was transferred to the regional neurosurgical unit where he was treated conserva-

tively because of pneumonia unresponsive to antibiotics. He died two weeks later, and necropsy was not done.

COMMENT

We suspect that this patient sustained a head injury at the time of his original fall but the CT scan also showed evidence of more recent bleeding¹. High density signifies an acute bleed while low density characterizes chronic subdural haematoma. In patients whose CT scan shows a high-density collection, symptoms develop an average of 5 days after head injury; with low-density collections the interval is 105 days². These changes reflect the evolution of the clots, which pass through an intermediate isodense phase in which they are hard to distinguish from nearby brain structures³. The coincidence of high-density and low-density areas in a subdural haematoma is unusual, and suggests acute bleeding into a longstanding collection.

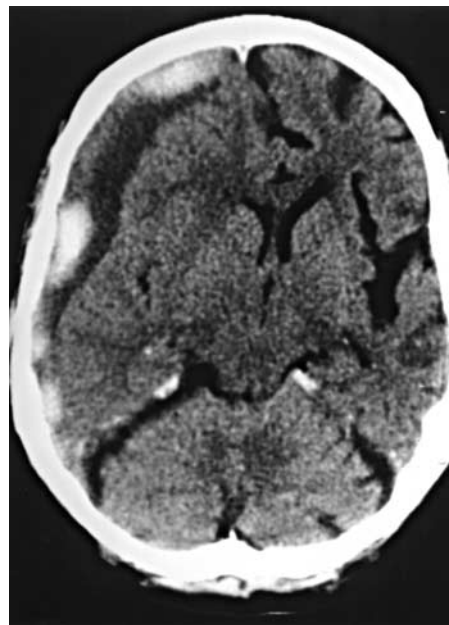


Figure 1
Computed tomographic scan showing subdural haematoma with high-density and low-density areas

Chronic subdural haematoma has been called the great imitator⁴, and the initial head trauma may go unnoticed in more than one-third of patients⁵. When the presenting feature is depression without neurological signs, subdural haematoma is especially likely to escape detection. Fortunately, this seems to be a rare event: a search of English-language publications yielded only two cases in which depression was the sole presenting feature of subdural haematoma.

It was the onset of drowsiness that prompted the request for a CT scan. Initially this was attributed to the medication prescribed: drowsiness is commonly seen in the elderly after initiation of treatment with benzodiazepines or antidepressant/antipsychotic drugs. In a depressed patient

Department of Old Age Psychiatry, Maudsley Hospital, London SE5 8AZ;
¹Department of Radiology, Farnborough Hospital, Farnborough BR6 8ND, UK
Correspondence to: Dr N Tabet
E-mail: n.tabet@iop.kcl.ac.uk

whose drowsiness seems not to be explained by the prescribed medication, an early CT scan of the brain may be lifesaving.

REFERENCES

- 1 Barrett K. Psychiatric sequelae of acquired brain injury. *Adv Psychiatr Treatment* 1999;5:250–60
- 2 Haar FL, Lott TM, Nichols P Jr. The usefulness of CT scanning for subdural haematomas. *Neurosurgery* 1977;1:272–5
- 3 Traynelis VC. Chronic subdural hematoma in the elderly. *Clin Geriatr Med* 1991;7:583–98
- 4 Potter JF, Fruin AH. Chronic subdural hematoma—the “great imitator”. *Geriatrics* 1977;32:61–6
- 5 Cameron MM. Chronic subdural haematoma: a review of 114 cases. *J Neurol Neurosurg Psychiatry* 1978;41:834–9
- 6 Black DW. Mental changes resulting from subdural haematoma. *Br J Psychiatry* 1984;145:200–3

Pel-Ebstein fever with cyclical pancytopenia

W J Chng MRCP M R Howard FRCP FRCPATH¹

J R Soc Med 2001;94:84–85

Occasionally, Hodgkin’s disease gives rise to the cyclical fever described by Pel and Ebstein. An accompanying cyclical pancytopenia has only once been reported.

CASE HISTORY

A previously well man aged 40 years was referred for investigation of a fluctuating pyrexial illness. For six weeks he had had cyclical arthralgia, myalgia, headaches, pyrexia and night sweats; the symptoms lasted about a week, then entirely resolved and returned every two weeks. There was no history of foreign travel. On examination when symptomatic he was pyrexial, pale and clammy. There was initially no palpable lymphadenopathy or jaundice. Examination was otherwise unremarkable. Investigation revealed pancytopenia (haemoglobin 10.7 g/dL, white cells $1.9 \times 10^9/L$, neutrophils $1.1 \times 10^9/L$, platelets $82 \times 10^9/L$) and abnormal liver function tests (alanine aminotransferase 107 iu/L, gamma-glutamyltransferase 88 iu/L, alkaline phosphatase 245 iu/L, bilirubin $30 \mu\text{mol/L}$); C-reactive

protein was raised at 193 mg/L and the erythrocyte sedimentation rate was 96 mm/h. Renal function, blood glucose and coagulation screen were normal. Direct antiglobulin test was negative and haptoglobin levels were normal. Three sets of blood cultures and a urine culture were negative (including cultures for mycobacterium). Hepatitis serology and viral serology were also negative. Chest X-ray and transthoracic cardiac echocardiogram were normal. Abdominal ultrasound revealed only a moderately enlarged spleen. Bone marrow aspiration and trephine biopsy demonstrated a hypercellular marrow with marked dyserythropoiesis and increased number of atypical megakaryocytes, suggesting a possible diagnosis of myelodysplastic syndrome (refractory anaemia type). He was

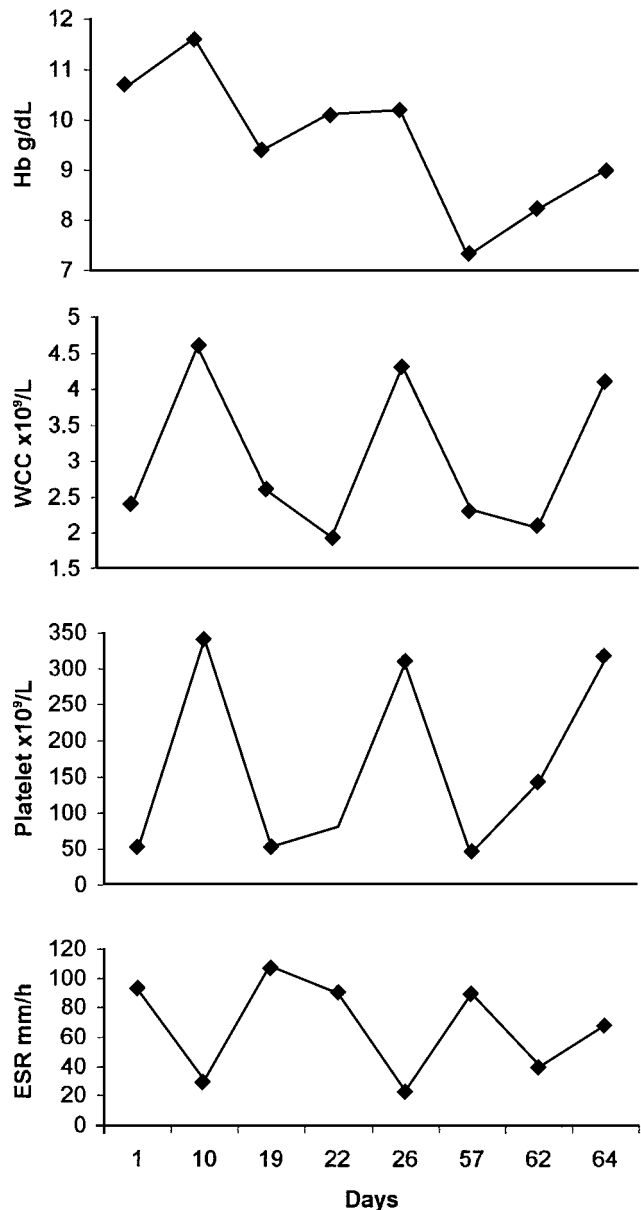


Figure 1 Cyclical pancytopenia coinciding with raised erythrocyte sedimentation rate (ESR). WCC=white cells; Hb=haemoglobin

Departments of Medicine and ¹Haematology, York District Hospital, York YO31 8HE, UK

Correspondence to: Dr WJ Chng, 12 Melrose Drive, Singapore 358508, Singapore

E-mail: weejoo@hotmail.com

discharged when his symptoms suddenly subsided and his blood count became normal.

When reviewed in clinic three weeks later, he was unwell with similar symptoms. Physical findings were unaltered. He again had pancytopenia with raised inflammatory markers. Computed tomographic scanning of the abdomen showed retroperitoneal lymphadenopathy with persisting splenomegaly. On re-examination, a 1 cm rubbery non-tender lymph node was palpable below the angle of his jaw and this was biopsied. Histology was of mixed cellularity Hodgkin's disease. He was started on combination chemotherapy with prompt relief of symptoms. Retrospective plotting of the blood count and inflammatory markers (Figure 1) revealed a cyclical pancytopenia exactly coinciding with his intermittent systemic upset and acute-phase response.

COMMENT

Periodic fever and systemic upset in Hodgkin's disease, a phenomenon described by Pel and Ebstein and bearing their name, is actually quite rare. The blood count and film at diagnosis is often abnormal but cyclical changes in the blood have seldom been reported. Cyclical haemolysis coinciding with Pel–Ebstein fever has been documented^{1,2}. Cyclical pancytopenia coinciding with systemic symptoms has been reported on one occasion³.

A key feature of Hodgkin's disease is deregulation of cytokine production. Reed–Sternberg cells, originating from germinal centre B-lymphocytes, secrete pro-inflammatory cytokines which mediate the systemic symptoms of the disease⁴. Pancytopenia in Hodgkin's disease has been attributed to several mechanisms. Bone marrow infiltration by tumour cells is rare but the uninvolved marrow is frequently abnormal. Reactive or dysplastic changes may accompany pancytopenia⁵. In this patient, cyclical episodes of pancytopenia coincided precisely with systemic symptoms and raised inflammatory markers. This strongly suggests that the haematological abnormalities were cytokine-induced. Why these cytokine-associated changes sometimes occur in a cyclical manner in Hodgkin's disease is unclear. Since this is the second reported case of cyclical pancytopenia associated with systemic upset in Hodgkin's disease it probably represents a real entity.

REFERENCES

- 1 McKenna W, Lampert I, Oakley C, Goldman J. Pel–Ebstein fever coinciding with cyclical haemolytic anaemia and splenomegaly in a patient with Hodgkin's disease. *Scand J Haematol* 1979;23:378–80
- 2 Ranlov O, Videbaeck A. Cyclic haemolytic anaemia synchronous with Pel–Ebstein fever in a case of Hodgkin's disease. *Acta Med Scand* 1963; 174:583–8
- 3 Dankbaar H, Williemze R, Bieger R. Bone marrow disorder in Hodgkin's disease: cyclic pancytopenia coinciding with Pel–Ebstein fever. *Neth J Med* 1983;26:74–6

- 4 Gruss HJ, Pinto A, Duyster J, Poppema S, Herrmann F. Hodgkin's disease: a tumour with disturbed immunological pathways. *Immunol Today* 1997;18:156–63
- 5 Velde JT, Den Ottolander GJ, Spaander PJ, Van Den Berg C, Hartcrink-Groenveld CA. The bone marrow in Hodgkin's disease: the non-involved marrow. *Histopathology* 1978;2:31–46

A child with pyrexia, flank pain and hip symptoms

M R Perkin MRCPCH M Warren BMBCh FRCP
D Ogilvie FRCP

J R Soc Med 2001;94:85–86

Infection of striated muscle is apt to be misdiagnosed as septic arthritis.

CASE HISTORY

A seven-year-old girl was seen in the accident and emergency department with a two-day history of pain in the left hip. There was no history of trauma but she had been febrile with temperatures up to 38 °C. Walking was uncomfortable but there was no obvious limp. Total white cell count was $16.7 \times 10^9/L$ with a neutrophilia. C-reactive protein was 57 mg/L. Ultrasound and X-rays of the hip were normal. Orthopaedic outpatient follow-up was arranged but two days later, before her appointment, she reattended the accident and emergency department with fever (37.8 °C) and persistent hip pain as well as tenderness in the left renal angle. On examination there was a swelling visible in the left paravertebral region. Ultrasound of this area as well as the abdomen was normal. Her repeat C-reactive protein was 91 mg/L and erythrocyte sedimentation rate was 86 mm/h. Blood cultures were taken.

A bone scan performed the following day showed a suggestion of increased uptake in the body of L4 on the delayed images but this was seen only on the anterior view and was thought possibly related to posture. The blood cultures grew *Staphylococcus aureus* within 24 hours, and she was started on high-dose antibiotics. On magnetic resonance imaging (MRI) the coronal T2 weighted images revealed a high signal throughout the left erector spinae muscle with a small central area of uniform high signal

Department of Public Health Sciences, St George's Hospital Medical School, London SW17 0RE, UK

Correspondence to: M R Perkin
E-mail: m.perkin@sghms.ac.uk

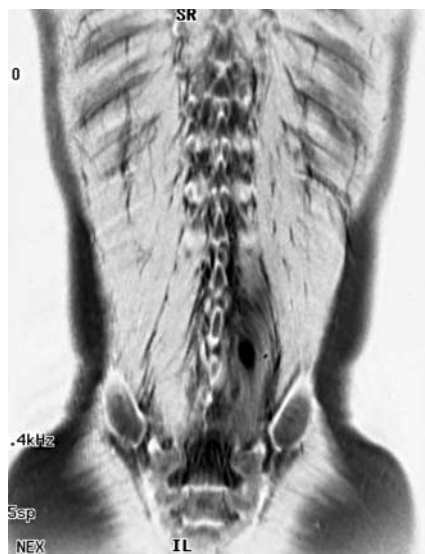

Figure 1 Coronal T₂ weighted magnetic resonance image showing abscess

suggestive of a fluid collection (Figure 1). Repeat ultrasound of the swelling disclosed that the left paravertebral muscles were bulky and more echogenic than previously, with a suspicion of an echogenic area adjacent to the L3 spinous process. Immunological investigations showed a normal nitroblue tetrazolium test, negative antistaphylococcal and antinuclease antibodies and normal total immunoglobulin levels. Initial IgG2 level was low (1.14 g/L, reference range 1.4–4.5) but normal on repeat testing two weeks later. After six weeks of antibiotic treatment the swelling had disappeared and radiological images and inflammatory markers were normal.

COMMENT

Pyomyositis is very rare in temperate climates. *S. aureus* is responsible for about 90% of cases, other pathogens being streptococci and anaerobic bacteria. In tropical climates there are two peaks in prevalence—early childhood (age 2–5) and middle age (35–40). The aetiology is uncertain. Previous trauma has sometimes been noted but other reported associations are concurrent skin or respiratory infections, muscle injury through exercise, diabetes mellitus, AIDS, steroid use and induction therapy for acute lymphocytic leukaemia.

The condition tends to occur in the muscles of the trunk and upper thigh and can lead to a misdiagnosis of septic arthritis (described with pyomyositis in the adductor, iliacus and psoas muscles)¹. Diagnosis is often delayed but ultrasound, gallium-67 scans, computed tomography and MRI have all been proved effective tools for confirming the cause^{2,3}. Blood cultures are positive in less than 5% of patients⁴. Treatment in most cases includes surgical incision and drainage but resolution without surgical intervention is well recognized⁵. Rare complications include toxic shock

syndrome and staphylococcal scalded skin syndrome⁵. The diagnosis should be suspected in any child with the triad of pyrexia, flank pain and hip symptoms².

REFERENCES

- 1 O'Reilly M, Cook JV, O'Reilly PM, Wood BP. Radiological case of the month. Psoas pyomyositis. *Arch Pediatr Adolesc Med* 1996;**150**: 1305–6
- 2 Royston DD, Cremin BJ. The ultrasonic evaluation of psoas abscess (tropical pyomyositis) in children. *Pediatr Radiol* 1994;**24**:481–3
- 3 Gordon BA, Martinez S, Collins AJ. Pyomyositis: characteristics at CT and MR imaging. *Radiology* 1995;**197**:279–86
- 4 Lenin MJ, Gardner P, Waldvogel FA. 'Tropical' pyomyositis: an unusual infection due to *Staphylococcus aureus*. *N Engl J Med* 1971;**284**: 196–8
- 5 Wong GW, Oppenheimer SJ, Evans RM, Leung SS. Pyomyositis and staphylococcal scalded skin syndrome. *Acta Paediatr* 1993;**82**:113–15

Primary *Staphylococcus aureus* meningitis in an infant

M G Gnanalingham MRCPCH M A Clarke FRCPCH

J R Soc Med 2001;**94**:86–88

Staphylococcus aureus is an unusual cause of meningitis, especially in children. In most cases there is an identifiable risk factor such as previous neurosurgery or head trauma. Primary *S. aureus* meningitis is exceptionally rare¹.

CASE HISTORY

A 3-month-old Indian girl was seen with a 2-day history of cyclical limb movements and vacant episodes; she had been febrile for 6 days. Antibiotics had not been given. There was no relevant antecedent or family history. Temperature was 38.8 °C. She was unresponsive, with a full anterior fontanelle and features of compensated shock. There was no identifiable focus of infection or rash. The provisional diagnosis was meningococcal meningitis and she was treated with intravenous fluid boluses (including 4.5% human albumin), high-dose ampicillin, cefotaxime and aciclovir and increasing doses of anticonvulsants. The initial serum investigations

Booth Hall Children's Hospital, Blackley, Manchester M9 7AA, UK

Correspondence to: Dr M G Gnanalingham, 20 Wensley Drive, Withington M20 3DD, UK E-mail: molingham@hotmail.com

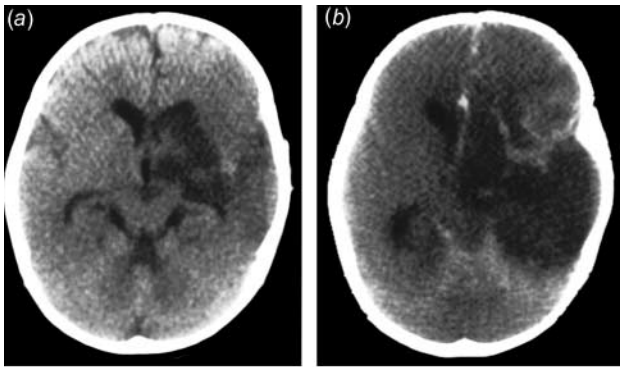


Figure 1 Contrast cranial computed tomographic scans demonstrating large left temporal infarction (a) and extension (b)

were all normal, except sodium 129 mmol/L, lactate 3.3 mmol/L and C-reactive protein 280 mg/L. Cerebrospinal fluid (CSF) showed 228×10^6 /L white blood cells (95% mononuclear cells, 5% polymorphs), 43×10^6 /L red blood cells, no organisms on Gram stain, protein 1.9 g/L and glucose 0.1 mmol/L (CSF/serum glucose ratio 0.02).

By day 2, the initial blood and CSF cultures had grown *S. aureus*, which was sensitive to flucloxacillin and fusidic acid. Flucloxacillin (100 mg/kg/day) and fusidic acid (20 mg/kg/day) were substituted for ampicillin, with continued cefotaxime treatment. By day 3, a progressive right-sided hemiparesis had developed. Cranial computed tomography (CT) with contrast revealed a large left temporal infarction (Figure 1a) without abscess formation. By day 4 she required ventilation for deteriorating respiratory function, and disseminated intravascular coagulation (DIC) developed with pancytopenia and cranial diabetes insipidus. A repeat cranial CT scan showed extension of the initial infarct (Figure 1b) with evidence of raised intracranial pressure. Brainstem death was evident and pulmonary assistance was withdrawn. A necropsy was not done. Investigations that gave normal results during her admission included an echocardiogram, metabolic screens (assays of urinary aminoacids, organic acids and orotic acid and serum aminoacids, ammonia, very long chain fatty acids, carnitine and biotinidase), immunodeficiency screens (assays of immunoglobulins and subclasses, complement, T and B lymphocyte subsets including functional assessments and nitroblue tetrazolium dye reduction test) and exclusion of *Mycobacterium tuberculosis* infection (negative gastric aspirates and blood and CSF analysis, including polymerase chain reaction [PCR] analysis).

COMMENT

During 1999 there were 68 cases of *S. aureus* meningitis in the UK, 2 (3% of them) in children (Communicable Disease Surveillance Centre, Public Health Laboratory Service, personal communication). In the USA, *S. aureus*

meningitis accounts for less than 1% of cases and carries a higher mortality than other meningitides^{2,3}. Hence the importance of early diagnosis and appropriate treatment. *S. aureus* meningitis is more common in the tropics, particularly in the Indian subcontinent⁴.

Clinical and laboratory indices do not discriminate between *S. aureus* and other bacterial meningitides. Definite diagnosis often depends on CSF culture of the organism, since Gram stain is positive in only 13–50% of cases and CSF white blood cell, protein and glucose assays are neither sensitive nor specific^{3,5}. Our patient had a CSF leucocytosis with only 5% polymorphs, though reported levels in infants are 6–83%³. The low polymorph count cannot be explained by prehospital antibiotic treatment or coexisting *M. tuberculosis* infection. *S. aureus* meningitis is usually a sequel to neurosurgical procedures (notably, insertion of ventricular shunts and drains) or head trauma^{3,6}. In the absence of such risk factors, meningitis is most likely to result from bacteraemia from another focus of infection or to be secondary to an immunodeficiency disorder. In our patient, no underlying cerebral abnormality, immunodeficiency or septic focus was apparent on admission. Since no post-mortem examination was undertaken, occult CNS malformations or other extracerebral foci of sepsis could not be excluded. In one series, occult abnormalities were found in all of the children with *S. aureus* meningitis⁶. In the future, a universal PCR technique may prove useful in *S. aureus* diagnosis⁷.

Associated findings in *S. aureus* meningitis in infants include bacteraemia (33%) and DIC (19%)³, which along with cranial diabetes insipidus were noted during the patient's rapid decline. Our patient also had a rapid extension of the initial left temporal infarction on CT imaging. Cerebral infarction is less common than haemorrhage, abscess formation, oedema and ventricular dilatation, which were detected in 52% of all CT scans undertaken in one study of adults and children⁵.

Numerous antibiotic regimens have been used in the treatment of *S. aureus* meningitis, and appropriate initial antibiotic treatment can double survival figures (76% versus 33%) in all age groups⁵. In our patient, the initial cefotaxime treatment would have had some activity against *S. aureus* but not sufficient⁸. First-line therapy for *S. aureus* is high-dose flucloxacillin plus fusidic acid or rifampicin with or without aminoglycoside⁹. Vancomycin should be reserved for methicillin-resistant *S. aureus*, unless the patient is penicillin-sensitive³. Combination therapy with vancomycin and rifampicin appears effective and prevents the emergence of rifampicin resistance¹⁰. Intrathecal antibiotic administration was contraindicated in our case, because of the clinical and radiological evidence of raised intracranial pressure. Nevertheless, in view of the rapid progression of the illness with such an aggressive organism, it seems very unlikely

that earlier institution of specific therapy would have affected the outcome.

REFERENCES

- 1 Kim JH, van der Horst C, Mulrow CD, Corey GR. *Staphylococcus aureus* meningitis: review of 28 cases. *Rev Infect Dis* 1989;5:698-706
- 2 Schlech WF III, Ward JL, Band JD, Hightower A, Fraser DW, Broome CV. Bacterial meningitis in the United States, 1978 through 1981. The National Bacterial Meningitis Surveillance Study. *JAMA* 1985;253:1749-54
- 3 Schlesinger LS, Ross SC, Schaberg DR. *Staphylococcus aureus* meningitis: a broad-based epidemiologic study. *Medicine* 1987;66:148-56
- 4 Panjarathinam R, Shah RK. Pyogenic meningitis in Ahmedabad. *Indian J Pediatr* 1993;60:669-73
- 5 Jensen AG, Espersen F, Skinhoj P, Rosdahl VT, Frimodt-Moller N. *Staphylococcus aureus* meningitis: a review of 104 nationwide, consecutive cases. *Arch Intern Med* 1993;153:1902-8
- 6 Givner LB, Kaplan SL. Meningitis due to *Staphylococcus aureus* in children. *Clin Infect Dis* 1993;16:766-71
- 7 Lu JJ, Perng CL, Lee SY, Wan CC. Use of PCR with universal primers and restriction endonuclease digestions for detection and identification of common bacterial pathogens in cerebrospinal fluid. *J Clin Microbiol* 2000;38:2076-80
- 8 Helwig HF. Cefotaxime monotherapy of bacterial meningitis caused by gram-positive pathogens. *Infection* 1985;13(suppl 1): S62-7
- 9 Quitiiani R, Cooper BW. Current concepts in the treatment of staphylococcal meningitis. *J Antimicrob Chemother* 1988;21(suppl C): 107-12
- 10 Vichaynon P, Olson LC. Staphylococcal CNS infections treated with vancomycin and rifampin. *Arch Neurol* 1984;41:637-9

Colo-broncho-cutaneous fistula complicating traumatic diaphragmatic rupture

Seema Biswas MBBS Richard J Guy MD FRCS
Robin K S Phillips MS FRCS

J R Soc Med 2001;94:88-89

Diaphragmatic rupture after high energy impact is often associated with other serious and life-threatening injuries¹.

CASE HISTORY

A previously fit 45-year-old man sustained blunt abdominal and chest injuries in a road traffic accident while abroad. He required splenectomy for splenic rupture but no other injuries were seen at laparotomy. Postoperatively he was transferred back to the UK. Over the ensuing weeks he

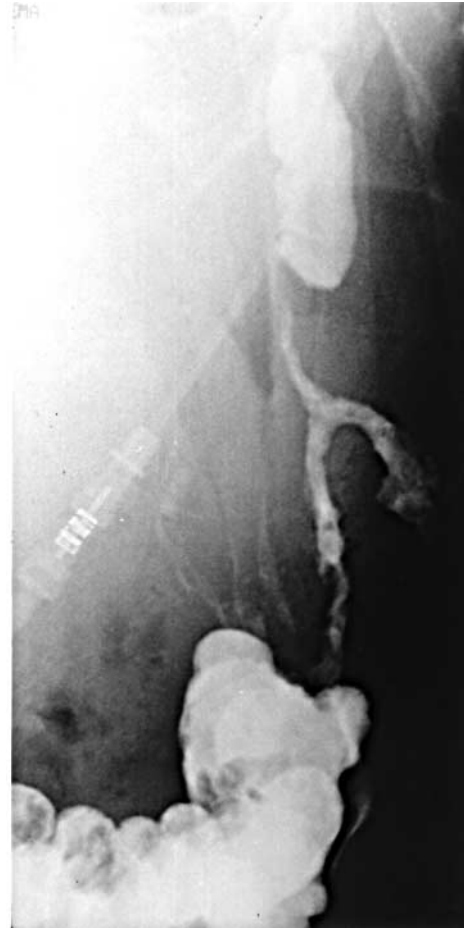

Figure 1 Sinogram showing fistula between colonic anastomosis and anterior chest wall via collections on both sides of diaphragm

experienced persistent left shoulder pain and he was admitted to hospital with increasing dyspnoea, fever and signs of sepsis. A chest radiograph suggested a large left hydropneumothorax. At left posterolateral thoracotomy he was found to have an empyema and ruptured diaphragm through which a perforated segment of transverse colon with omentum had prolapsed. After repair of the diaphragm and closure of the chest with drain insertion, transverse colectomy with primary anastomosis was performed through a midline laparotomy. His postoperative recovery was complicated by infection of the thoracotomy wound and abdominal wound dehiscence requiring resuture. A residual pleural collection also required drainage but he recovered fully.

Three months after discharge he was readmitted with a purulent and faeculent discharge from a previous anterior chest drain site. A sinogram (Figure 1) revealed a fistula between the colonic anastomosis and the chest wall via subphrenic and supraphrenic collections. Despite percutaneous drainage and parenteral nutrition he did not improve and a further laparotomy was undertaken. A colonic

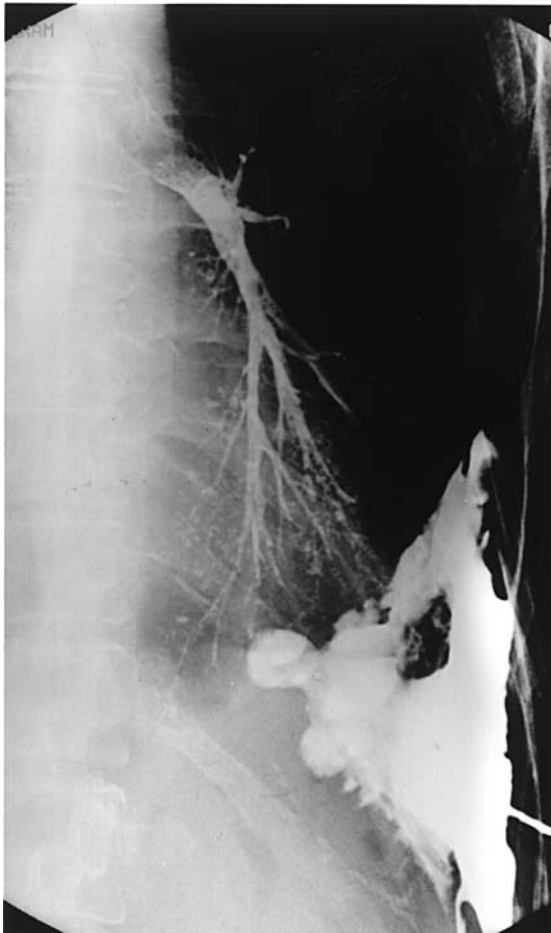


Figure 2 Gastrograffin enema delineating the bronchial tree

resection incorporating the previous anastomosis was performed and the abscess cavities were formally drained. With intensive nutritional support he made a good recovery.

Three months later he was readmitted with a recurrent faecal fistula at the same site. A water-soluble contrast enema (Figure 2) delineated the bronchial tree, signifying a colo-pleuro-broncho-cutaneous fistula. At repeat laparotomy an extended left hemicolectomy was carried out with curettage of the fistula track and insertion of a chest drain. The ascending colon and caecum were mobilized, inverted and anastomosed to the sigmoid colon, leaving the small bowel in the left upper quadrant. A defunctioning loop ileostomy was raised.

He was eventually discharged to his local cottage hospital but three weeks later he was transferred to his local district general hospital for total parenteral nutrition. He became increasingly unwell over the next day, had a respiratory arrest and died. At necropsy the death was attributed to respiratory insufficiency secondary to bronchopneumonia and left pyothorax; no recurrence of a fistula was demonstrated.

COMMENT

Almost 90% of the diaphragmatic hernias that follow blunt trauma occur on the left side, probably because of the protective effect of the liver on the right. The stomach and colon are the organs most frequently displaced into the chest. These injuries are said to occur in three distinct phases: *acute*, from the time of trauma to the apparent recovery from primary injuries; *latent*, as abdominal viscera begin to occupy the diaphragmatic defect and herniate into the thoracic cavity; and *obstructive*, as bowel obstruction and strangulation ensue. Intestinal perforation in the obstructive phase has a mortality approaching 70%².

Initial chest radiography may be normal, or misleading³, as in the present case. Finger palpation following chest drain insertion, ultrasound, computed tomography, thoracoscopy, laparoscopy and gastrointestinal contrast studies have all been reported useful in diagnosis. However, the condition may not be apparent until laparotomy or thoracotomy² and may even then be overlooked (as here). Complications such as pneumothorax and intestinal strangulation may not be recognized immediately because of the relative lack of signs and symptoms⁴. Their late diagnosis contributes to the substantial morbidity and mortality. The usual cause of death in diaphragmatic rupture is strangulation of a herniated viscus, which has a mortality of up to 66%².

Surgery for intestinal sequelae of traumatic diaphragmatic hernia is frequently associated with a poor outcome, particularly if colonic resection is required⁵⁻⁷. Sepsis and poor nutritional status contribute to complications such as wound dehiscence, anastomotic failure, fistulae, Meleney's gangrene and empyema^{3,6,7}. Faecopneumothorax and colopleural fistula have been reported after colonic resection under these circumstances^{6,7}, with death resulting from pulmonary sepsis. There are no known reports of the more complex fistula described here.

REFERENCES

- 1 Simpson J, Lobo D, Shah A, Rowlands B. Traumatic diaphragmatic rupture: associated injuries and outcome. *Ann R Coll Surg Eng* 2000;**82**:97-100
- 2 Degiannis E, Levy R, Sofianos C, Potokar T, Florizoone M, Sadiia R. Diaphragmatic herniation after penetrating trauma. *Br J Surg* 1996;**83**: 88-91
- 3 Seelig M, Klinger P, Schonleben K. Tension faecopneumothorax due to colonic perforation in a diaphragmatic hernia. *Chest* 1999;**115**:288-91
- 4 Feliciano D, Cruse P, Mattox K. Delayed diagnosis of injuries of the diaphragm after penetrating wounds. *J Trauma* 1998;**28**:1135-44
- 5 Murray J, Demetriades D, Ashton K. Acute tension diaphragmatic herniation: case report. *J Trauma* 1997;**43**:698-700
- 6 Phipps P, Jackson B. Faeco-pneumothorax as the presenting feature of a traumatic diaphragmatic hernia. *J R Soc Med* 1988;**81**:549-50
- 7 Price B, Elliot M, Featherstone G, Blesovsky A. Perforation of intrathoracic colon causing acute pneumothorax. *Thorax* 1983;**38**:959-60

Spontaneous oesophageal perforation during vaginal delivery

S M Dresner FRCS J L Bailey MRCOG¹
P J Lamb FRCS² J Wayman FRCS S M Griffin FRCS

J R Soc Med 2001;94:90–91

In 1724, Boerhaave of Leiden reported a fatal oesophageal rupture in Baron Wassenaar, Grand Admiral of the Dutch Fleet, a glutton who practised the Roman habit of autoemesis. Boerhaave's syndrome continues to occur in similar, although usually less extreme, circumstances where there is prolonged and forceful vomiting.

CASE HISTORY

A woman aged 24 underwent spontaneous normal vaginal delivery at 39 weeks of gestation. Her antenatal course had been uncomplicated and she was otherwise fit and well. The total labour time was 8.5 h, with a short second stage (17 min); the infant, a healthy boy, weighed 3.2 kg. The mother was given 50 mg intramuscular pethidine with an antiemetic shortly before delivery and vomited once, bringing up a small amount of bile. The attending midwife and obstetrician subsequently noted development of surgical emphysema over the chest wall. Apart from further retching and mild dyspnoea there were no other symptoms. A chest radiograph revealed extensive subcutaneous and mediastinal air and oesophageal perforation was diagnosed, but a Gastrograffin contrast swallow revealed no leak. Intravenous antibiotics were administered, oral intake was stopped and the patient was referred to the regional oesophageal unit.

14 hours after delivery surgical emphysema was still present over the chest wall and neck but the patient was comfortable, afebrile and haemodynamically stable. The chest X-ray was unchanged, with no pleural effusion or pneumothorax. Upper gastrointestinal endoscopy, conducted under intravenous sedation with minimal insufflation, revealed a short full-thickness linear tear in the lower oesophagus. A nasogastric tube was inserted into the stomach under direct vision and image intensification, for hourly aspiration. The patient made good progress thereafter. Intravenous fluid therapy and antibiotics were maintained for 5 days and a repeat chest X-ray confirmed the resolution of the surgical emphysema. A further contrast swallow was normal and the nasogastric tube was removed before oral diet was resumed without adverse

effects. The patient was discharged home on day 6. Throughout the hospital stay mother and baby had been nursed together and the child bottle-fed successfully.

COMMENT

Spontaneous oesophageal perforation during pregnancy is very rare and, when it does happen, tends to be associated with hyperemesis gravidarum in the first trimester^{1,2}. In the case reported here, the perforation during normal vaginal delivery could have had several causes. Vomiting is a well-recognized aetiological factor³ and may have been induced by the pethidine analgesia. Another opioid, morphine, is known to impair lower oesophageal sphincter relaxation within minutes after intravenous administration⁴. Furthermore, the patient had a raised intra-abdominal pressure from pushing during the second stage of labour. Both these factors may have contributed to development of the perforation. It is also possible that the patient had an inherent oesophageal abnormality such as a deficiency in the muscularis mucosa or a disorder of motility; but, even if we had found such an abnormality the question of cause or effect would have remained open.

The successful outcome of this case is principally related to the early recognition of the tear and correct management at the outset. Many spontaneous oesophageal ruptures are confused with pneumonia or myocardial ischaemia and delays in diagnosis and appropriate therapy can lead to life-threatening mediastinal sepsis. The classic triad of vomiting followed by severe chest pain and subsequent development of surgical emphysema is not always present. Diagnosis is often difficult since 20–45% of patients have no history of vomiting and clinical features vary widely according to the site of perforation⁵. Here the patient vomited only once and pain was not a major feature; surgical emphysema was the only sign. Mediastinal and subcutaneous gas on chest X-ray is highly suggestive of an oesophageal tear although its absence does not exclude a rupture; all patients in whom the diagnosis is suspected should have a contrast swallow. In the patient reported here, the tear had probably sealed spontaneously, since the Gastrograffin swallow 5 hours after initial symptoms did not reveal a leak. Upper gastrointestinal endoscopy is of great importance, both to view the rupture and to ensure that a nasogastric tube for decompression is safely inserted into the stomach and not through the tear.

The choice between conservative and operative approaches depends on the site/size of rupture, the degree of mediastinal contamination and crucially any delay in diagnosis⁶. The conservative approach—withholding of oral intake coupled with nasogastric decompression and broad-spectrum intravenous antibiotics—is

unfortunately only appropriate for a minority of small tears recognized at an early stage. The addition of chest drainage for pleural collections is another option, but most patients present late with cardiorespiratory complications, necessitating surgical repair or resection. An overall mortality of less than 10% is achievable, but the case-fatality is several times higher if diagnosis is delayed^{5,6}. Early recognition remains the key to a successful outcome.

REFERENCES

- 1 Gorbach JS, Counselman FL, Mendelson MH. Spontaneous pneumomediastinum secondary to hyperemesis gravidarum. *J Emerg Med* 1997;**15**:639–43
- 2 Woolford TJ, Birzgalis AR, Lundell C, Farrington WT. Vomiting in pregnancy resulting in oesophageal perforation in a 15-year-old. *J Laryngol Otol* 1993;**107**:1059–60
- 3 Walker WS, Cameron EW, Walbaum PR. Diagnosis and management of spontaneous transmural rupture of the oesophagus (Boerhaave's syndrome). *Br J Surg* 1985;**73**:204–7
- 4 Dowlatshahi K, Evander A, Walther B, *et al*. Influence of morphine on the distal oesophagus and the lower oesophageal sphincter—a manometric study. *Gut* 1985;**26**:802–6
- 5 Bufkin BL, Miller JI Jr, Mansour KA. Esophageal perforation: emphasis on management. *Ann Thorac Surg* 1996;**61**:1447–51
- 6 Curci JJ, Horman MJ. Boerhaave's syndrome: the importance of early diagnosis and treatment. *Ann Surg* 1976;**183**:401–8

Painful eye after a 'flu-like illness

T G Duke FRCOphth¹ P M Drummond FRCS FRCOphth¹
D Brightman MRCPATH²

J R Soc Med 2001;**94**:91–92

Endogenous ophthalmitis needs to be thought of in a patient with painful eye, even when there are no manifestations of systemic infections.

CASE HISTORY

A girl of 16 came to eye casualty with a one-day history of a red painful left eye with photophobia. Three days previously she had had a 'flu-like illness with headache, sore throat, neck stiffness and rash. The symptoms had resolved without medical intervention and the rash had disappeared. On initial examination her visual acuity was 6/9 in each eye and she had a moderate anterior uveitis without posterior segment involvement. Inflammatory acute anterior uveitis was diagnosed and she was started on topical steroids and a cycloplegic. Next day she returned

with severe ocular pain and reduced visual acuity (hand movements only). She had diffuse exudates in the anterior chamber; intraocular pressure was raised (44 mmHg by Goldmann applanation tonometry) and fundal details were not visible. She continued to worsen on intensive topical steroids and infective endophthalmitis was diagnosed. The anterior chamber and vitreous were tapped and she received intravitreal vancomycin 1.0 mg and amikacin 0.4 mg. As she was penicillin-sensitive, she was started on intravenous ciprofloxacin (daily dose 15 mg/kg) and intensive topical cefuroxime and gentamicin. *Neisseria meningitidis* group C subtype 1:5 was isolated from the anterior chamber and from vitreous samples cultured in blood agar and chocolate agar. The topical antibiotics were changed to chloramphenicol and ciprofloxacin.

N. meningitidis was not isolated from blood cultures or nasal and throat swabs. Cerebrospinal fluid was not examined since she had no symptoms of meningitis. The hypopyon became organized and the lens opacified. She was then referred to a regional unit for lensectomy and vitrectomy. After surgery and with further resolution of the endophthalmitis, she achieved a corrected visual acuity of 6/18.

COMMENT

Endogenous endophthalmitis is an important condition to recognize since early intravenous antibiotic therapy is essential for a good outcome¹. The condition results from haematogenous spread of the infective organism across the blood–ocular barrier (whereas exogenous endophthalmitis is usually due to trauma). The groups most affected are diabetic and immunocompromised patients together with intravenous drug abusers.

Overall, fungi are the most common pathogens, *Bacillus cereus* is the principal bacterial cause^{1,2}. *N. meningitidis* endogenous endophthalmitis is a familiar complication of meningococcal meningitis or septicaemia¹. Reviewing 22 cases of meningococcal endogenous endophthalmitis reported since 1943, Wong and Balakrishnan³ found the onset of ocular findings to range between one and six days from the initial systemic presentation, which was a rash in 50%. One-third of cases were bilateral.

N. meningitidis endogenous endophthalmitis usually has a good outcome if treated early, since it tends to arise in young previously fit patients, is sensitive to penicillin, affects the anterior segment primarily and is heralded by a characteristic picture of meningitis and bacteraemia¹. When, however, systemic symptoms are absent, diagnosis and treatment are likely to be delayed; several cases of this sort have been reported previously^{4–7}. In our patient, the 'flu-like illness and rash probably represented a bacteraemic event which resolved spontaneously but seeded in the eye.

REFERENCES

- 1 Greenwald MJ, Wohl LG, Sell CH. Metastatic bacterial endophthalmitis: a contemporary reappraisal. *Surv Ophthalmol* 1986;**31**:81-101
- 2 Okada AA, Johnson RP, Liles WC, D'Amico DJ, Baker AS. Endogenous endophthalmitis: report of a ten-year retrospective study. *Ophthalmology* 1994;**101**:832-8
- 3 Wong JS, Balakrishnan V. *Neisseria meningitidis* endogenous endophthalmitis: case report and literature review. *J Pediatr Ophthalmol Strabismus* 1999;**36**:145-52
- 4 Auerbach SB, Leach CT, Bateman BJ, Sidikaro Y, Cherry JD. Meningococcal endophthalmitis without concomitant septicemia or meningitis. *Pediatr Infect Dis J* 1989;**8**:411-13
- 5 Brinser JH, Hess JB. Meningococcal endophthalmitis without meningitis. *Can J Ophthalmol* 1981;**16**:100-1
- 6 Kearns AM, Sprott MS. Endophthalmitis caused by *Neisseria meningitidis*. *J Infect* 1990;**22**:299-300
- 7 Sleep T, Graham M. A case of meningococcal endophthalmitis in a well patient. *Br J Ophthalmol* 1997;**81**:1016-17