

## Spontaneous carotid dissection presenting lower cranial nerve palsies

Donata Guidetti<sup>a,\*</sup>, Anna Pisanello<sup>a</sup>, Franco Giovanardi<sup>b</sup>, Claudio Morandi<sup>b</sup>, Giulio Zuccoli<sup>b</sup>,  
Antonio Troiso<sup>b</sup>

<sup>a</sup>*Divisione Neurologica, Azienda Ospedaliera Santa Maria Nuova, Viale Risorgimento 80, 42100 Reggio Emilia, Italy*

<sup>b</sup>*Servizio di Radiologia, Azienda Ospedaliera Santa Maria Nuova, Viale Risorgimento 80, 42100 Reggio Emilia, Italy*

Received 7 March 2000; received in revised form 2 January 2001; accepted 4 January 2001

### Abstract

Cranial nerve palsy in internal carotid artery (ICA) dissection occurs in 3–12% of all patients, but in 3% of these a syndrome of hemiparesis and ipsilateral cranial nerve palsy is the sole manifestation of ICA dissection, and in 0.5% of cases there is only cranial nerve palsy without headache. We present two cases of lower cranial nerve palsy. The first patient, a 49-year-old woman, developed left eleventh and twelfth cranial nerve palsies and ipsilateral neck pain. The angio-RM showed an ICA dissection with stenosis of 50%, beginning about 2 cm before the carotid channel. The patient was treated with oral anticoagulant therapy and gradually improved, until complete clinical recovery. The second patient, a 38-year-old woman, presented right hemiparesis and neck pain. The left ICA dissection, beginning 2 cm distal to the bulb, was shown by ultrasound scanning of the carotid and confirmed by MR angiogram and angiography with lumen stenosis of 90%. Following hospitalisation, 20 days from the onset of symptoms, paresis of the left trapezius and sternocleidomastoideus muscles became evident. The patient was treated with oral anticoagulant therapy and only a slight right arm paresis was present at 10 months follow-up. Cranial nerve palsy is not rare in ICA dissection, and the lower cranial nerve palsies in various combinations constitute the main syndrome, but in most cases these are present with the motor or sensory deficit due to cerebral ischemia, along with headache or Horner's syndrome. In the diagnosis of the first case, there was further difficulty because the cranial nerve palsy was isolated without hemiparesis, and the second case presented a rare association of hemiparesis and palsy of the eleventh cranial nerve alone. Compression or stretching of the nerve by the expanded artery may explain the palsies, but an alternative cause is also possible, namely the interruption of the nutrient vessels supplying the nerve, which in our patients is more likely. © 2001 Elsevier Science B.V. All rights reserved.

*Keywords:* Carotid artery dissection; Lower cranial nerves; Eleventh cranial nerve; Twelfth cranial nerve

### 1. Introduction

The incidence of ICA dissection for all age groups ranges from 2.6 to 2.9 per 100,000 per year, and it is now recognized as one of the common causes of ischemic stroke in younger patients [14,15,22]. Due to advances in neuroimaging techniques and to a more widespread availability of these diagnostic methods, more patients with ICA dissection are identified and a wider spectrum of clinical presentation of such dissections is recognized. The com-

mon clinical presentations of ICA dissection are hemiparesis and ipsilateral oculosympathetic palsy or hemiparesis and delayed focal cerebral ischemic symptoms [15]. Other manifestations such as neck pain, amaurosis fugax, bruits, dysgeusia or cranial nerve palsies may occur. Many cases of cranial nerve palsies in ICA dissection have been reported, including trigeminal nerve or chorda tympani palsy, and later involvement of the lower cranial nerve palsies associated with ICA dissections has been reported [10,18]. Two distinct syndromes of cranial nerve palsies are recognized in association with ICA dissection. These include a syndrome of lower cranial nerve palsies and a syndrome of ocular motor palsies [4,5,16,18,21,24]. In the syndrome of lower cranial nerve palsy, the twelfth nerve is

\*Corresponding author. Tel.: +39-0522-296-494; fax: +39-0522-296-266.

E-mail address: sno.dona@iol.it (D. Guidetti).

almost invariably involved with or without other lower cranial nerves; ninth, tenth, and eleventh, all or in part [6,9,19,26]. The aim of this study is to signal two new cases of paralysis of the last cranial nerves in the course of ICA dissection, and to discuss the details and the pathogenesis.

## 2. Case report

S.T.M.G, a 49-year-old female, was admitted to hospital after complaining of neck pain and left side headache resistant to common analgesics. The history was positive for migraine without visual disturbances starting from the age of 18, but negative for neck trauma. The present symptoms were not comparable to others previously occurring. The examination showed a left tongue deviation and paresis of the left trapezius and sternocleidomastoideus muscles, without palsy of other cranial nerve or focal cerebral ischemic symptom (Fig. 1). The cerebral CT and MRI were normal and ultrasound scanning of the carotid circulation was performed (Acuson 128 XP/10, mountain view 7 MHz linear array probe), which showed no wall lesions or flow alterations in the left ICA. An MRI of the skull base and neck showed thyroïdal goitre involving the right lobe, with left trachea displacement. Moreover, T<sub>1</sub>-weighted spin echo images acquired on axial plane re-

vealed an eccentric hyperintense signal surrounding the left ICA in the last part of the prepetrosal portion suggestive of a subacute intramural hematoma (Fig. 2). The MR angiogram confirmed vessel stenosis, beginning 2 cm before admittance of the vessel into the carotid channel and continuing in the same channel for less than 1 cm. At the same level, the maximum transverse diameter of the vessel was increased by an oval formation with intermediate signal intensity surrounding the luminal flow that represents intramural haemorrhage, inside of which the lumen lies in an eccentric way with a stenosis of 50%. There were no irregularities of the vessel lumen typical of fibromuscular dysplasia and there were no clinically significant aspects for other hereditary connective tissue disorders. Neurogenic EMG alterations were seen in the trapezius and sternocleidomastoideus muscles. The blood examinations including lupus-like anticoagulant, anti-phospholipid antibodies, Lp (a), homocysteine, and APC resistance, were normal. The molecular biology study excluded V Leiden factor, C/T 677 mutation of the MTHFR gene, and prothrombin G20210A mutations.

The patient was treated with oral anticoagulants (INR range 2 to 3) and gradually improved up to complete clinical recovery. An MR angiogram performed at 50 days distance from symptoms onset demonstrated the disappearance of the alterations.

V.E., a 38-year-old woman, was admitted to hospital

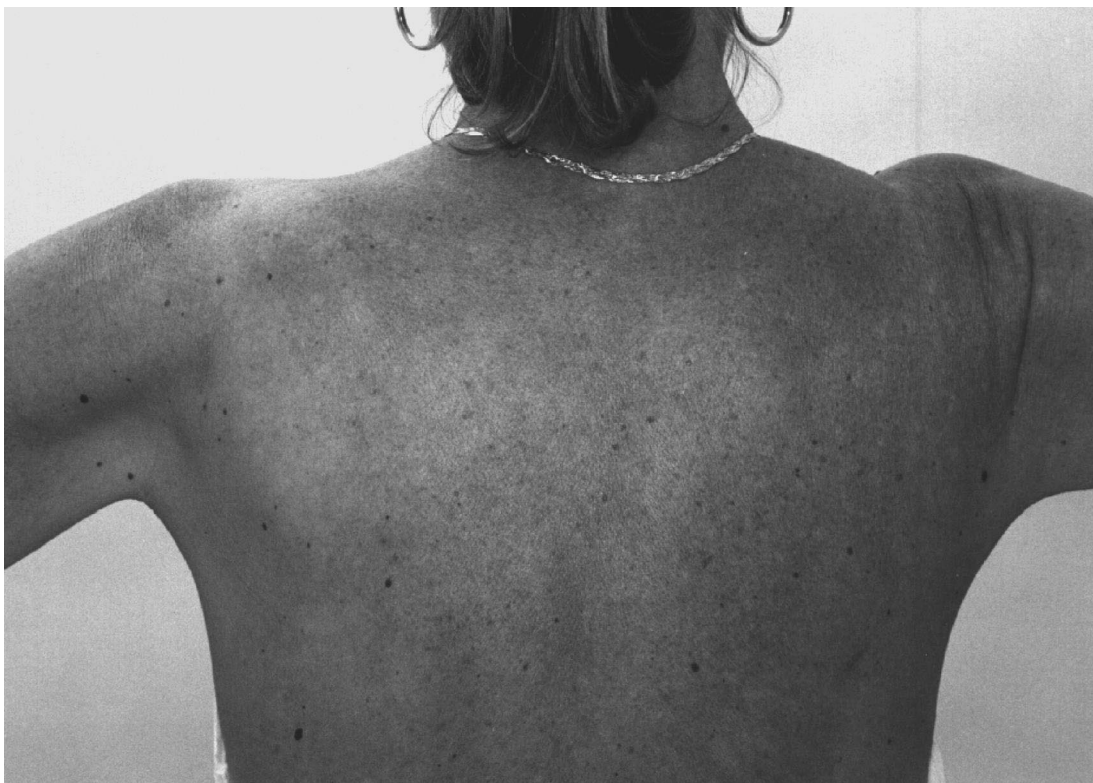

Fig. 1. Patient S.T.M.G.: paresis of the left trapezius muscle.

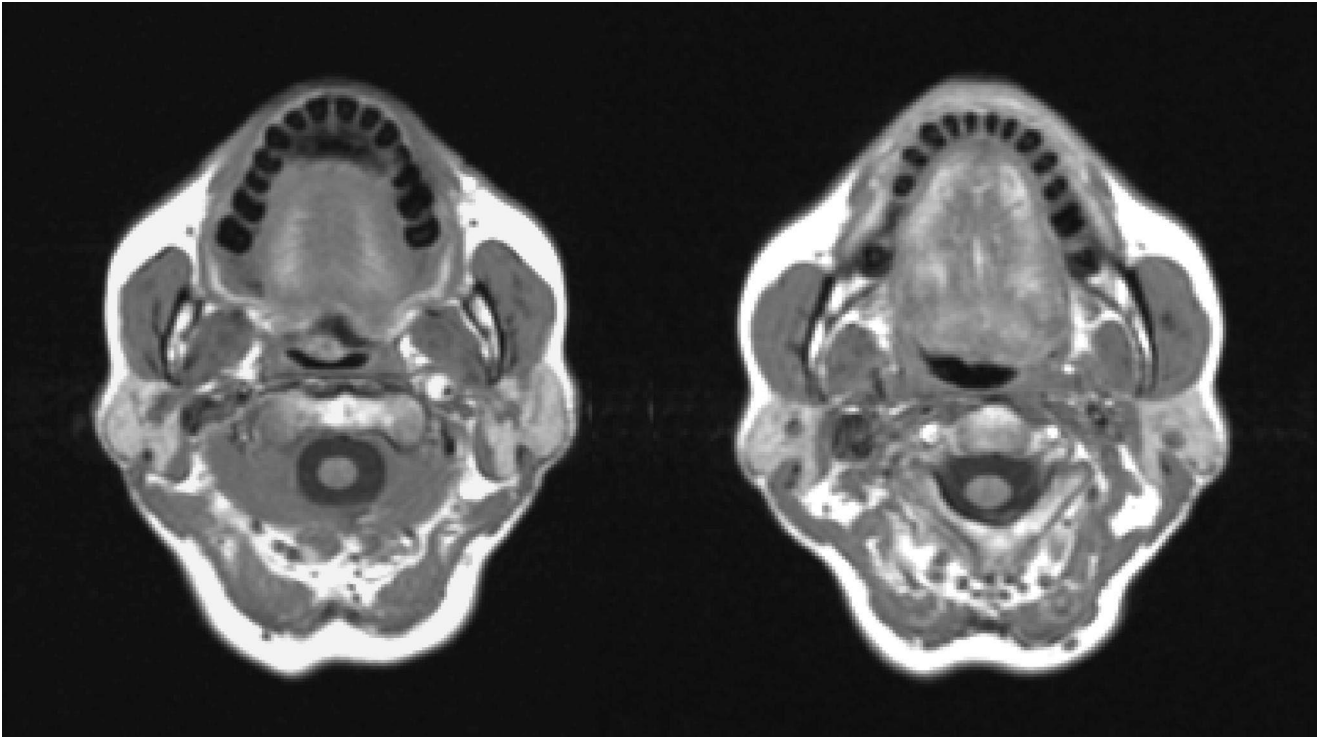


Fig. 2. (a, b) Patient S.T.M.G.: Axial T1-weighted MR image shows eccentric hyperintensity of the hematoma surrounding the left ICA (a). No signs of left ICA dissection are seen at the lower scan level (b).

because of a right hemiparesis increasing over 3 days along with neck pain. The left ICA dissection, beginning 2 cm distal to the bulb, was shown by ultrasound scanning of the carotid and confirmed by MR angiogram and angiography which showed a lumen stenosis of 90%. The lumen stenosis stopped at the entry into the carotid canal. The CT also showed a cerebral ischaemic lesion in the territory of the middle left cerebral artery. There were no irregularities of the vessel lumen, typical of fibromuscular dysplasia, and there were no clinically significant aspects for other hereditary connective tissue disorders. Following hospitalisation, 20 days from the onset of symptoms, paresis of the left trapezius and sternocleidomastoideus muscles became evident (Fig. 3). Neurogenic EMG alterations were seen in these muscles. The blood examinations including lupus-like anticoagulant, anti-phospholipid antibodies, protein C, protein S, serum lactic acid, Lp (a), homocysteine, APC resistance, were all normal. The molecular biology study excluded V Leiden factor and prothrombin G/A 20210 mutations. The MTHFR gene showed a heterozygous mutation C/T 677 and the homocysteinaemia was high following methionine load:  $30.1 \mu\text{mol/l}$  (v.n. 10.3–26.7), with normal folic acid and vitamins. The patient was treated with oral anticoagulant therapy and only a slight right arm paresis was present at 10 months follow-up. The MR angiogram at 4 months follow-up showed the normalisation of the vessel lumen of left ICA.

### 3. Discussion

Rather than the typical lower cranial nerve palsy involving the twelfth, eleventh, tenth, ninth cranial nerves and Horner's syndrome, our cases presented the sole involvement only of the twelfth and eleventh or only the eleventh. For this reason, the pathogenesis of the palsy cannot easily be attributed to mechanical compression or stretching of the nerves below the jugular foramen. Furthermore, the mechanical theory does not explain the palsy of twelfth and eleventh nerves, without involvement of the sympathetic, vagus and glossopharyngeal nerves which, in the prepetrosal part of ICA, lie nearer to ICA. In particular, such a mechanism must always involve the sympathetic nerve which actually surrounds the ICA [8,11,20,25]. Moreover, in our first case, the size of the dissected vessel was not significant and no dissecting aneurysms were present.

In addition, the mechanical theory does not explain other cranial nerve palsies reported in the literature, such as the trigeminal, the facial nerve or ocular motor palsies [5,7,12,17,21,23]. In only one of 190 cases reported by Mokri does the ICA dissection extend into the carotid canal, but there was no extension to the cavernous segment, where the ICA is in proximity to the oculomotor nerves [15]. Therefore, in these cases as well, a mechanical cause could not be hypothesized [4]. A less likely possibility was either a transient or permanent interruption of

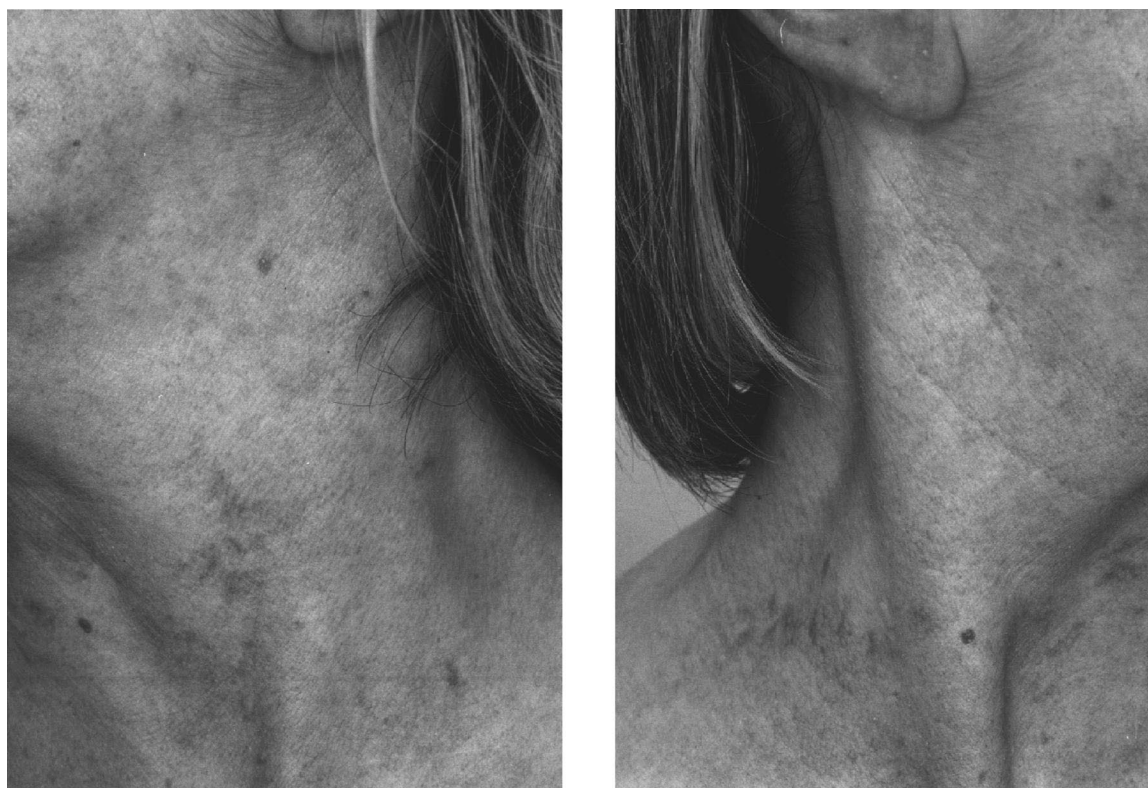

Fig. 3. Patient V.E.: Evident atrophy of left sternocleidomastoideus muscle (a) in comparison with the contralateral (b).

the blood supply to the cranial nerve. In the practice of interventional neuroradiology, cranial nerve palsies are recognized complications of intra-arterial embolization, and a regressive paralysis of IXth, Xth and XIIth nerves after cerebral angiography is reported [1,13]. In a study of autopsy material, Havelius identified a very minor artery that sometimes detaches from the ICA close to the base of the skull. These authors commented that if this minor artery contributes to the vascular supply of the nearby cranial nerves, its compromise may cause segmental ischemic damage to these nerves [3]. These nutrient arteries are too small (200 to 300  $\mu\text{m}$  in diameter). Three vascular systems play a significant role in nutrient supply

to most of the cranial nerve: the inferolateral trunk, often arising from the ICA and the middle meningeal system, and the ascending pharyngeal system that derive from the external carotid artery [2,4] (Table 1). The lower cranial nerves have a significant nutrient supply from the ascending pharyngeal system, which may present anomalies originating from cervical ICA. An anomaly of this type, which is difficult to demonstrate by means of standard angiographic techniques, could be the basis, at least in part, of the complications involving the cranial nerves described by cerebral angiography, interventional neuroradiology and in the cases of partial syndromes of lower cranial nerve palsies in which there is no significant dilation of the artery

Table 1  
Cranial nerve anatomical vascular distribution

Vessel	Origin	Branches	Variation of origin	Cranial nerves supplied
Inferolateral trunk	Siphon of internal carotid artery	Superior or tentorial artery	No	III, IV
		Anteromedial branch	No	III, IV, VI and the first division of V nerve
		Anterolateral branch	External carotid artery	Second division of V nerve
		Posterior branch	External carotid artery	Third division of V nerve
Middle meningeal system	External carotid artery	Accessory meningeal artery	Inferior lateral trunk (internal carotid artery)	Third division of V nerve
		Middle meningeal	10% of cases	Third division of V nerve
		Petrous branch		VII nerve
Ascending pharyngeal system	External carotid artery	Posterior neuromeningeal branch	Jugular	IX, X, and XI
			Hypoglossal	XII
			Musculospinal	Muscular ramus of XI

and the nerves are not involved according to their degree of proximity with the ICA itself.

In the only case reported in the literature, the paresis of cranial nerves that arises after considerable time from the onset of symptoms was attributed to a slow progressive, or later acute, expansion of the carotid artery; but in this case a gradual reduction of the stenosis and normalisation of the flow was documented by means of ecocolour doppler ultrasound scanning. As an alternative, it might be possible to hypothesise an embolic mechanism, with ischaemia of the nerve, during the course of anti-coagulant treatment and resolution of the wall thrombus [10].

We conclude that cranial nerve palsies are explained by compression or stretching of the expanded artery in some cases; most of them probably result from impairment of the nutrient arterial supply to the related nerve. Such impairment may be caused by distal embolisation, pressure gradient changes in collateral supply, or anomalous origin in the nutrient vessel and its impairment by the dissection.

## Acknowledgement

Authors wish to thank Dr. Marco Boillat De Corgemont Sartorio for revising the manuscript.

## References

- [1] Lapresle J, Lasjaunias P, Thevenier D. Transitory paralysis of cranial nerves IX, X and XII as well as the left VII after angiography. Contribution to the ischemic pathology of the cranial nerve. *Ren Neurol* 1980;136:787–91.
- [2] Devoize JL, Rouanet J, Cellerier P, Georget AM, Tournilhac M. Benign paralysis of the last 4 cranial nerves. Arguments in favor of an ischemic mechanism. *Presse Med* 1985;14:1328–30.
- [3] Havelius U, Hindfelt B. Minor vessels leaving the extracranial internal carotid artery. *Neurol Ophthalmol* 1985;5:51–6.
- [4] Lapresle J, Lasjaunias P. Cranial nerve ischaemic arterial syndromes. A review. *Brain* 1986;109:207–16.
- [5] Biousse V, Touboul PJ, D'Anglejan-Chatillon J, Levy C, Schaison M, Bousser MG. Ophthalmologic manifestations of internal carotid artery dissection. *Am J Ophthalmol* 1988;126:565–77.
- [6] Klossek JM, Vandenmarq P. Unilateral lower cranial nerve palsies due to spontaneous internal carotid artery dissection. *Ann Otol Rhinol Laryngol* 1994;103:413–5.
- [7] Lal V, Sawhney IMS, Bansal SK, Prabhakar S. Abducens nerve palsy due to spontaneous internal carotid artery dissection. A case report. *Comput Med Imaging Graph* 1994;18:381–3.
- [8] Magoni M, Scipione V, Anzola GP. Isolated accessory nerve palsy of unusual cause. *Ital J Neurol Sci* 1994;15:241–3.
- [9] Auzou P, Hannequin D, Patroux B, Proust F, Marie JP, Augustin P. Atteinte du grand hypoglosse révélant une dissection de l'artère carotide interne. *Ann Otolaryngol Chir Cervicofac* 1995;113:45–7.
- [10] Pica RA, Rockwell BH, Raji RM, Dastur KJ, Berkey KE. Traumatic internal carotid artery dissection presenting as delayed hemilanguage paresis. *AJNR Am J Neuroradiol* 1995;17:86–8.
- [11] Brow J, Danielson R, Donahue SP, Thompson HS. Horner's syndrome in subadventitial carotid artery dissection and the role of magnetic resonance angiography. *Am J Ophthalmol* 1995;119:811–3.
- [12] Selky AK, Pascuzzi R. Raeder's paratrigeminal syndrome due to spontaneous dissection of the cervical and petrous internal carotid artery. *Headache* 1995;35:432–4.
- [13] Cartier J, Cartier P, Hudon G, Rousseau M. Combined endarterectomy of the internal carotid artery and persistent hypoglossal artery: an unusual case of carotid revascularization. *Can J Surg* 1996;39:159–62.
- [14] Gobert M, Mounier-Vehier F, Lucas C, Leclerc X, Leys D. Cranial nerve palsies due to internal carotid artery dissection : seven cases. *Acta Neurol Belg* 1996;96:55–61.
- [15] Mokri B, Silbert PL, Schievink WI, Piepgras DG. Cranial nerve palsy in spontaneous dissection of the extracranial internal carotid artery. *Neurology* 1996;46:356–9.
- [16] Lemesle M, Beuriat P, Becker F, Martin D, Giroud M, Dumas R. Head pain associated with sixth-nerve palsy: spontaneous dissection of the internal carotid artery. *Cephalalgia* 1998;18:112–4.
- [17] Ogretmenoglu O, Kaya S, Unal OF. Blindness as a rare complication of neck dissection. *Eur Arch Otorhinolaryngol* 1997;254:478–80.
- [18] Purvin V. Unilateral headache and ptosis in a 30-year-old woman. *Surv Ophthalmol* 1997;42:163–8.
- [19] Rees JH, Valentine AR, Llewelyn JG. Spontaneous bilateral carotid and vertebral artery dissection presenting as a Collet-Sicard syndrome. *Br J Radiol* 1997;70:856–8.
- [20] Ameline-Audelan V. Syndrome de Claude Bernard Horner douloureux: a propos d'une dissection carotidienne indolore. *J Fr Ophtalmol* 1998;21:591–5.
- [21] Biousse V, Schaison M, Touboul PJ, D'Anglejan J, Bousser MG. Ischemic optic neuropathy associated with internal carotid artery dissection. *Arch Neurol* 1998;55:715–9.
- [22] Guillon B, Lévy C, Bousser MG. Internal carotid artery dissection: an update. *J Neurol Sci* 1998;153:146–58.
- [23] Gout O, Bonnaud I, Weill A, Moulignier A, Quenet JJ, Moret J, Bakouche P. Facial diplegia complicating a bilateral internal carotid artery dissection. *Stroke* 1998;30:681–6.
- [24] Koennecke HC, Seyfert S. Mydriatic pupil as the presenting sign of common carotid artery dissection. *Stroke* 1998;29:2653–5.
- [25] Leira EC, Bendixen BH, Kardon RH, Adams HP. Brief, transient Horner's syndrome can be a hallmark of carotid artery dissection. *Neurology* 1998;50:289–90.
- [26] Nusbaum AO, Som PM, Dubois P, Silvers A. Isolated vagal nerve palsy associated with a dissection of the extracranial internal carotid artery. *AJNR Am J Neuroradiol* 1998;19:1845–7.